

Start	End	Topic	Speakers
09:00	09:15	Pelvic Neuroanatomy and Neurophysiology	Nucelio Lemos
09:15	09:45	Peripheral Nerve Entrapment – From Diagnosis to Surgical Treatment	Nucelio Lemos
09:45	10:00	Role, Techniques and Rationale of Physical Therapy on the Post-Operative Treatment of Intrapelvic Nerve Entrapments	Marilia Frare
10:00	10:15	Musculoskeletal Nerve Entrapments and Myofascial Pain- The Role of Physical	Nelly Faghani
10:15	10:30	Discussion and Wrap Up	Nucelio Lemos, Marilia Frare, Nelly Faghani

Speaker Powerpoint Slides

Please note that where authorised by the speaker all PowerPoint slides presented at the workshop will be made available after the meeting via the ICS website www.ics.org/2017/programme Please do not film or photograph the slides during the workshop as this is distracting for the speakers.

Aims of Workshop

This workshop is directed to both clinicians and basic scientists interested in understanding the pathophysiology, clinical features and the therapeutic options of pudendal neuralgia and other intrapelvic nerve entrapments. The program starts with a review of the normal pelvic neuroanatomy through real surgery laparoscopic dissections. After this introduction, the clinical features of nerve entrapment syndromes will be explained, medical treatment guidelines will be proposed and the surgical treatment will be demonstrated by means of real surgery videos. The role of pelvic floor muscles in the etiopathogenesis of pelvic and perineal pain role of physical therapy will also be thoroughly discussed.

Learning Objectives

- To describe and discuss the Surgical Neuroanatomy of the Pelvis as applied to intrapelvic neuropathies.
- To develop an etiology-based understanding of pudendal pain and pain derived from other intrapelvic neuropathies.
- To highlight the importance of a multidisciplinary approach to intrapelvic neuropathies and describe the role of each professional in the team.

Learning Outcomes

- Understand the Surgical Neuroanatomy of the Pelvis as applied to intrapelvic neuropathies.
- Understand and diagnose pudendal pain and pain derived from other intrapelvic neuropathies.
- Start/improve the multidisciplinary approach to intrapelvic neuropathies.

Target Audience

Clinicians, surgeons and physios interested at pelvic and pudendal pain

Advanced/Basic

Advanced

Suggested Learning before Workshop Attendance

1. Lemos N, Possover M. Laparoscopic approach to intrapelvic nerve entrapments. Journal of Hip Preservation Surgery. , 2015. doi: 10.1093/jhps/hnv030. [CME article in International Journal of Hip Arthroscopy describing the anatomy of intrapelvic nerve bundles and the assessment and treatment of intrapelvic neuropathies.]
2. Lemos N, Souza C, Marques RM, Kamergorodsky G, Schor E, Girão MJ. Laparoscopic anatomy of the autonomic nerves of the pelvis and the concept of nerve-sparing surgery by direct visualization of autonomic nerve bundles. Fertil Steril. 2015 Nov;104(5):e11-2. doi: 10.1016/j.fertnstert.2015.07.1138. [CME video-article describing the anatomy of autonomic nerves of the pelvis and the steps of nerve-sparing radical pelvic surgery.]
3. Lemos N, D'Amico N, Marques R, Kamergorodsky G, Schor E, Girão MJ. Recognition and treatment of endometriosis involving the sacral nerve roots. Int Urogynecol J. 2016 Jan;27(1):147-50. doi: 10.1007/s00192-015-2703-z. [Video-article with series of 13 cases of sacral nerve endometriosis describing signs, symptoms and guidelines for treatment of endometriosis involving sacral nerves.]
4. Lemos N. Intrapelvic Neuropathies In: ICS TV. <http://www.ics.org/tv?play=3189> [Webinar]

Suggested Reading

1. Lemos N, Possover M. Laparoscopic approach to intrapelvic nerve entrapments. *Journal of Hip Preservation Surgery.* , 2015. doi: 10.1093/jhps/hnv030. [CME article in *International Journal of Hip Arthroscopy* describing the anatomy of intrapelvic nerve bundles and the assessment and treatment of intrapelvic neuropathies.]
2. Lemos N, Souza C, Marques RM, Kamergorodsky G, Schor E, Girão MJ. Laparoscopic anatomy of the autonomic nerves of the pelvis and the concept of nerve-sparing surgery by direct visualization of autonomic nerve bundles. *Fertil Steril.* 2015 Nov;104(5):e11-2. doi: 10.1016/j.fertnstert.2015.07.1138. [CME video-article describing the anatomy of autonomic nerves of the pelvis and the steps of nerve-sparing radical pelvic surgery.]
3. Lemos N, D'Amico N, Marques R, Kamergorodsky G, Schor E, Girão MJ. Recognition and treatment of endometriosis involving the sacral nerve roots. *Int Urogynecol J.* 2016 Jan;27(1):147-50. doi: 10.1007/s00192-015-2703-z. [Video-article with series of 13 cases of sacral nerve endometriosis describing signs, symptoms and guidelines for treatment of endometriosis involving sacral nerves.]
4. Lemos N. Intrapelvic Neuropathies In: ICS TV. <http://www.ics.org/tv?play=3189> [Webinar]

Other Supporting Documents, Teaching Tools, Patient Education etc

WORKSHOP SYLABUS

PELVIC NEUROANATOMY AND NEUROPHYSIOLOGY – NUCELIO LEMOS

Ilio-Hypogastric, Ilio-Inguinal And Genito-Femoral Nerves

These nerves are sensitive branches of the lumbar plexus. The ilio-hypogastric and ilio-inguinal nerves enter the retroperitoneal space emerging on the lateral border of the psoas muscle and follow anteriorly and distally to pierce the internal abdominal oblique muscle close to the antero-superior iliac spine. (4). The genito-femoral nerve emerges from the anterior border of the psoas muscle and its two branches leave the abdomen through the femoral (femoral branch) and inguinal (genital branch) canals. Their fibrotic entrapment is related to post-herniorrhaphy inguinodynia (5) (Figure 1).

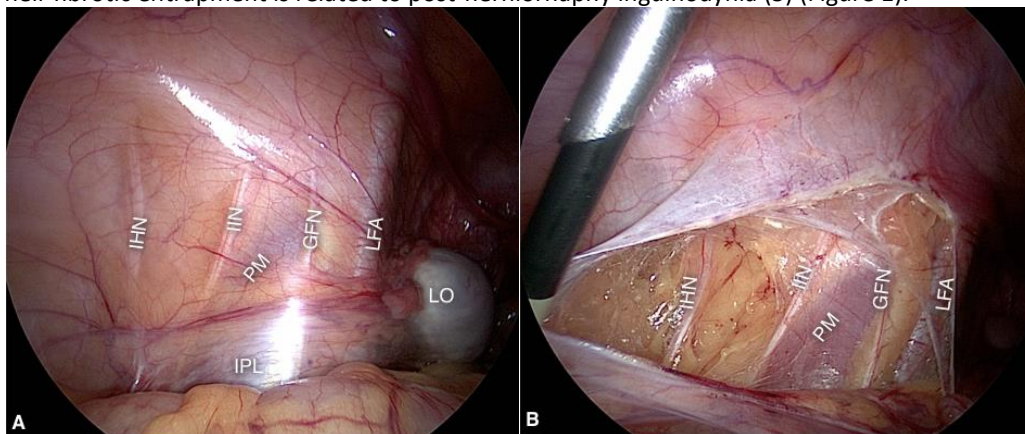


Figure 1. Laparoscopic view the left abdominal wall exhibiting the Ilio-Hypogastric (IHN), Ilio-Inguinalis (IIN) and Genito-Femoralis (GFN) Nerves, with the overlying peritoneum intact (A) and exposed (B) [PM – Psoas Muscle; LO – Left Ovary; IPL – Infundibulopelvic Ligament; LFA – Left Femoral Artery

Femoral nerve

The femoral nerve is the largest motor and sensory nerve of the lumbar plexus. It emerges from the postero-lateral aspect of the psoas muscle and leaves the abdomen through the femoral canal (Figure 2) to innervate the quadriceps muscle and the skin covering the anterior thigh and medial aspect of the leg.

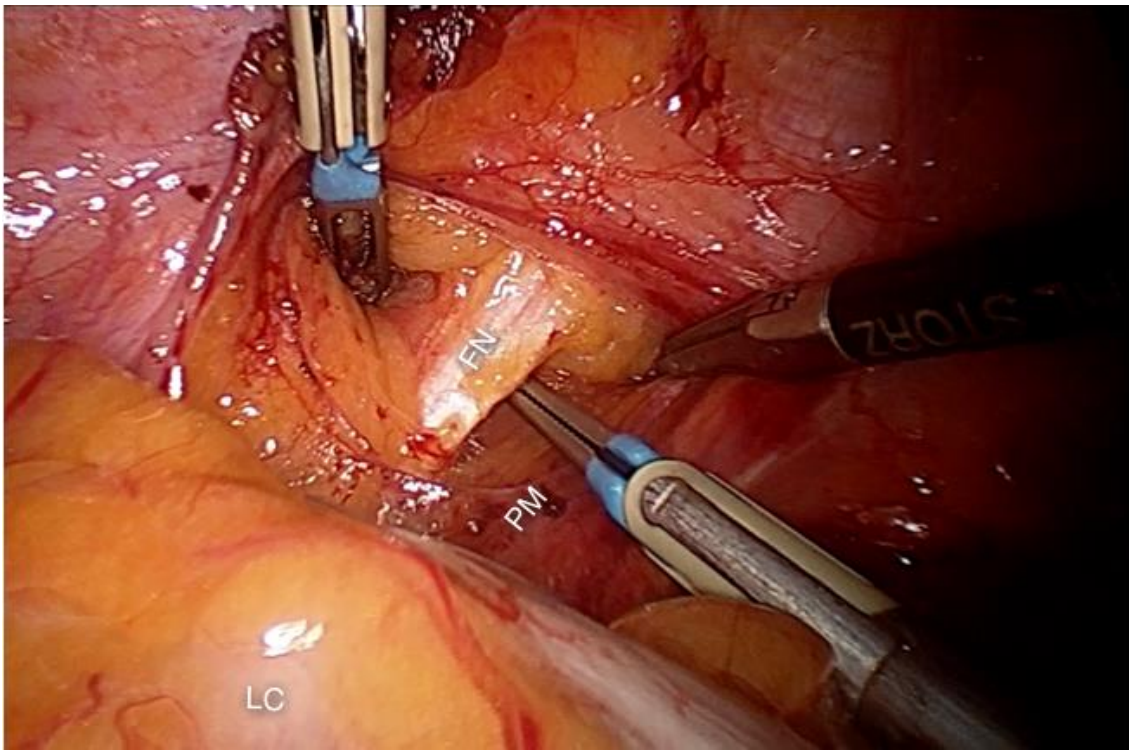


Figure 2. The Left Femoral Nerve (FN) entering the retroperitoneal space on the posterolateral aspect of the Psoas Muscle (PM). (LC – Left Colon)

Nerves of the Obturator Space

The obturator nerve enters the obturator space at the level of the pelvic brim and leaves the pelvis through the obturator canal. It gives sensory branches to the skin of the medial thigh and motor branches to the hip adductors (Figure 3-A).

The lumbosacral trunk and the distal portions of the S1, S2, S3 and S4 nerve roots merge into the obturator space and form the sciatic and pudendal nerves (Figure 3-B).

The sciatic nerve is formed by the L4 and L5 fibers of the lumbosacral trunk and fibers from the S1, S2 and S3 nerve roots and leaves the pelvis through the greater sciatic notch. It gives out sensory branches to the upper gluteal region, posterolateral thigh, leg, ankle and foot. It also controls the hip extensors, abductors and rotators, knee flexors, and all the muscles for the ankle and foot.

The pudendal nerve is formed by fibers of the 2nd, 3rd and 4th nerve roots and leaves the pelvis in the interligamentous plane between the sacrospinous and sacrotuberous ligament. It then enter the pudendal (Alcock's) canal. It provides sensory branches to the the perineal skin. It also sends motor branches to the perineal muscles and the anterior fibers of the levator ani muscles. Finally, there are direct motor and sensory branches from the S3 and S4 nerve roots to the posterior fibers of the levator ani muscle (6-8).

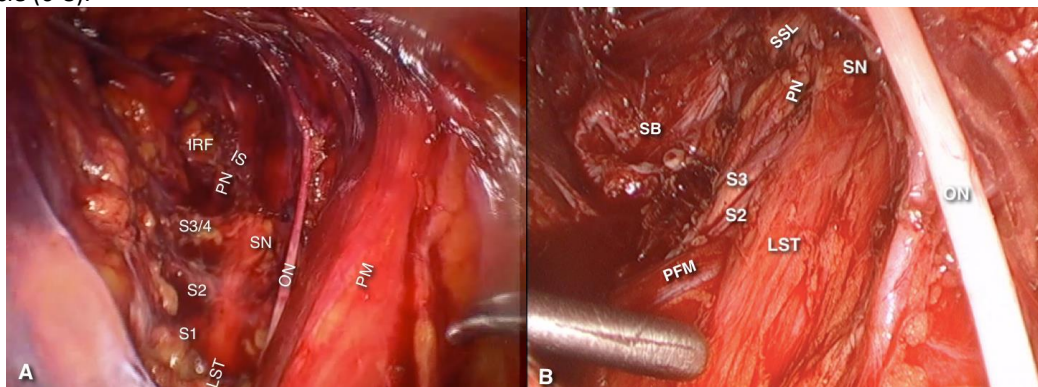


Figure 3. Nerves of the obturator space (right side). Picture (A) is the final aspect of a laparoscopic approach to Alcock's Canal Syndrome, where the sacrospinous ligament has been transected to expose the pudendal nerve (PN). In picture B, the sacrospinous ligament (SSL) is intact. In both pictures, the internal and external iliac vessels are retracted medially. (ON

– Obturator Nerve; PM – Psoas Muscle; SN – Sciatic Nerve; LST – Lumbosacral Trunk; PN – Pudendal Nerve; IRF – Ischiorectal Fossa; IS – Ischial Spine; SB – Sacral Bone; PFM – Piriformis Muscle)

Nerves of the Presacral and Pararectal Spaces

The superior hypogastric plexus, which is formed by fibers from para-aortic sympathetic trunk and gives rise to the hypogastric nerves. The hypogastric nerves run over the hypogastric fascia in an anterior and distal direction. After crossing about two thirds of the distance between the sacrum and the uterine cervix or the prostate, its fibers spread to join the pelvic splanchnic nerves (described below) to form the inferior hypogastric plexus (Figure 4). The hypogastric nerves carry the sympathetic signals to the internal urethral and anal sphincters, rectum and bladder, which cause detrusor relaxation and bladder contraction, thus promoting continence. They also carry proprioceptive and nociceptive afferent signals from the pelvic viscera (9).

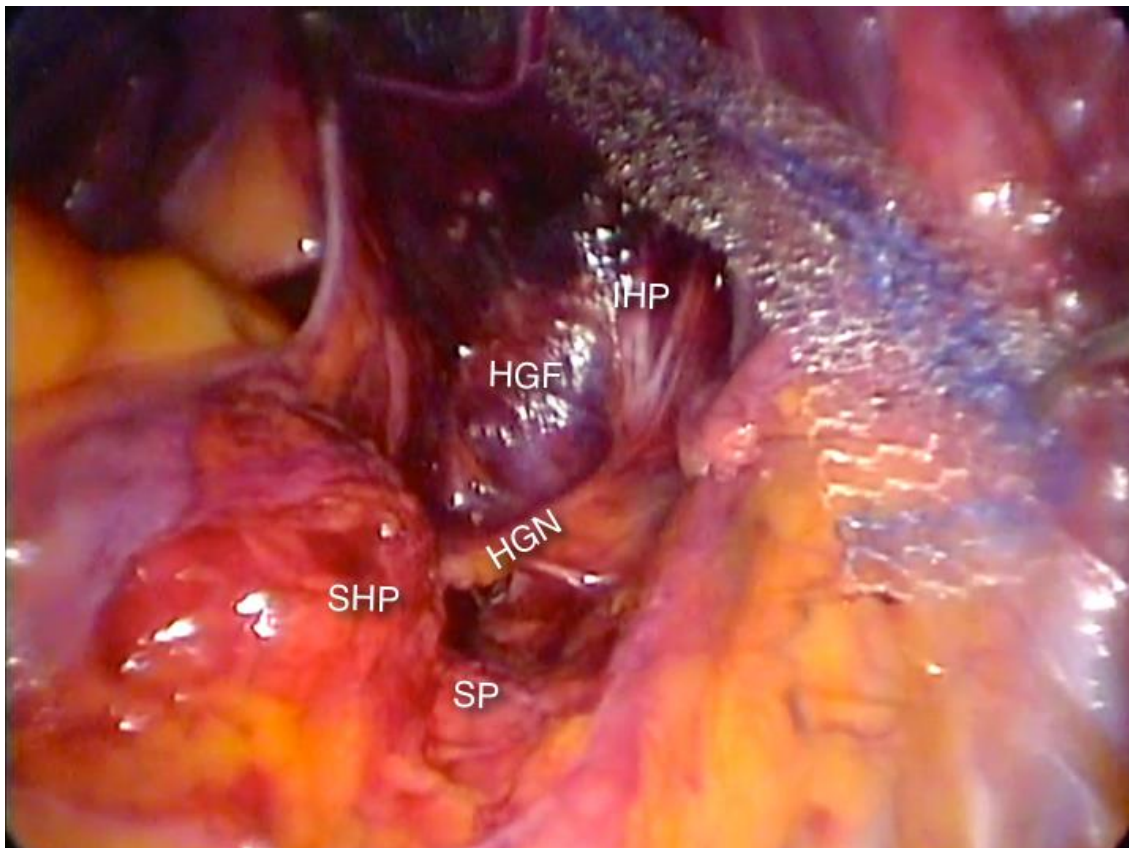


Figure 4. The hypogastric nerve (HN) emerges from the Superior Hypogastric Plexus (SHP) at the level of the Sacral Promontory (SP) and runs anteriorly and distally, juxta-laterally to the Hypogastric Fascia (HF), to merge with the Pelvic Splanchnic Nerves to form the Inferior Hypogastric Plexus (IHP)

The lateral limit of the presacral space is the hypogastric fascia, which is formed by the medial most fibers of the endopelvic fascia. The sacral nerve roots can be found juxta-laterally to this fascia (Figure 5). They leave the sacral foramina and run anteriorly and distally, lying over the piriformis muscle and crossing the internal iliac vessels laterally to them, to merge and form the nerves of the sacral plexus (10). Before crossing the internal iliac vessels, they give out the thin parasympathetic branches called pelvic splanchnic nerves, which promote detrusor contraction and provide extrinsic parasympathetic innervation to the descending colon, sigmoid and rectum. They also carry nociceptive afferent signals from the pelvic viscera (9). The pelvic splanchnic nerves join the hypogastric nerves to form the inferior hypogastric plexus in the pararectal fossae (10).

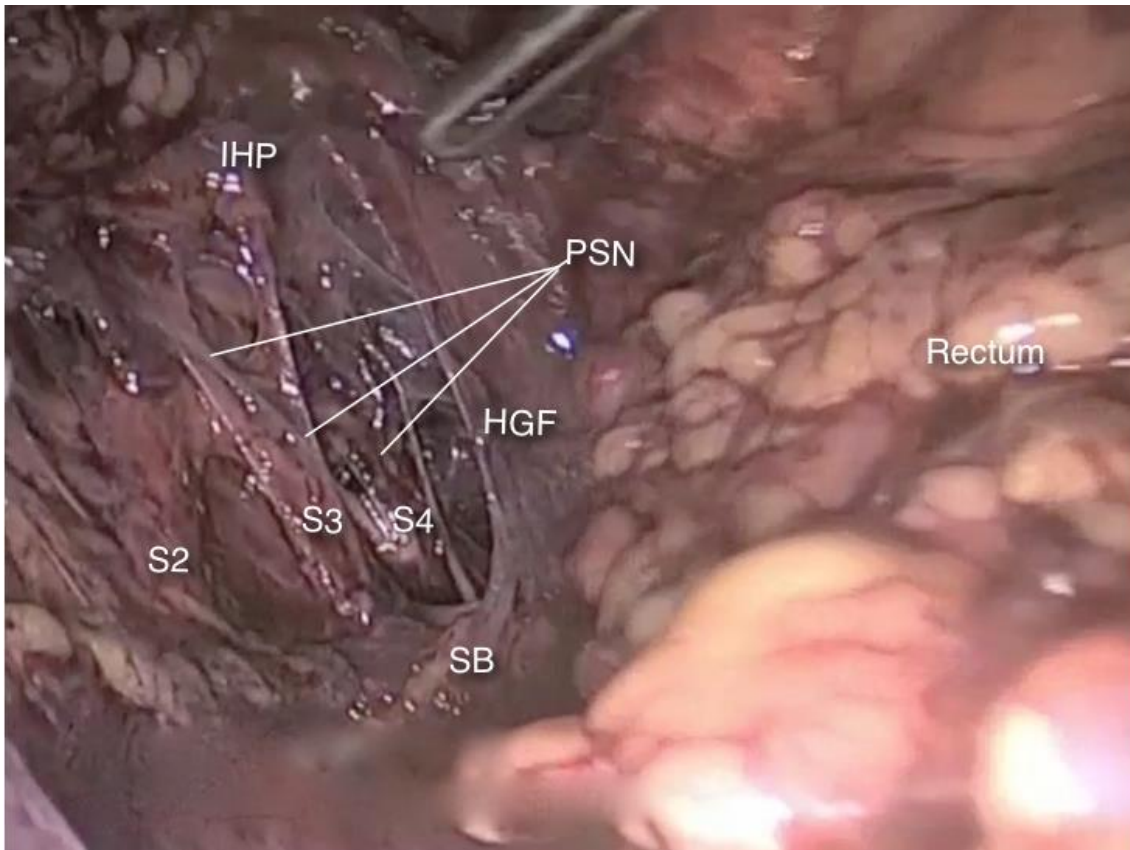


Figure 5. The Sacral Nerve Roots (S2-S4) can be found juxta-laterally to the Hypogastric Fascia (HGF) and give origin to the Pelvic Splanchnic Nerves (PSN), which run anteriorly and distally to merge the Hypogastric Nerve and form the Inferior Hypogastric Plexus (IHP).

INTRAPELVIC NERVE ENTRAPMENT SYNDROME – NUCELIO LEMOS

Definition and Clinical Features

Nerve entrapment syndrome, or compression neuropathy, is a clinical condition caused by compression on a single nerve or nerve root. The symptoms and signs include pain, tingling, numbness, and muscle weakness on the affected nerve's dermatome and myotome (11). Intrapelvic nerve entrapments are, therefore, entrapments of the intrapelvic portions of the nerves described in the previous sessions and will produce clinical features related to the affected nerves.

The above definition refers to the entrapment of somatic nerves. Autonomic nerve entrapment will produce visceral and vegetative symptoms, such as urinary frequency or urgency, dysuria, rectal pain, suprapubic and/or abdominal cramps and chills. However, as described, above, the sacral nerve roots give origin to both somatic and parasympathetic nerves. Therefore, entrapments of these roots will produce somatic (such as pain along the dermatome) and visceral (such as urinary and bowel dysfunction) clinical pictures.

In a concise manner, the main symptoms of intrapelvic nerve entrapments are:

- Sciatica associated with urinary symptoms (urgency, frequency, dysuria) without any clear orthopedic cause (spinal or deep gluteal nerve entrapment);
- Gluteal pain associated with perineal, vaginal or penile pain;
- Dysuria and/or painful ejaculation;
- Refractory urinary symptoms;
- Refractory pelvic and perineal pain.

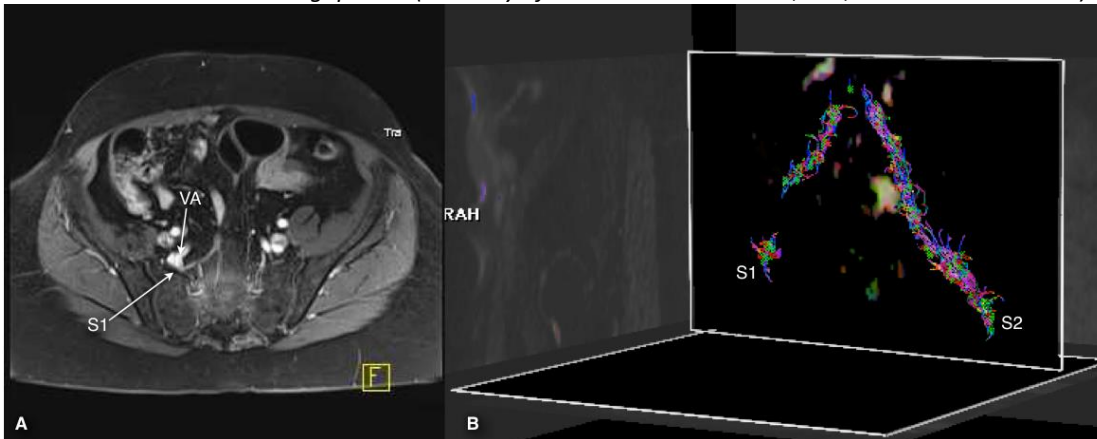
It is important to emphasize that, due to the distance between both plexuses, intrapelvic nerve entrapments will usually cause unilateral symptoms.

Diagnostic Workup

Once the hypothesis of an intrapelvic entrapment is raised, it is mandatory to perform the topographic diagnosis, which is the determination of the exact point of entrapment. So far, careful neuropelveological evaluation, combined with a detailed medical history and neurological examination is the most reliable method for this.

To increase objectivity and accuracy of the diagnosis, we have been examining the use of high definition pelvic MRI and sacral plexus tractography, which is a technique for functional MRI of peripheral nerves (12). Asymmetries and structures that could entrap the plexus are identified at MRI and those specific portions are investigated on tractography for any gaps in neural activity (Figure 6).

Figure 6 – A: contrasted MRI showing enlarged vessels (VA) in direct contact with S1 nerve root. B: Tractography showing a signal gap in S1. (Courtesy of Dr. Suzan M. Goldman, MD, PhD & Homero Faria)



Our results so far are very promising, but the accuracy of this method still needs to be investigated. Therefore, for further assurance, our next step is a diagnostic block, guided by ultrasound or fluoroscopy and performed by an intervention pain specialist; the exact point where a signal gap is identified at the tractography is infiltrated with 0.5mL to 1mL of lidocaine 0.5%. If a reduction of 50% or more in pain (VAS) is observed, the test is considered positive. (Figure 7)

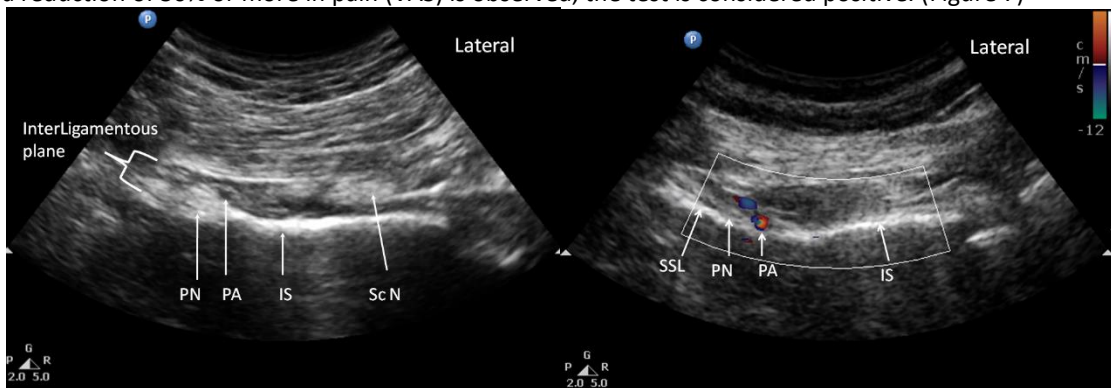


Figure 7 – (A) Ultrasound image of the interligamentous plane at the ischial spine where the pudendal artery and nerve are located between the sacrospinous and sacrotuberous ligaments. (B) Color Doppler of the same picture showed the pudendal artery. Reprinted with permission from Philip Peng Educational Series

ETIOLOGY OF INTRAPELVIC ENTRAPMENTS

Endometriosis

The first report of intrapelvic nerve entrapment was made by Denton and Sherill (13), who described a case of cyclic sciatica due to endometriosis in 1955. After that, some other case reports and small series were published, until 2011, when Possover et al (2) described the largest series so far, with 175 patients, all treated laparoscopically.

In endometriotic entrapments, the symptoms tend to be cyclic, worsening during the premenstrual and menstrual days and ameliorating or even disappearing during the post-menstrual period (2,14, 15).

Evaluation consists of preoperative identification of the symptoms and determination of the topographical localization of the lesions mainly by clinical evaluation, although radiological examination (MRI) is sometimes required. Treatment is achieved by exploring all suspect segments of the plexus through laparoscopic approach, with radical removal of all endometriotic foci and fibrosis (2,14,15) (Figure 8).

The true incidence of endometriosis involving the sacral plexus is unknown, as this presentation of the disease is often neglected. On average, patients undergo four surgical procedures seeking to treat the pain before receiving the right diagnosis (2). Moreover, about 40% of women with endometriosis refer unilateral pain on the inferior limb (16) and, in 30% of patients

with endometriosis, leg pain was demonstrated to be neuropathic, (17) which leads to the conclusion that endometriotic involvement of the lumbosacral plexus is probably underdiagnosed and much more frequent than reported.

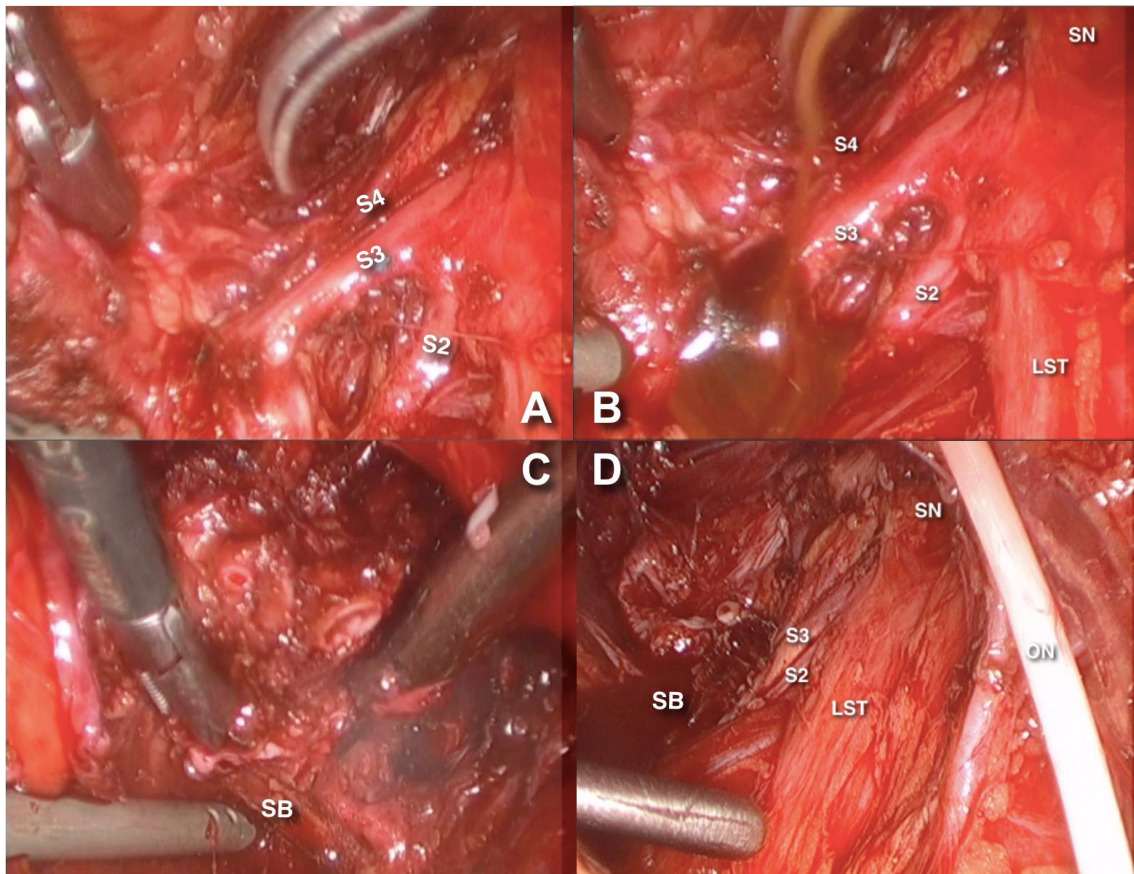


Figure 8 – A – after partial detachment of the nodule, allowing for visualization of S2, S3 and S4 nerve roots, S3 was found to be dilated on its proximal part; B – opening of the S3 nerve root sheath revealed an endometrioma inside the nerve; C – the nodule was detached from the sacral bone (SB); D – final aspect of the right pelvic sidewall; ON – obturator nerve; SN – sciatic nerve.

Fibrosis

This is one of the most frequent causes of intrapelvic nerve entrapments and possibly the most well-known etiology, since Amarenco (18) described the pudendal neuralgia in cyclists, in whom the pain is a consequence of fibrotic entrapment due to continued trauma.

Despite the historical aspect, however, surgical manipulation seems to be the most frequent cause of fibrosis over the sacral plexus (Figure 9). Among the surgeries with higher risks of inducing such kinds of entrapments are the pelvic reconstructive procedures (19).

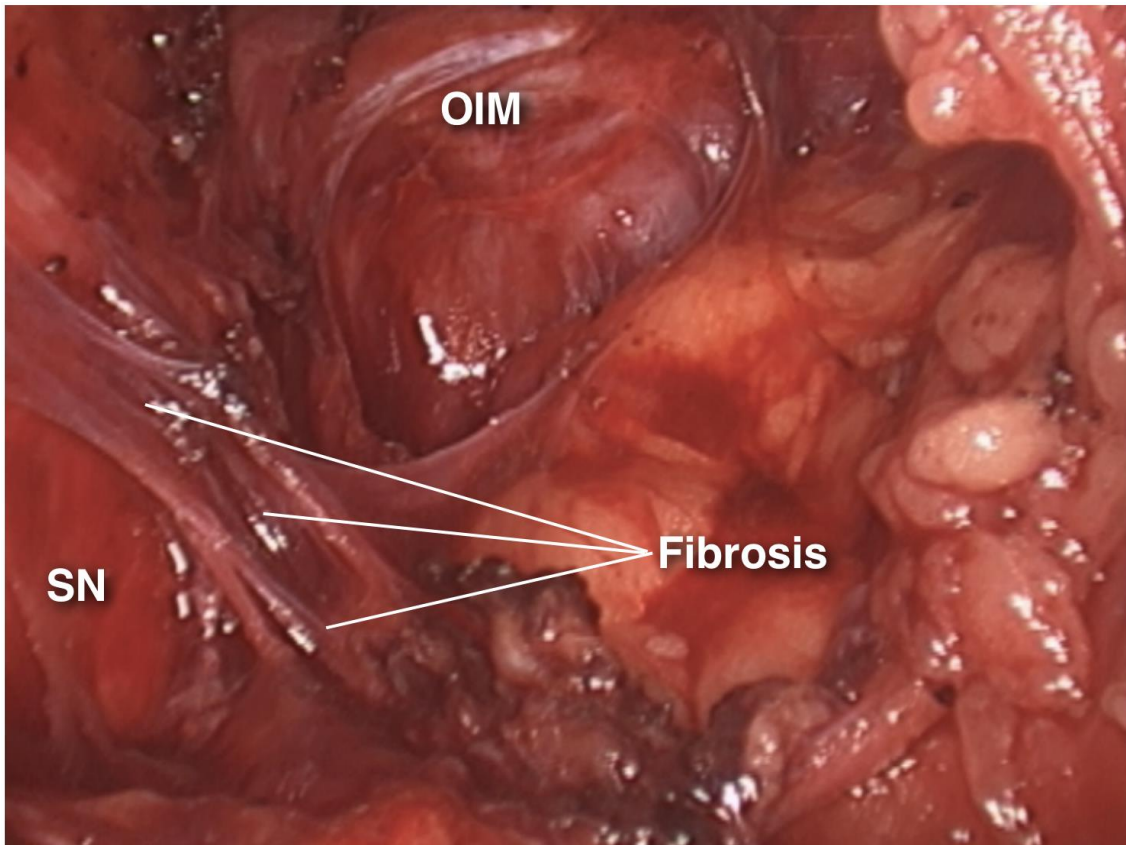


Figure 9 – Fibrotic entrapment of the left sciatic nerve

Vascular Entrapment

Pelvic congestion syndrome is a well-known cause of cyclic pelvic pain. Patients commonly present with pelvic pain without evidence of inflammatory disease. The pain is worse during the premenstrual period and pregnancy, and is exacerbated by fatigue and standing (20).

However, what is much less known is the fact that dilated or malformed branches of the internal or external iliac vessels can entrap the nerves of the sacral plexus against the pelvic sidewalls, producing symptoms such as sciatica, or refractory urinary and anorectal dysfunction (2, 21) (Figure 10).

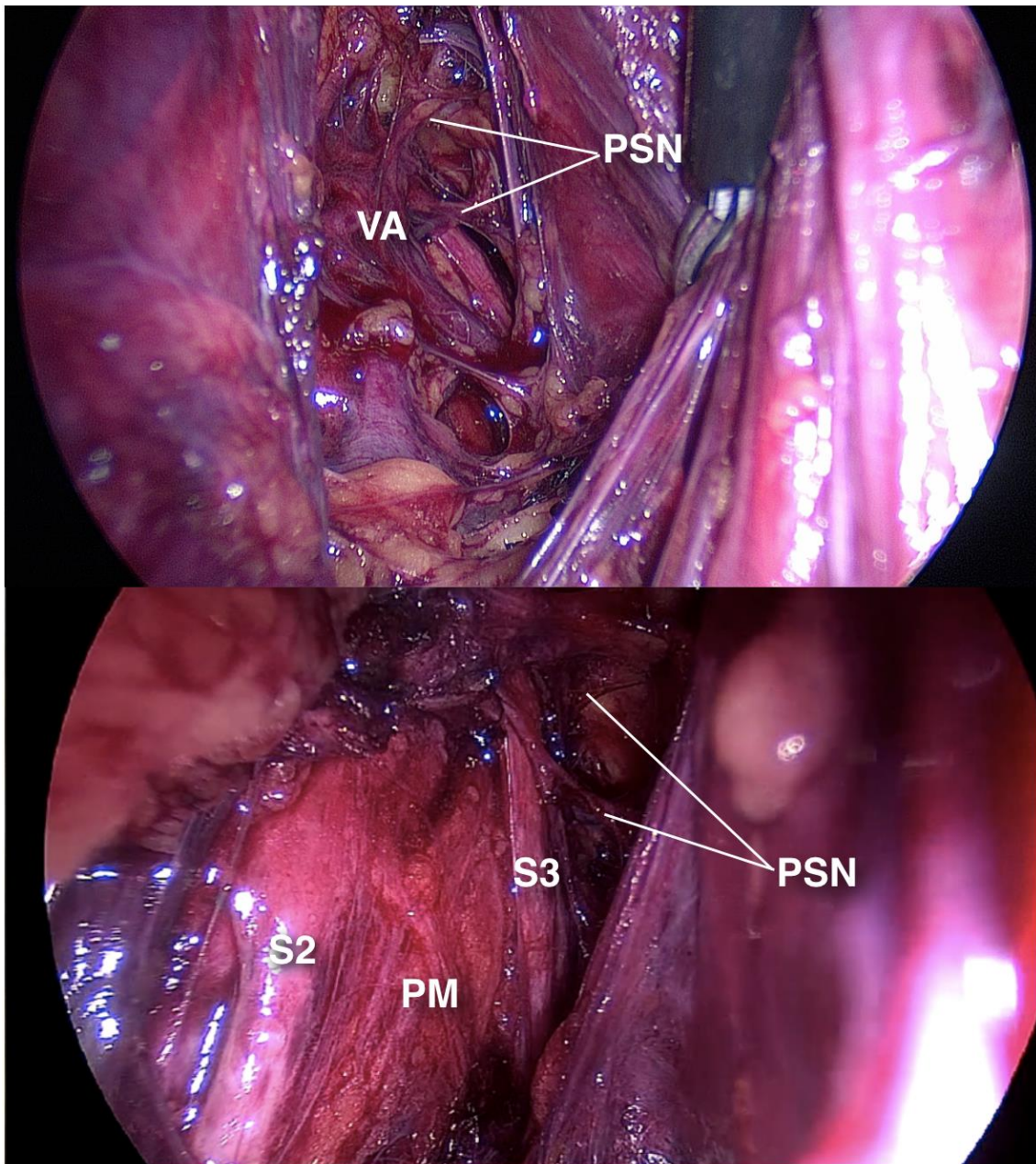


Figure 10 – Varicose tributary (VA) of the left internal iliac vein entrapping the S2 and S3 nerve roots against the left piriformis muscle (PM)

Piriformis Syndrome

Numerous malformations of the piriformis muscle have been described in the deep gluteal space that can entrap branches of the sciatic nerve. The laparoscopic approach has revealed that the intrapelvic fibers of this muscle can also entrap the sacral nerve roots (22). Usually, these fibers originate from the sacral bone, laterally to the sacral foramina. However, part of the piriformis fibers may originate medially to the sacral foramina and the corresponding nerve roots in some individuals (Figure 11). Differentiating intrapelvic from extrapelvic piriformis syndrome can be very challenging. Bowel and urinary symptoms are a good indication that the entrapment is intrapelvic, but these are not always present.

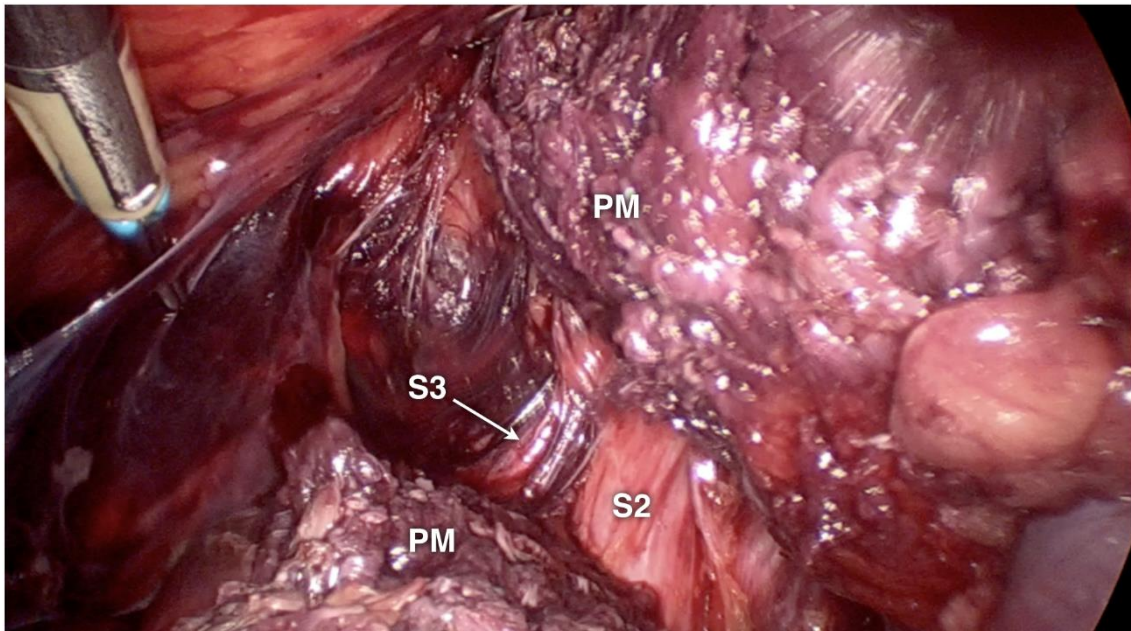


Figure 11 – Muscular entrapment of the right S2 and S3 nerve roots. Observe the transected piriformis muscle bundle (PM) originating from the sacral bone medially from the sacral nerve roots and, therefore, crushing the nerves every time the muscle contracts.

Neoplasms

Tumors can also entrap the nerves or nerve roots. Tumors can be primary neural tumors, such as Schwannomas, or metastatic tumors, such as pelvic lymph nodes, entrapping the nerves in pelvic malignancies (Figure 12).

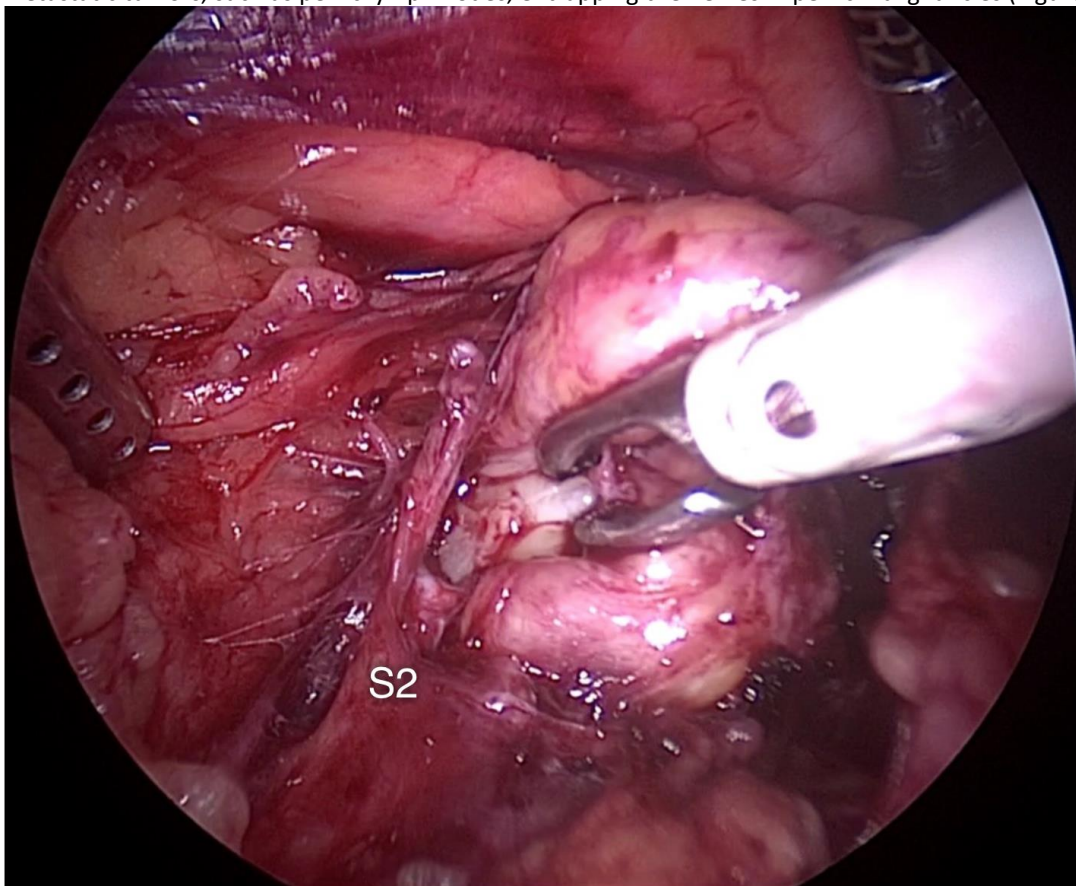


Figure 12 – Schwannoma in S2 (left)

Primary Neuropathic Pain, Nerve Transection and Secondary Neuropathic Pain

All the previously described causes of intrapelvic neuropathies have extrinsic entrapment as the etiology of pain. Intrapelvic radiculopathies can also result from nerve transections and or degenerations or intrinsic dysfunctions of the nerves themselves.

Nerve transections can occur during surgery or trauma and can induce neuroma formation, resulting in phantom pain and anesthesia of the affected nerve dermatome. An example of this is the phantom pain secondary to amputations, where branches of the sciatic and femoral nerves are transected. In the same fashion, pudendal transection will induce perineal pain and perineal anesthesia, as well as unilateral atrophy of perineal muscles, frequently resulting in urinary and fecal incontinence.

In entrapment syndromes, chronic ischemia induces cytoarchitectural changes to the neuron, which do not heal properly after the detrapment, resulting in neuropathic pain. The later the detrapment is performed, the higher the risk of neuropathic pain (23).

Neuropathic pain can also result from metabolic disturbances of the neuron, infectious agents, chronic exposure to neurotoxic substances, or a myriad of other causes.

In cases where there is no suspicion of entrapment as the primary cause of symptoms, extensive neurological investigation must be performed, preferably by a neurologist trained in assessing peripheral nerve pain. The symptoms must be clinically treated by an interprofessional pain team composed of a pain physician (usually an anesthesiologist or neurologist), a physiotherapy team (pelvic and motor), and a mental healthcare team (psychologist and psychiatrist). The pain specialist will prescribe and adjust the pharmacological treatment and, in cases where poor response to medical treatment is observed, perform the appropriate intervention (e.g. anesthetic blocks, pulsed radiofrequency).

As a rule, once a nerve entrapment has been diagnosed, decompression (usually surgical) is mandatory, since chronic ischemia can lead to endoneurial degeneration (23). Therefore, the longer the time between the beginning of symptoms and detrapment, the lower the chance of success.

Surgical decompression will lead to complete resolution of pain and other symptoms in about 30% of the patients; around 50% will experience more than 50% reduction in pain and about 20% will not improve or, in some cases, experience worsening of their pain. Approximately 25% of patients will present with post-decompression neuropathic pain and 17% will present neuropathic strength loss, both of which tend to be transient; the former will last, on average, 5.5 months and the latter will last 2.5 months (24).

Patients who present with transient post-decompression pain, persistent post-neuropathic pain or worsening of symptoms, should be treated like patients with primary neuropathic pain, as described in the following session.

Pharmacological Treatment

There are no specific recommendations for the treatment of neuropathic pain of intra-pelvic origin. Management of this group of patient will follow the recommendation of neuropathic pain in general. Antidepressants, anticonvulsants, local anesthetics, N-methyl-D-aspartate (NMDA) antagonists, opioids, cannabinoids, botulinum toxin, capsaicin, and others may be used (25-27). Most of these drugs were originally developed for other indications (e.g. depression and epilepsy), and their effectiveness for controlling neuropathic pain was later verified. The following tables outline commonly used drugs used for neuropathic pain control:

– Anticonvulsants

Carbamazepine	400 to 1600 mg / day
Oxcarbazepine	600 to 1200 mg / day
Diphenylhydantoin	300 to 400 mg / day
Valproate Sodium	500 to 1500 mg / day
Lamotrigine	50 to 400 mg / day
Topiramate	50 to 200 mg / day
Gabapentin	900 at 2400 mg / day
Pregabalin	150 to 300 mg / day

– Antidepressants

Amitriptyline	50 to 150 mg / day
Nortriptyline	50 to 150 mg / day
Maprotiline	50 to 150 mg / day
Duloxetine	60 mg / day

– Neuroleptics

Fluphenazine	2 to 20 mg / day
Levomepromazine	25 to 500 mg / day
Chlorpromazine	50 at 600 mg / day

– Antiarrhythmics

Lidocaine	5 mg/kg/h/6h
Mexiletine	600 mg / day

– Central Acting Muscle Relaxants

Baclofen	10 to 30 mg / day
----------	-------------------

– Opioids

Tramadol	100 to 300 mg / day
Oxycodone	20 to 60 mg / day
Morphine Sulfate	20 to 90 mg / day
Methadone	150 to 400 mg / day
Transdermal Fentanyl	Up to 75 mg / day

– Local anesthetics

Capsaicin
Anti-inflammatories

Interventional Treatments

Interventional procedures are an important option for the treatment of pelvic and perineal neuropathic pain. This is true especially for patients in whom conservative treatment did not bring the expected relief from pain, or for those whom the adverse effects of medications are intolerable.

The percutaneous blockade of specific nerves serves both diagnostic and therapeutic roles. In addition to the local anesthetic, it is quite common to add depot steroid for the anti-inflammatory and membrane-stabilizing effect. Imaged guidance with ultrasound (37,38), computed tomography, or fluoroscopy (39) enhanced the accuracy, reduce the volume of injectate and potentially minimize the complication rates.

If the pain relief is temporary, it is possible to apply more lasting techniques, such as radiofrequency, cryoablation, or neurolysis by chemical agents, such as phenol.

In the case of neuralgia caused by nervous incarceration by a muscle, there is the possibility of infiltration of this muscle with local anesthetic at first, followed by specific physiotherapy (40; 41). If this muscle contracts again, resulting again in nervous compression, it is possible to inject botulinum toxin, for a more prolonged relaxation. These techniques are best described in the myofascial pain chapter.

Pulsed Radio Frequency (RFP) is an alternative technique to conventional radiofrequency, and its advantage would be a longer pain relief without neural damage. During RFP application, a high frequency, pulsed current is generated and this allows the heat generated in the tissue to dissipate during the latency periods, not exceeding 45°C, which would be a neurodestructive temperature. (42). Thus, by maintaining the temperature only up to 42°C, there is no neural destruction, and, therefore, can be applied even in mixed nerves (i.e. both sensory and motor). The mechanism of action of the RFP is related to the electric field formed, which would alter painful signaling in a neuromodulatory form, but has not yet been fully elucidated (42,43). The RFP can be applied distally to the nerve responsible for the patient's pain, or proximal, at its exit in the intervertebral foramen.

The Dorsal Root Ganglia (DRG) block corresponding to the nerve responsible for the pain can be performed with local anesthetic, guided by fluoroscopy. If the blockage alleviates at least 50% of the pain, it is possible to apply RFP thereafter (38).

Phenol Neurolysis has been described in several targets, especially to treat cancer pain, but also for non-cancer pain, and may bring prolonged pain relief. Care must be taken not to inject near motor nerves, because of the risk of flaccid paralysis. Chemical neuritis is another possible complication, although uncommon (44).

Cryoablation is a technique that promotes prolonged analgesia. The application of tissue cold blocks nerve conduction is similar to the local anesthetic. Long-term analgesia is due to freezing, which damages the nerve structure and causes Wallerian degeneration. However, since the myelin sheath and endoneurium remain intact, the nerve can regenerate after a period of time. One of its advantages over other neurolysis techniques, such as phenol for example, is the absence of post-procedure neuritis (39).

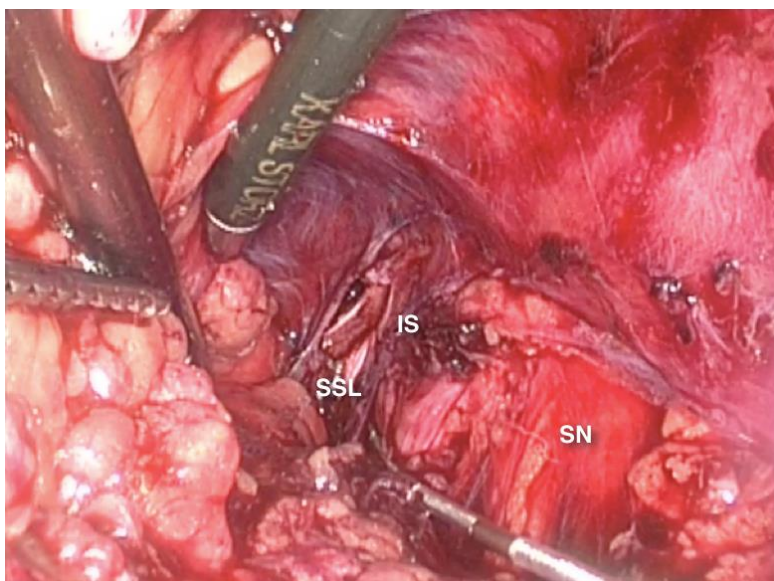
The main complications described with these procedures are similar to those experienced with any injection, including hematoma, infection and nerve damage.

Neuromodulation

In cases where medical and intervention pain treatment has failed or in cases where, although the topography of the lesion is determined, its etiology cannot be identified intraoperatively, the laparoscopic implantation of neuromodulation electrodes can be used to specifically modulate the affected nerve, producing very encouraging results when compared to the more commonly available epidural neuromodulation (5, 45).

The laparoscopic implantation of neuroprosthesis – the LION procedure – was first reported by Possover in 2009 as a rescue procedure in patients with local complications of a Brindley procedure (45). Due to its successful results and decreased invasiveness, it was then used as a primary procedure in spinal cord-injured patients, aiming to improve locomotion and bladder function (46). Long term data has shown improvement in voluntary motor function and sensitivity, suggesting positive effects on neuroplasticity (47) (Figure 13).

Figure 13: LION Electrode placed on right sciatic and pudendal nerves (PM – Psoas Muscle; IS – Ischial Spine; SN – Sciatic Nerve; SSL – Sacrospinous Ligament)



ROLE, TECHNIQUES AND RATIONALE OF PHYSICAL THERAPY ON THE POST-OPERATIVE TREATMENT OF INTRAPELVIC NERVE

ENTRAPMENTS – MARILIA FRARE

Sacral nerve roots give origin to both somatic and parasympathetic nerves. Therefore, entrapments of these roots will produce pain on their somatic dermatomes, as well as urinary and bowel dysfunction.

It is recognized that more than 85% of patients with chronic pelvic pain have dysfunction of the musculoskeletal system, including lumbar hyperlordosis, knee hyperextension and pelvic anteriority, as well as spasm of the levator ani muscle and piriformis syndrome. In patients with intrapelvic nerve entrapments, the average time between the onset of symptoms and diagnosis is more than 5 years. This delay in diagnosis leads most of these patients to developing an abnormal posture, in an attempt to relieve pain, leading to chronic muscle, joint and ligament tension, which becomes a secondary, self-sustained, source of pain itself.

Moreover, despite the high success rate of laparoscopic detrapments, only a third of the patients experienced complete remission of pain. It is important to educate patients that when dealing with nerve entrapment, success means significant pain score and medication reduction and that complete symptom relief is often not accomplished.

In that sense, the role of pelvic physiotherapy is to treat all muscle unbalances related to chronic pelvic pain, collaborate with the psychological support on the coping with chronic pain and post-decompression symptoms, as well as providing specific analgesic measurements to help reduce post-decompression neuropathic pain, collaborating for a faster reduction of analgesic intake.

Initial physical therapy assessment is composed of a complete anamnesis to understand the remaining symptoms about bladder and bowel function, postural evaluation and a manual pelvic muscle examination to identify internal and external pelvic myofascial trigger points.

In pelvic dysfunction resulting from nerve compression, the main goals of physical therapy are to reduce pain, train the pelvic floor muscles, and provide education about dysfunction and lifestyle interventions. This includes teaching awareness of the pelvic muscle group, the correct way to contract the pelvic muscles, coordination, motor control, strength, endurance, and relaxation of the musculature (28, 29, 30).

In order to reduce the patient's pain after surgical nerve decompression, cryotherapy has proven to be an effective therapeutic resource when applied to the vaginal canal. It is recommended to fill a non-sterile glove finger (or a condom) with ice and insert it into the patient's vagina for less than 20 minutes.

Electrical stimulation is also an important resource in the treatment of pain. It stimulates the rapidly conducting myelinated gross nerve fibers, triggering at the central level the descending inhibitory analgesic systems on the nociceptive transmission conducted by the non-myelinated fibers of small caliber, thus generating pain reduction (31, 32)

Manual therapy techniques for myofascial release should be applied when there are signs of muscular tension of the pelvic floor, with the presence of trigger points, due to pain caused by nerve compression. The technique involves firm massage on the levator anus muscle with sliding movements towards the origin and insertion, punctual pressure at the trigger points at the limit of the patient's pain, in addition to perpendicular movements to the muscle fiber (33).

The techniques described for strengthening and awareness of pelvic floor musculature include biofeedback, and electrostimulation. These represent an important form of prevention and treatment for pelvic floor dysfunction.

Biofeedback is one of the most used resources for urogynecological physiotherapy, since it has no side effects. This technique allows the objective awareness of the physiological function that is unconscious in the individual, facilitating the correct learning of the pelvic floor muscle contraction. It can also be used for training and hypertrophy of the muscles. In addition, biofeedback assists in patient motivation during treatment, improving adherence to the physiotherapy program (34, 35).

Electrical stimulation, when applied in the vaginal canal acts passively, and has an important effect on the proprioceptive awakening along with stimulating the correct learning of the perineal contraction. In addition, it has shown effective therapeutic results in patients with pelvic floor dysfunction, contributing to training of strength and muscular endurance, increasing the number of activated motor units and generating hypertrophy of the fibers. These benefits promote a strong and rapid contraction of the muscles, increasing urethral pressure and preventing urine loss during an abrupt increase in intra-abdominal pressure (36).

The laparoscopic approach to the intrapelvic bundles of the lumbosacral nerves opened a myriad of possibilities to assess and treat this neglected portion of the plexus, by means of nerve decompression or selective neuromodulation.

MUSCULOSKELETAL NERVE ENTRAPMENTS AND MYOFASCIAL PAIN- THE ROLE OF PHYSICAL – NELLY FAGHANI

Physiotherapy is an integral part of the interdisciplinary team that must take a comprehensive framework with a biopsychosocial approach when treating pelvic pain/dysfunction (Hilton et al 2011).

There is no standard protocol for treating chronic pelvic pain. A thorough history and physical examination will help identify contributors to chronic pelvic pain. The use of validated and reliable outcome measures will help in our assessment of our client's attitudes and beliefs and hence allow us to target the right therapies for them.

There are a variety of terms and definitions used in the literature to describe the state of the pelvic floor including hyperactive and hypertonic pelvic floor muscles, which we will refer to as overactive pelvic floor muscles (OAPF) (Paoda et al 2016). OAPF muscles can be a contributor to the pelvic pain that our clients experience. There are a myriad of possible

etiologies for the onset/existence of OAPF, and it is important to identify what the predominant 'drivers' or 'threats' are in each person, and then develop an effective strategy to treat these. Some of these etiologies include (but are not limited to) direct trauma, psychological distress (anxiety, fear or pain), psychosocial/psychosexual disturbances (trauma, abuse, poor relationships), postural abnormalities, abnormal behaviors and/or patterns of pelvic floor use (constipation, delayed voiding).

Using a biopsychosocial approach means we must look at the current understanding of local tissue dysfunction with the wider context of sensitized protective mechanisms within the spinal cord and brain. We need to treat both the local tissue complaints and the central nervous system sensitivity by teaching patients about the biological processes underpinning their pain. There is also compelling evidence that pain education reduces pain, disability, catastrophization and improves physical performance (Louw et al, 2012). Overactivity of the pelvic floor is not simply an isolated dysfunction, but can be a physical manifestation of the patient's emotional state. In cases of actual or imminent physical or mental pain or anxiety the pelvic floor muscles will involuntarily, and often unconsciously, contract. Pelvic floor overactivity in threatening situations should be regarded as part of a general defense mechanism (Van der Velde et al., 2001). Interventions that target psychological variables in women with CPP do not appear to be widely used by physical therapists to complement traditional physical therapy interventions (Allapatu 2011). Thoughts are nerve impulses, and negative thinking alone can drive the pain (Moseley 2008).

A sensitized nervous system, caused by stress, anxiety, fear, catastrophization, a weakened immune system, hormonal imbalance, poor diet, or a heightened sympathetic nervous system response (constant fight or flight response) can also drive our clients pain state in the absence of any tissue problems

In order to get best outcomes, we must address the 'drivers' of our client's pain. Our focus during treatment must be on function and quality of life. We must continue to empower our clients with self-efficacy and give them hope. Treatment strategies can consist of:

- Pain education
- Bowel and bladder education/training
- Diet modification
- Deep breathing
- Postural and ergonomic education
- Address peripheral mediators of OAPF with non-nociceptive manual therapy
- Improve proprioception and pelvic floor function
- Appropriate cardiovascular exercise
- Guided relaxation and/or meditation
- Mindfulness practice
- CBT
- Graded imagery/exposure
- Improve sleep hygiene
- Yoga/Qi gong/Tai chi
- Knowing when to refer

REFERENCES

1. Gray, Henry. 1918. *Anatomy of the Human Body*. IX. Neurology. 6d. The Lumbosacral Plexus.
2. Possover M, Schneider T, Henle KP (2011) Laparoscopic therapy for endometriosis and vascular entrapment of sacral plexus. *Fertil Steril* 95(2):756-8.
3. Possover M, Chiantera V, Baekelandt J (2007) Anatomy of the Sacral Roots and the Pelvic Splanchnic Nerves in Women Using the LANN Technique. *Surg Laparosc Endosc Percutan Tech* 17(6): 508-10.
4. Whiteside JL, Barber MD, Walters MD, Falcone TA (2003) Anatomy of ilioinguinal and iliohypogastric nerves in relation to trocar placement and low transverse incisions. *Am J Obstet Gynecol* 180(6): 1574-8.
5. Possover M. Use of the LION procedure on the sensitive branches of the lumbar plexus for the treatment of intractable postherniorrhaphy neuropathic inguinodynia. *Hernia*. 2013 Jun;17(3):333-7. doi: 10.1007/s10029-011-0894-x.
6. Grigorescu BA, Lazarou G, Olson TR, Downie SA, Powers K, Greston WM, Mikhail MS. Innervation of the levator ani muscles: description of the nerve branches to the pubococcygeus, iliococcygeus, and puborectalis muscles. *Int Urogynecol J Pelvic Floor Dysfunct*. 2008 Jan;19(1):107-16.
7. Barber MD, Bremer RE, Thor KB, Dolber PC, Kuehl TJ, Coates KW. Innervation of the female levator ani muscles. *Am J Obstet Gynecol*. 2002 Jul;187(1):64-71.
8. Wallner C, van Wissen J, Maas CP, Dabhoiwala NF, DeRuiter MC, Lamers WH. The contribution of the levator ani nerve and the pudendal nerve to the innervation of the levator ani muscles; a study in human fetuses. *Eur Urol*. 2008 Nov;54(5):1136-42.
9. DeGroat WC, Yoshimura N. *Anatomy and Physiology of the Lower Urinary Tract*. In: *Handbook of Clinical Neurology* 3rd Series. Ed. Elsevier. Oxford, UK, 2015.

10. Possover M, Baekelandt J, Flaskamp C, Li D, Chiantera V. Laparoscopic neurolysis of the sacral plexus and the sciatic nerve for extensive endometriosis of the pelvic wall. *Minim Invasive Neurosurg.* 2007 Feb; 50(1):33-6
11. Bouche P. Compression and entrapment neuropathies. *Handb Clin Neurol.* 2013; 115:311-66.
12. van der Jagt PK, Dik P, Froeling M, Kwee TC, Nievelstein RA, ten Haken B, Leemans A. Architectural configuration and microstructural properties of the sacral plexus: a diffusion tensor MRI and fiber tractography study. *Neuroimage.* 2012 62(3):1792-9. doi:10.1016/j.neuroimage.2012.06.001.
13. Denton RO, Sherrill JD. Sciatic syndrome due to endometriosis of sciatic nerve. *South Med J.* 1955 Oct;48(10):1027-31.
14. Lemos N, Kamergorodsky G, Ploger C, Castro R, Schor E, Girão M. Sacral nerve infiltrative endometriosis presenting as perimenstrual right-sided sciatica and bladder atonia: case report and description of surgical technique. *J Minim Invasive Gynecol.* 2012 May-Jun;19(3):396-400. doi: 10.1016/j.jmig.2012.02.001.
15. Lemos N, D'Amico N, Marques R, Kamergorodsky G, Schor E, Girão MJ. Recognition and treatment of endometriosis involving the sacral nerve roots. *Int Urogynecol J.* 2016 Jan; 27(1):147-50
16. Missmer SA, Bove GM. A pilot study of the prevalence of leg pain among women with endometriosis. *J Body Mov Ther.* 2011 Jul;15(3):304-8. doi: 10.1016/j.jbmt.2011.02.001.
17. Pacchiarotti A, Milazzo GN, Biasiotta A, Truini A, Antonini G, Frati P, Gentile V, Caserta D, Moscarini M. Pain in the upper anterior-lateral part of the thigh in women affected by endometriosis: study of sensitive neuropathy. *Fertil Steril.* 2013 Jul;100(1):122-6. doi: 10.1016/j.fertnstert.2013.02.045.
18. Amarenco G, Lanoe Y, Perrigot M, Goudal H. [A new canal syndrome: compression of the pudendal nerve in Alcock's canal or perineal paralysis of cyclists]. *Presse Med.* 1987 Mar 7;16(8):399.
19. Possover M, Lemos N. Risks, symptoms, and management of pelvic nerve damage secondary to surgery for pelvic organ prolapse: a report of 95 cases. *Int Urogynecol J.* 2011 Dec;22(12):1485-90. doi: 10.1007/s00192-011-1539-4.
20. Ganeshan A, Upponi S, Hon LQ, Uthappa MC, Warakaulle DR, Uberoi R. Chronic pelvic pain due to pelvic congestion syndrome: the role of diagnostic and interventional radiology. *Cardiovasc Intervent Radiol.* 2007 Nov-Dec;30(6):1105-11.
21. Lemos N, Marques RM, Kamergorodsky G, Ploger C, Schor E, Girão M. Vascular entrapment of the sciatic plexus causing catamenial sciatica and urinary symptoms. In: 44th Annual Meeting of the International Continence Society (ICS), 2014, Rio de Janeiro. *Neurourology and Urodynamics.* Hoboken, NJ: Willey, 2014. v. 33. p. 999-1000. doi: 10.1016/j.jbmt.2011.02.001.
22. Possover M. The sacral LION procedure for recovery of bladder/rectum/sexual functions in paraplegic patients after explantation of a previous Finetech-Brindley controller. *J Minim Invasive Gynecol.* 2009 Jan-Feb;16(1):98-101.
23. Rempel D, Dahlin L. Pathophysiology of Nerve Compression Syndromes: Response of Peripheral Nerves to Loading. *J Bone Joint Surg Am.* 1999 Nov; 81 (11): 1600 -10 .
24. Lemos et al. Intrapelvic nerve entrapments – a neglected cause of perineal pain and urinary symptoms. In: “Scientific Programme, 45th Annual Meeting of the International Continence Society (ICS), 6-9 October 2015, Montreal, Canada.” *Neurourol Urodyn.* 2015 Aug;34 Suppl 3:S53-S55. doi: 10.1002/nau.22830.
25. Finnerup N, Attal N, Haroutounian S, McNicol E, Baron R, Dworkin R et al. Pharmacotherapy for neuropathic pain in adults: a systematic review and meta-analysis. *The Lancet Neurology.* 2015;14(2):162-173.
26. Haanpää M, Attal N, Backonja M, Baron R, Bennett M, Bouhassira D et al. NeuPSIG guidelines on neuropathic pain assessment. *Pain.* 2011;152(1):14-27.
27. Attal N, Cruccu G, Baron R, Haanpää M, Hansson P, Jensen T et al. EFNS guidelines on the pharmacological treatment of neuropathic pain: 2010 revision. *European Journal of Neurology.* 2010;17(9):1113-e88.
28. Bo K, Berghmans B, Morkved S, Van Kampen M. *Evidence-Based Physical Therapy for the Pelvic Floor.* 2nd Ed. China: Elsevier; 2007.
29. Weiss JM. Pelvic floor miofascial trigger points: manual therapy for interstitial cystitis and the urgency-frequency syndrome. *J Urol.* 2001, Dec; 166: 2226-2231.
30. Stockdale CK, Lawson HW. 2013 Vulvodynia Guideline update. *J Low Genit Tract Dis.* 2014 Apr;18(2):93-100. doi: 10.1097/LGT.0000000000000021.
31. Robinson AJ, Snyder-Mackler L. *Eletrofisiologia clínica: eletroterapia e teste fisiológico.* 3 ed. Porto Alegre: Artmed; 2010.
32. Fitzwater JB, Kuehl TJ, Schrier JJ. Electrical stimulation in the treatment of pelvic pain due to levator ani spasm. *J Reprod Med.* 2003; 48: 573-577
33. Srinivasan AK, Kaye JD, Moldwin R. Myofascial dysfunction associated with chronic pelvic pain: management strategies. *Curr Pain Headache Rep.* 2007, Oct; 11(5): 359-64

34. Fitz FF, Resende APM, Stüpp L, Costa TF, Sartori MGF, Girão MJBC, Castro RA. Efeito da adição do biofeedback ao treinamento dos músculos do assoalho pélvico para tratamento da incontinência urinária de esforço. *Rev Bras Ginecol Obstet*. 2012; 34 (11): 505-10.
35. Moreno, AL. *Fisioterapia em Uroginecologia*. São Paulo: Manole; 2004
36. Palma, P (ed). *Urofisioterapia aplicações clínicas das técnicas fisioterapêuticas nas disfunções miccionais e do assoalho pélvico*. Campinas/SP: Personal Link Comunicações; 2009.
37. Bendtsen TF, Lönnqvist PA, Jepsen KV, Petersen M, Knudsen L, Børglum J. Preliminary results of a new ultrasound-guided approach to block the sacral plexus: the parasacral parallel shift. *Br J Anaesth*. 2011 Aug;107(2):278-80. doi: 10.1093/bja/aer216.
38. Peng PWH, Tumber PS. Ultrasound-Guided Interventional Procedures for Patients with Chronic Pelvic Pain – A Description of Techniques and Review of Literature. *Pain Physician*. 2008; 11:215-224.
39. Trescot AM. Cryoanalgesia in Interventional Pain Management. *Pain Physician*. 2003; 6:345-360.
40. Ingber RS. Iliopsoas myofascial dysfunction: a treatable cause of “failed” low back syndrome. *Arch Phys Med Rehabil*. 1989; 70(5):382–6.
41. Lewit K. Manipulative Therapy in Rehabilitation of the Motor System. In: John P. Butler (ed). *Myofascial Pain and Dysfunction*. Volume 2. The Trigger Point Manual Butterworths, London. Lippincott Williams & Wilkins; 1985. p. 138, 276, 315).
42. Rozen D, Parvez U. Pulsed radiofrequency of lumbar nerve roots for treatment of chronic inguinal herniorrhaphy pain. *Pain Physician*. 2006; 9(2):153–6.
43. Cahana A, Zundert JV, Macrea L, van Kleef M, Sluijter M. Pulsed Radiofrequency: Current Clinical and Biological Literature Available. *Pain Medicine*. 2006; 7(5):411-23.
44. Weksler N, Klein M, Gurevitch B, Rozentsveig V, Rudich Z, Brill S, et al. Phenol neurolysis for severe chronic nonmalignant pain: is the old also obsolete? *Pain Med*. 2007; 8(4):332–7.
45. Possover M. Laparoscopic management of endopelvic etiologies of pudendal pain in 134 consecutive patients. *J Urol*. 2009 Apr;181(4):1732-6. doi: 10.1016/j.juro.2008.11.096.
46. Possover M, Schurch B, Henle K. New strategies of pelvic nerves stimulation for recovery of pelvic visceral functions and locomotion in paraplegics. *NeuroUrol Urodyn*. 2010; 29:1433–1438.
47. Possover M. Recovery of sensory and supraspinal control of leg movement in people with chronic paraplegia: a case series. *Arch Phys Med Rehabil*. 2014 Apr; 95(4):610-4.

A Biopsychosocial Approach to Chronic Pelvic Pain and Pudendal Neuralgia

Nelly Faghani
Registered Physiotherapist



Nelly Faghani 

Affiliations to disclose[†]:

No disclosures

* All financial ties (over the last year) that you may have with any business organisation with respect to the subjects mentioned during your presentation

Funding for speaker to attend:


Self-funded

Institution (non-industry) funded

Sponsored by:


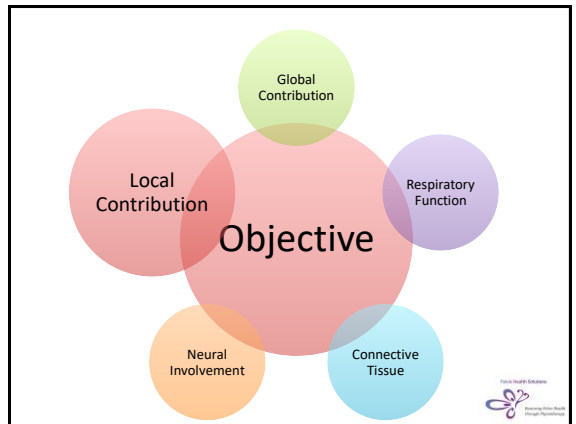
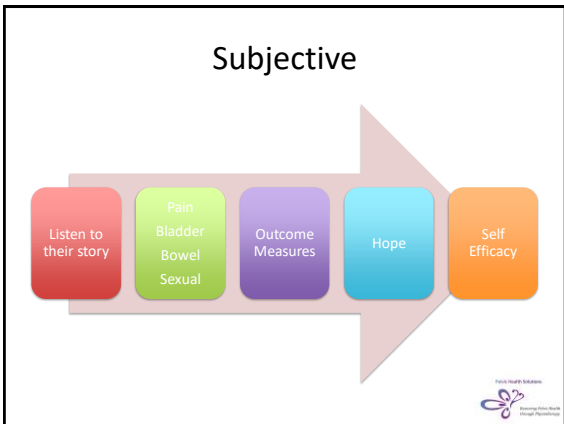
Biopsychosocial Approach

- Physiotherapy is an integral part of the interdisciplinary team that must take a comprehensive framework with a biopsychosocial approach when treating pelvic pain/dysfunction
Vandyken, Hilton 2011



Pudendal Neuralgia

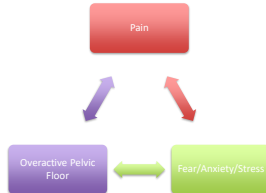
- Pelvic floor physiotherapy is considered first line therapy for pudendal neuralgia Koder et al 2014
- No standardized protocol
- Target the right “driver” of symptoms

Overactive Pelvic Floor Muscles

Paoda et al 2016

- “A condition in which the pelvic floor muscles do not relax, or may even contract when relaxation is functionally needed, for example during micturition or defecation” 2005 report from the Pelvic Floor Clinical Assessment Group of the ICS



The Psychology of the Pelvic Floor

- Overactivity of the pelvic floor is not simply an isolated dysfunction, but a physical manifestation of the patient's emotional state Rosenbaum, 2012
- In cases of actual or imminent physical or mental pain or anxiety the pelvic floor muscles will involuntarily, and often unconsciously, contract



Centralized Pain

- Interventions that target psychological variables in women with CPP do not appear to be widely used by physical therapists to complement traditional physical therapy interventions Allapatu 2011, Hartman 2011
- A meta-analysis demonstrated that physiotherapists are uncomfortable addressing psychosocial factors due to a lack of training Synnott 2015
- Differentiating pain that is more centralized could provide a mechanistic rationale for intervention Cohen SP, Raja SN. Anesthesiology 2007



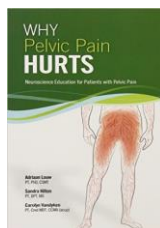
Pain

- Pain is an unpleasant sensory and emotional experience associated with actual and potential tissue damage, or described in terms of such damage Pain Definition by IASP
- Thoughts are nerve impulses, and negative thinking alone can drive the pain Moseley 2008
- There is compelling evidence that pain education reduces pain, disability, catastrophization and improves physical performance Louw et al, 2012



Treatment: Pain Education

- Pain is real
- Pain is an output of the brain 100% of the time
- Emotions
- Stress
- Thoughts
- Attitudes
- Beliefs



Physiotherapy Treatment

- Improve bladder and bowel function
- Deep breathing
- Improve sleep hygiene
- Address global contributors
- Address OAPF through internal techniques
- Nerve mobilization/flossing
- Connective tissue manipulation
- Manual lymph drainage
- Visceral manipulation



Treatment

- Evoke the relaxation response: guided relaxation, meditation, yoga, qi gong or tai chi
- Exercise: novel, fun and non irritating
- Mindfulness Kabat-Zinn, et al,1985, 1992, Brotto et al 2008, Zeldan et al 2015
- Cognitive Behavioral Therapy (CBT)
- Graded imagery/exposure Maddison et al 2012, Broadbent et al 2012
- Body mapping Hubbard, Mayer et al, JNS 2011
- Social connections
- Positive affect has been associated with better health outcomes, including chronic pain Park et al 2010



Summary

- Biopsychosocial Approach
- Interdisciplinary team
- Physiotherapy Treatment
- Start with pain education
- Target the right driver



Thank you

nelly@pelvichealthsolutions.ca

www.pelvichealthsolutions.ca





Intrapelvic Neuropathies: Guidelines for Diagnosis and Management

Nucelio Lemos, MD, PhD

Associate Professor of Obstetrics & Gynecology, University of Toronto

Head of the Pelvic Neurodysfunctions Clinic, DepT. of Gynecology - Federal University of São Paulo

Founding Member of the ISON - International Society of Neuropelveology

Chairman of the Scientific and Education Committee of the Latin American Pelvic Floor Association



WOMEN'S COLLEGE HOSPITAL
Health care for women | REVOLUTIONIZED



increasing
INSTITUTO DE CUIDADOS, REABILITAÇÃO E ASSISTÊNCIA
EM NEUROPELVEOLOGIA E GINECOLOGIA

Financial Disclosures

- Speaker/Proctorship Fee
 - Medtronic®
 - Johnson&Johnson®
- Research Grants
 - Medtronic®
 - Laborie®
- Travel & Education Grants
 - Medtronic®
 - Boston Scientific®



WOMEN'S COLLEGE HOSPITAL
Health care for women | REVOLUTIONIZED



Medical Propedeutics & Diagnostic Sequence

Syndromic Diagnosis

Symptoms & Signs

Topographic Diagnosis

Affected /Dysfunctional Organ/Tissue

Topographic Diagnosis

Affected /Dysfunctional Organ/Tissue

Topographic Diagnosis

Affected /Dysfunctional Organ/Tissue



WOMEN'S COLLEGE HOSPITAL
Health care for women | REVOLUTIONIZED



Medical Propedeutics & Diagnostic Sequence

Syndromic Diagnosis

Symptoms&Signs

Topographic Diagnosis

Affected /Dysfunctional Organ/Tissue

Etiological Diagnosis

Etiological Diagnosis

Etiological Diagnosis

Topographic Diagnosis

Affected /Dysfunctional Organ/Tissue

Etiological Diagnosis

Etiological Diagnosis

Etiological Diagnosis

Topographic Diagnosis

Affected /Dysfunctional Organ/Tissue

Etiological Diagnosis

Etiological Diagnosis

Etiological Diagnosis



WOMEN'S COLLEGE HOSPITAL
Health care for women | REVOLUTIONIZED



Mount Sinai
Hospital

Sinai Health System
Joseph & Wolf Lebovic
Health Complex



UNIVERSIDADE FEDERAL DE SÃO PAULO



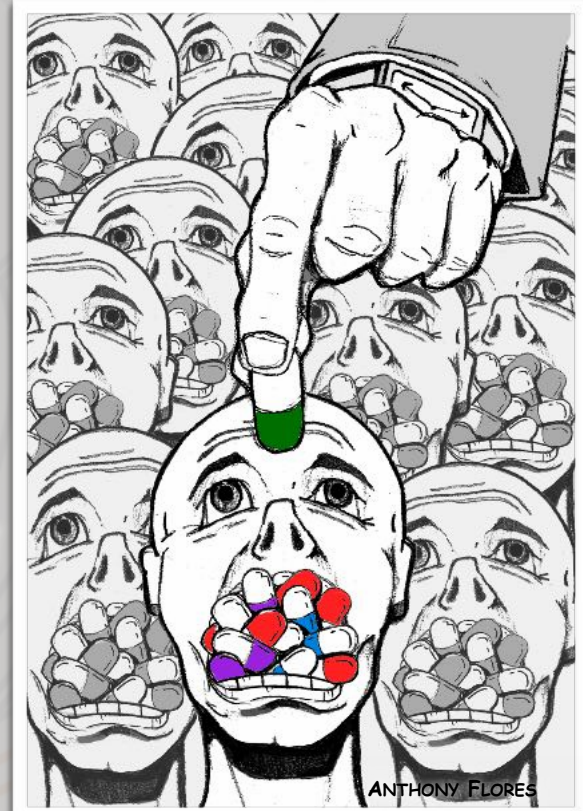
increasing
INSTITUTO DE CUIDADOS, REABILITAÇÃO E ASSISTÊNCIA
EM NEUROPELVEOLOGIA E GINECOLOGIA

The "Syndromic Era"

Syndromic Diagnosis

Symptoms&Signs

- Chronic Pelvic Pain Syndrome
- Bladder Pain Syndrome
- OAB Syndrome
- Irritable Bowel Syndrome
- Attention Deficit and Hyperactivity Disorder (Syndrome)
- Fibromyalgia
- Pudendal Neuralgia



ANTHONY FLORES



WOMEN'S COLLEGE HOSPITAL
Health care for women | REVOLUTIONIZED



Sinai Health System
Joseph & Wolf Lebovic
Health Complex



increasing
INSTITUTO DE CUIDADOS, REABILITAÇÃO E ASSISTÊNCIA
EM NEUROPELVEOLOGIA E GINECOLOGIA

The "Syndromic Era"

- How do you treat pelvic pain?
- How do you treat Sciatica?
- How do you treat Overactive Bladder (urgency)?
- How do you treat pudendal neuralgia?



UNIVERSITY OF
TORONTO

WCHI

WOMEN'S COLLEGE HOSPITAL
Health care for women | REVOLUTIONIZED



Mount Sinai
Hospital

Sinai Health System
Joseph & Wolf Lebovic
Health Complex

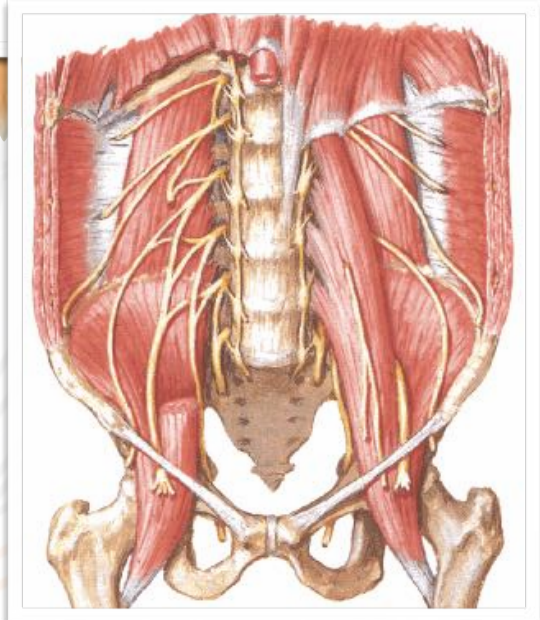
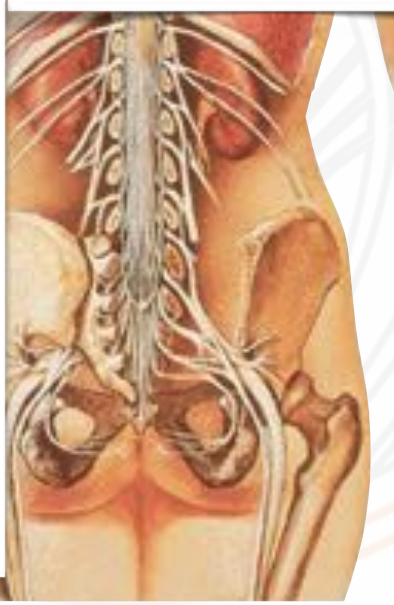
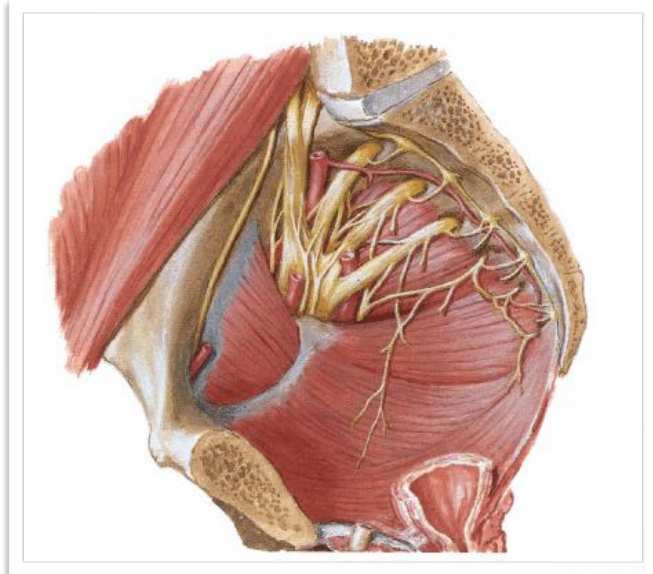
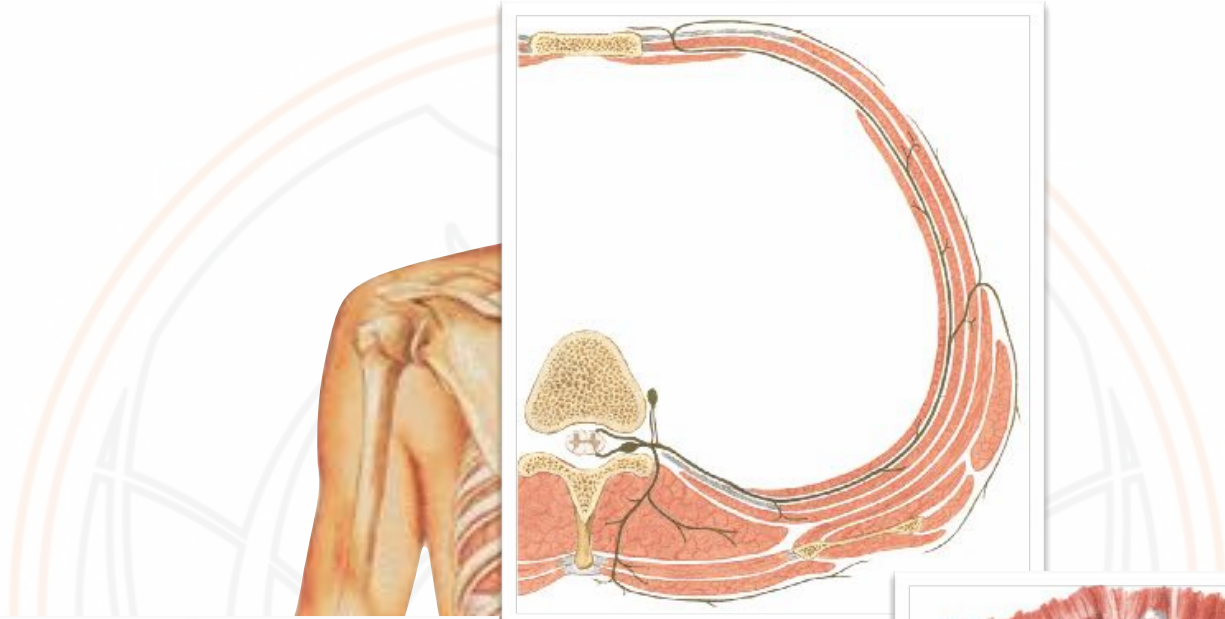


UNIFESP
UNIVERSIDADE FEDERAL DE SÃO PAULO



increasing

INSTITUTO DE CUIDADOS, REABILITAÇÃO E ASSISTÊNCIA
EM NEUROPELVEOLOGIA E GINECOLOGIA





UNIVERSITY OF
TORONTO

WCH

WOMEN'S COLLEGE HOSPITAL
Health care for women | REVOLUTIONIZED



Mount Sinai
Hospital

Sinai Health System
Joseph & Wolf Lebovic
Health Complex

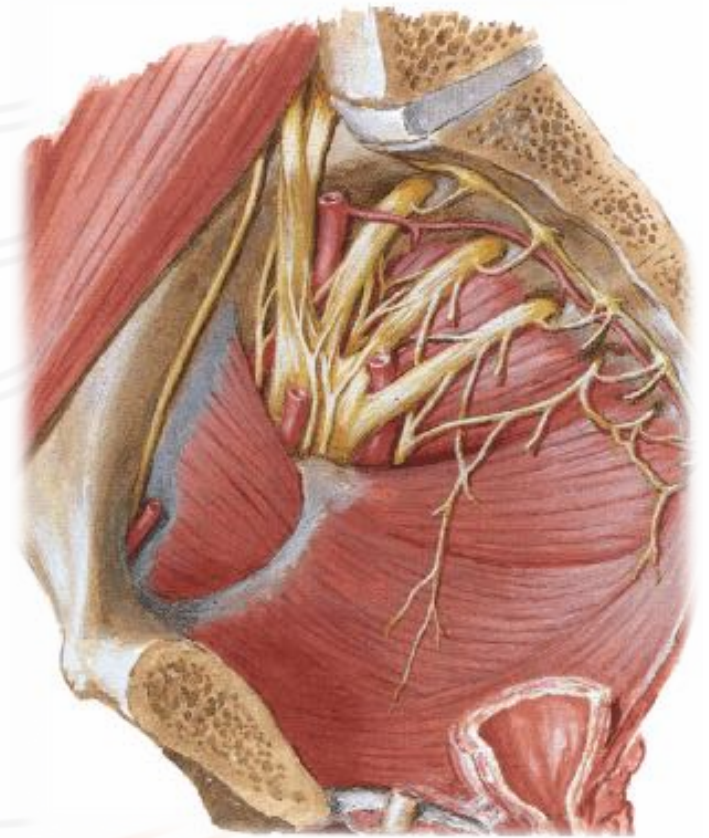
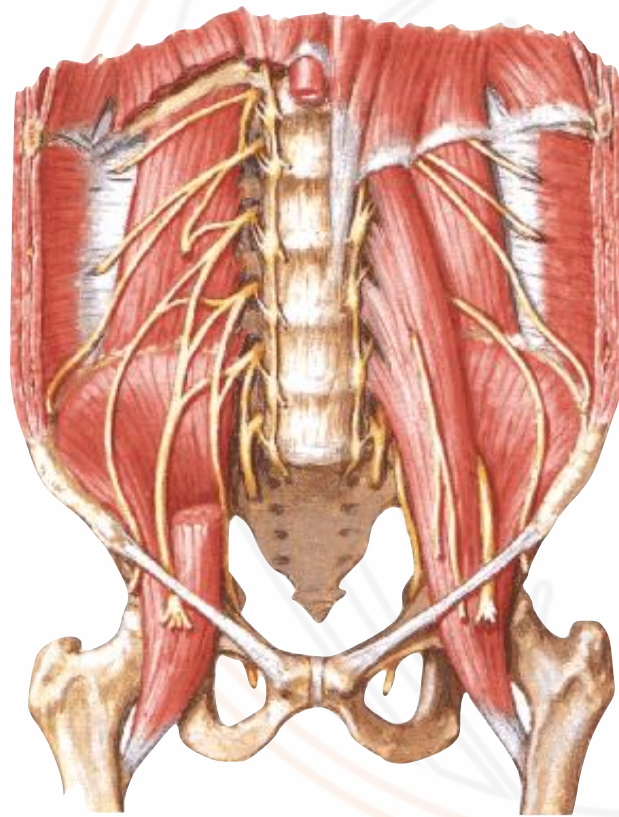


UNIFESP
UNIVERSIDADE FEDERAL DE SÃO PAULO



increasing
INSTITUTO DE CUIDADOS, REABILITAÇÃO E ASSISTÊNCIA
EM NEUROPELVEOLOGIA E GINECOLOGIA

Intrapelvic Nerves





UNIVERSITY OF
TORONTO



WOMEN'S COLLEGE HOSPITAL
Health care for women | REVOLUTIONIZED



Mount Sinai
Hospital

Sinai Health System
Joseph & Wolf Lebovic
Health Complex



UNIVERSIDADE FEDERAL DE SÃO PAULO



increasing
INSTITUTO DE CUIDADOS, REABILITAÇÃO E ASSISTÊNCIA
EM NEUROPELVEOLOGIA E GINECOLOGIA

Lumbar Nerves

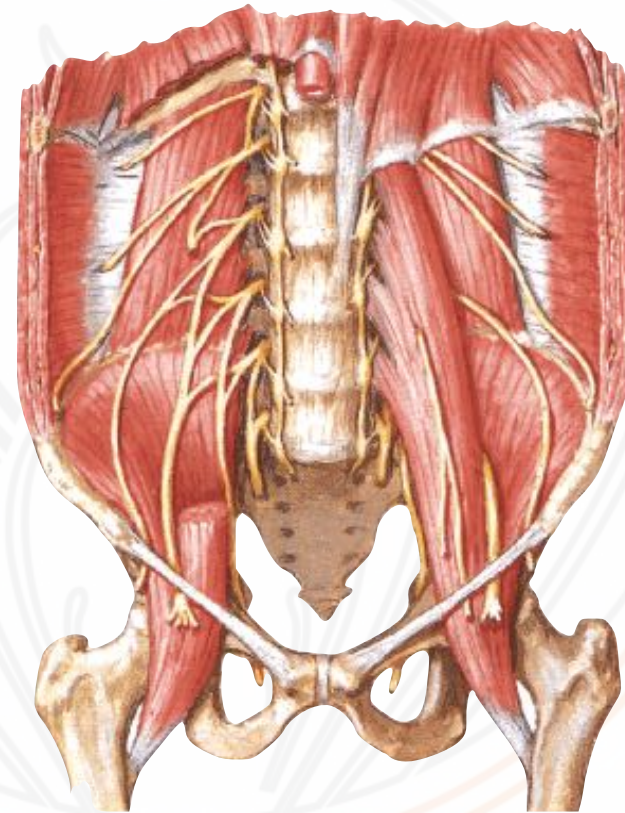
- Iliohypogastric N.

- Ilioinguinalis N.

- Genitofemoralis N.

- Femoral N.

- Obturator N.





UNIVERSITY OF
TORONTO



WOMEN'S COLLEGE HOSPITAL
Health care for women | REVOLUTIONIZED



Mount Sinai
Hospital

Sinai Health System
Joseph & Wolf Lebovic
Health Complex

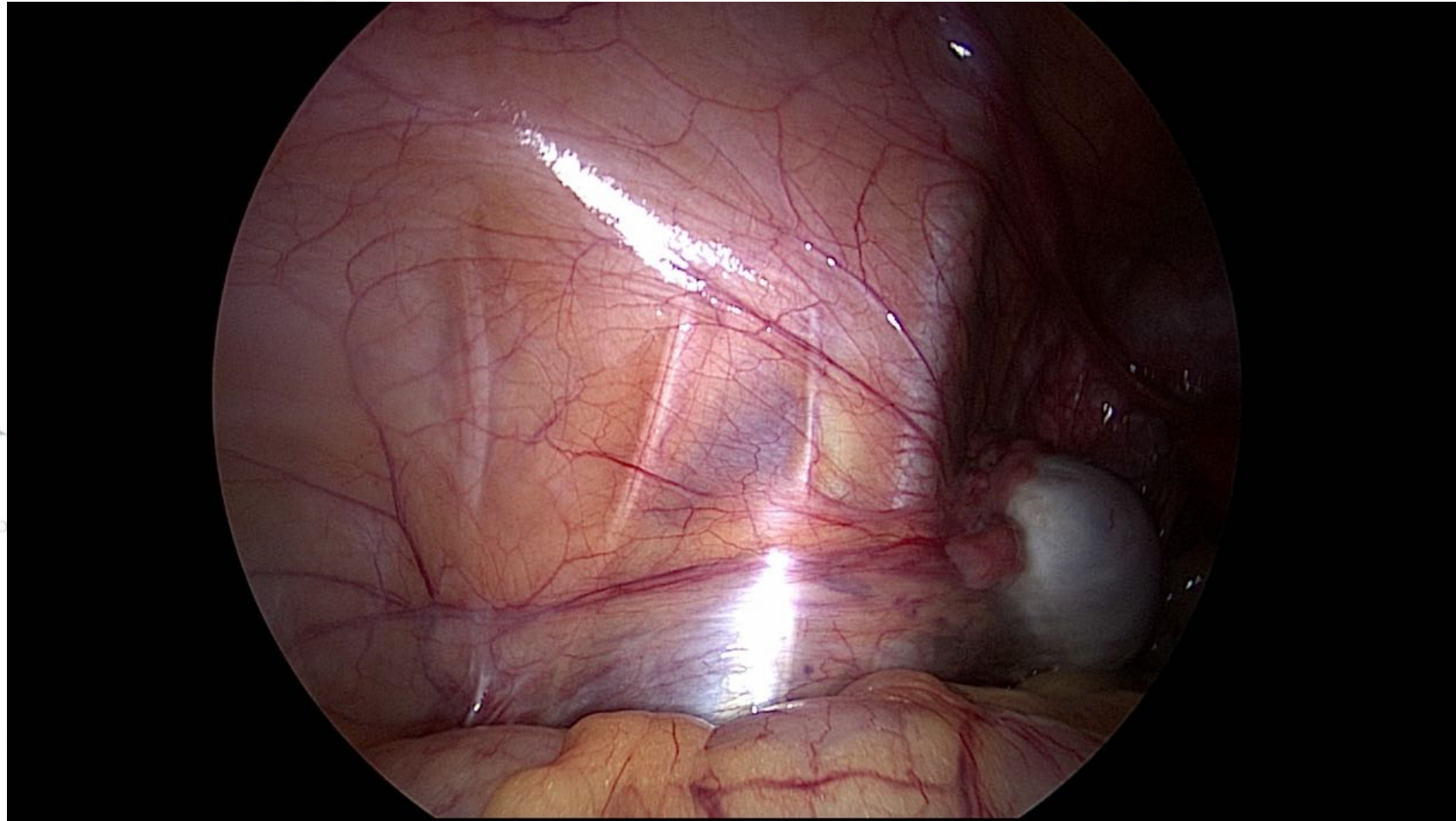


UNIVERSIDADE FEDERAL DE SÃO PAULO



increasing
INSTITUTO DE CUIDADOS, REABILITAÇÃO E ASSISTÊNCIA
EM NEUROPELVEOLOGIA E GINECOLOGIA

Somatic Nerves of the Pelvis





UNIVERSITY OF
TORONTO



WOMEN'S COLLEGE HOSPITAL
Health care for women | REVOLUTIONIZED



Mount Sinai
Hospital

Sinai Health System
Joseph & Wolf Lebovic
Health Complex



UNIFESP

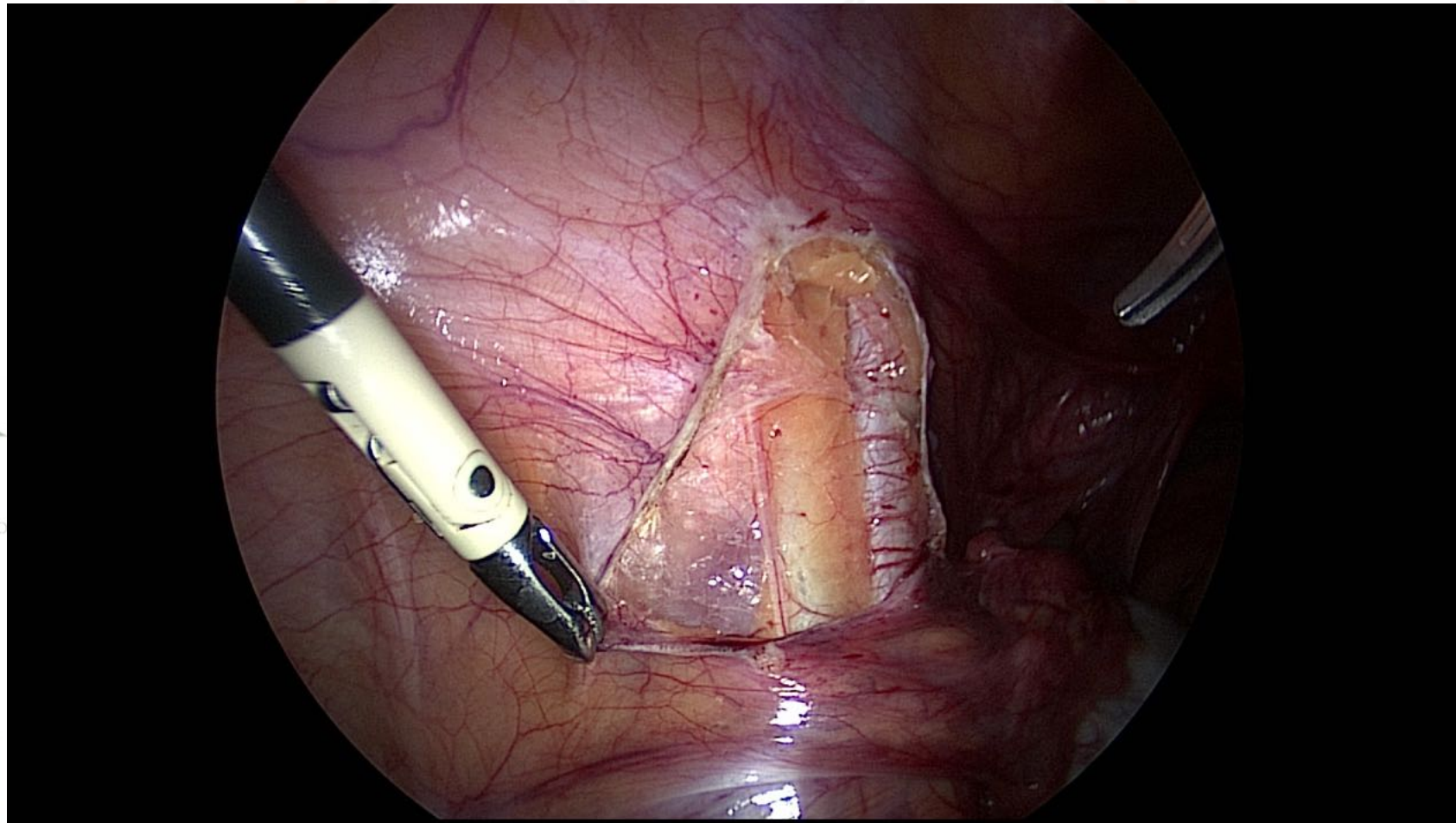


UNIVERSIDADE FEDERAL DE SÃO PAULO



increasing
INSTITUTO DE CUIDADOS, REABILITAÇÃO E ASSISTÊNCIA
EM NEUROPELVEOLOGIA E GINECOLOGIA

Somatic Nerves of the Pelvis





UNIVERSITY OF
TORONTO



WOMEN'S COLLEGE HOSPITAL
Health care for women | REVOLUTIONIZED



Mount Sinai
Hospital

Sinai Health System
Joseph & Wolf Lebovic
Health Complex

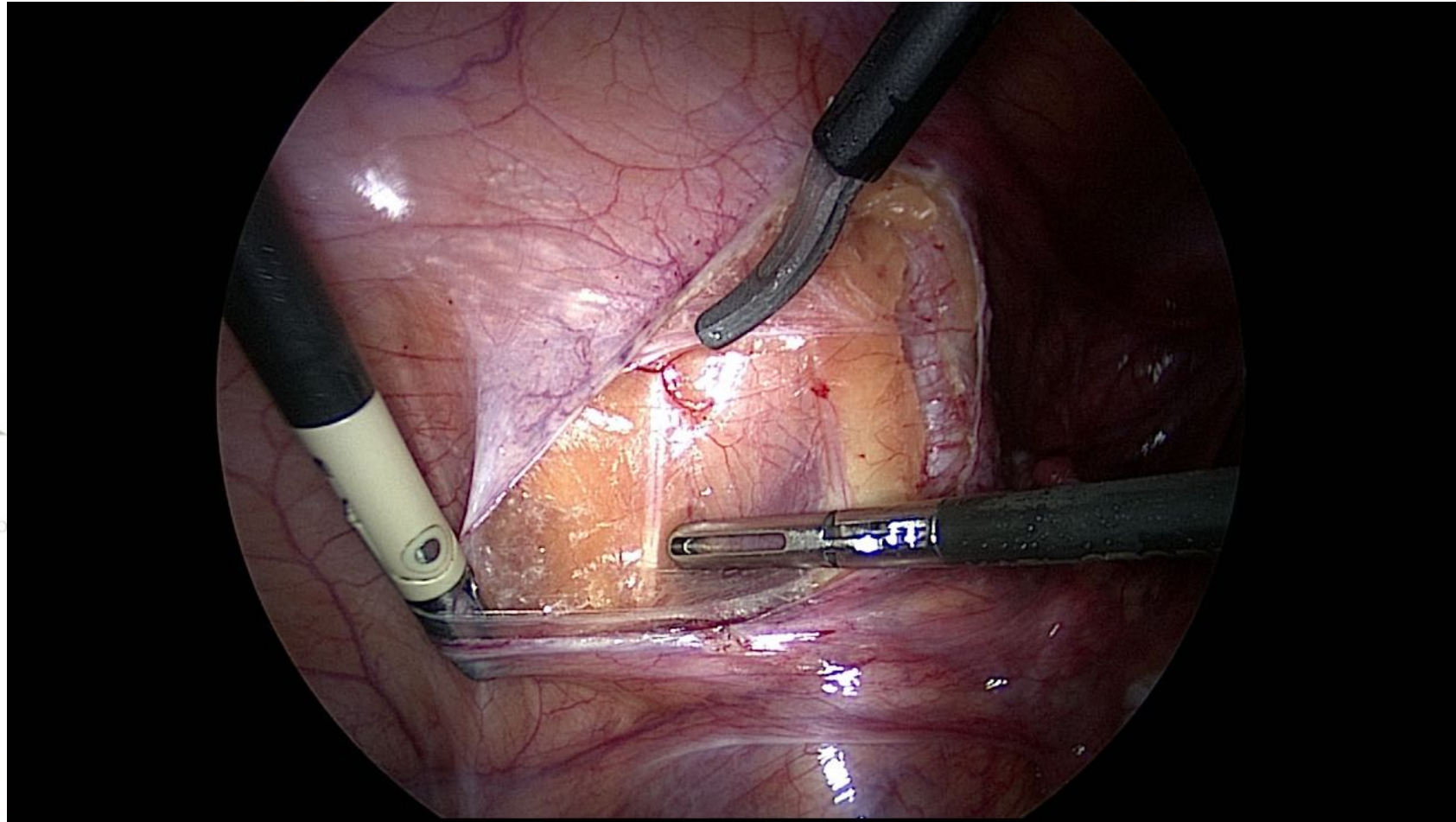


UNIVERSIDADE FEDERAL DE SÃO PAULO



increasing
INSTITUTO DE CUIDADOS, REABILITAÇÃO E ASSISTÊNCIA
EM NEUROPELVEOLOGIA E GINECOLOGIA

Somatic Nerves of the Pelvis





UNIVERSITY OF
TORONTO



WOMEN'S COLLEGE HOSPITAL
Health care for women | REVOLUTIONIZED



Mount Sinai
Hospital

Sinai Health System
Joseph & Wolf Lebovic
Health Complex



PAULISTA
UNIFESP

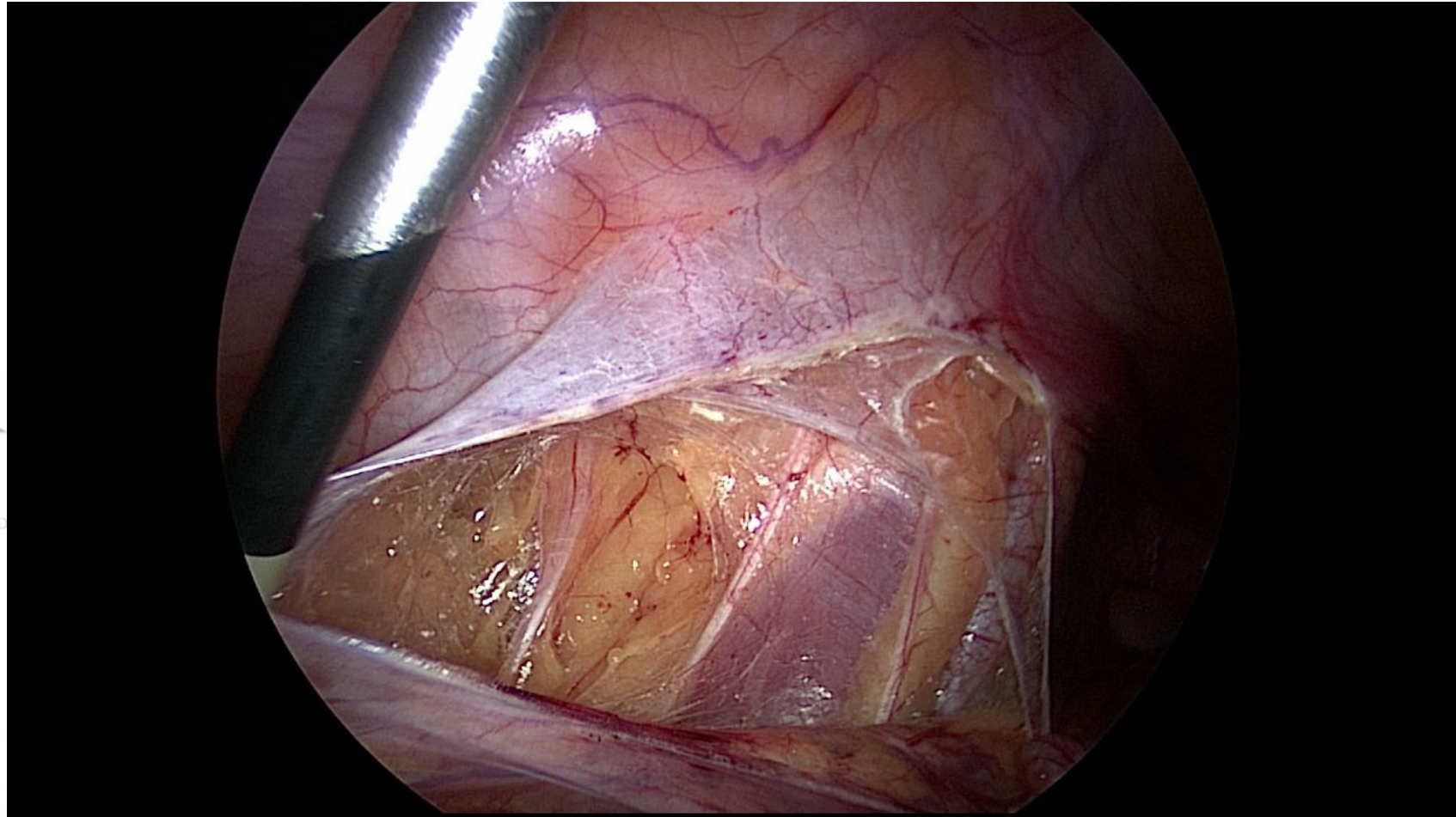


UNIVERSIDADE FEDERAL DE SÃO PAULO



increasing
INSTITUTO DE CUIDADOS, REABILITAÇÃO E ASSISTÊNCIA
EM NEUROPELVEOLOGIA E GINECOLOGIA

Somatic Nerves of the Pelvis





UNIVERSITY OF
TORONTO



WOMEN'S COLLEGE HOSPITAL
Health care for women | REVOLUTIONIZED



Mount Sinai
Hospital

Sinai Health System
Joseph & Wolf Lebovic
Health Complex



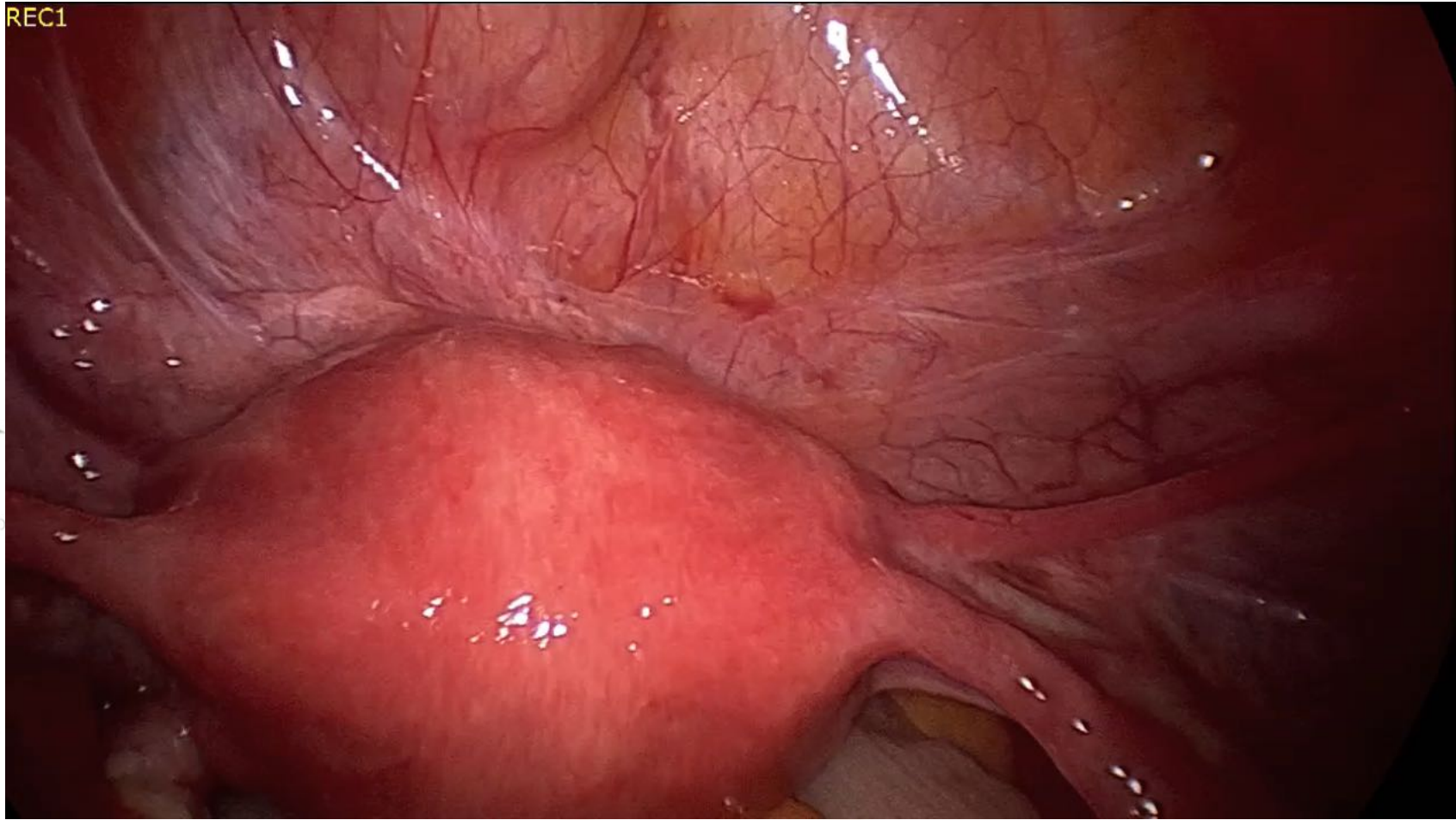
UNIVERSIDADE FEDERAL DE SÃO PAULO



increasing
INSTITUTO DE CUIDADOS, REABILITAÇÃO E ASSISTÊNCIA
EM NEUROPELVEOLOGIA E GINECOLOGIA

Somatic Nerves of the Pelvis

REC1





WOMEN'S COLLEGE HOSPITAL
Health care for women | REVOLUTIONIZED



Mount Sinai
Hospital

Sinai Health System
Joseph & Wolf Lebovic
Health Complex



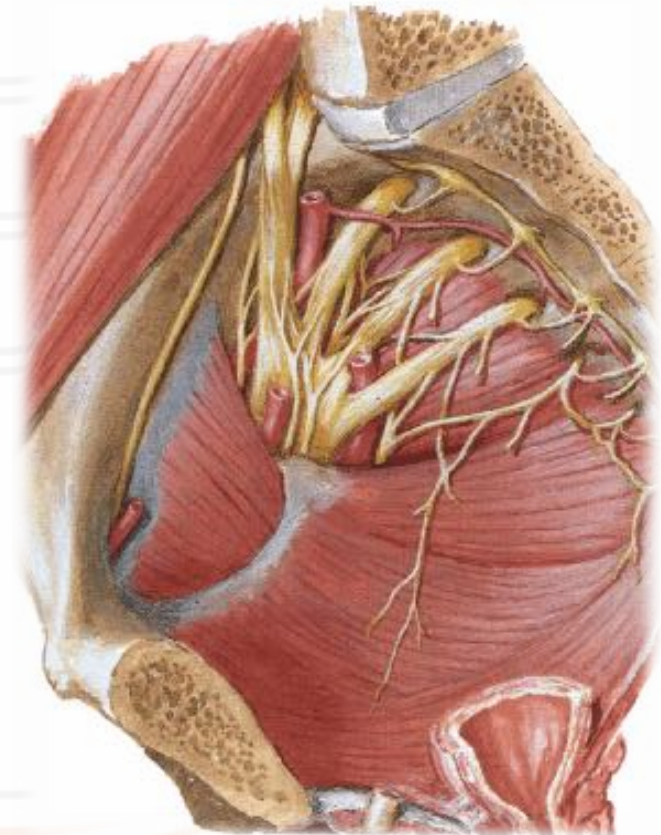
UNIVERSIDADE FEDERAL DE SÃO PAULO



increasing
INSTITUTO DE CUIDADOS, REABILITAÇÃO E ASSISTÊNCIA
EM NEUROPELVEOLOGIA E GINECOLOGIA

Sacral & Coccygeal Nerves

- Superior Gluteal N.
- Inferior Gluteal N.
- Post. Cutaneous Femoralis N.
- Sciatic N.
- Pudendal N.
- Nn. to the Levator Ani Mm.





WOMEN'S COLLEGE HOSPITAL
Health care for women | REVOLUTIONIZED

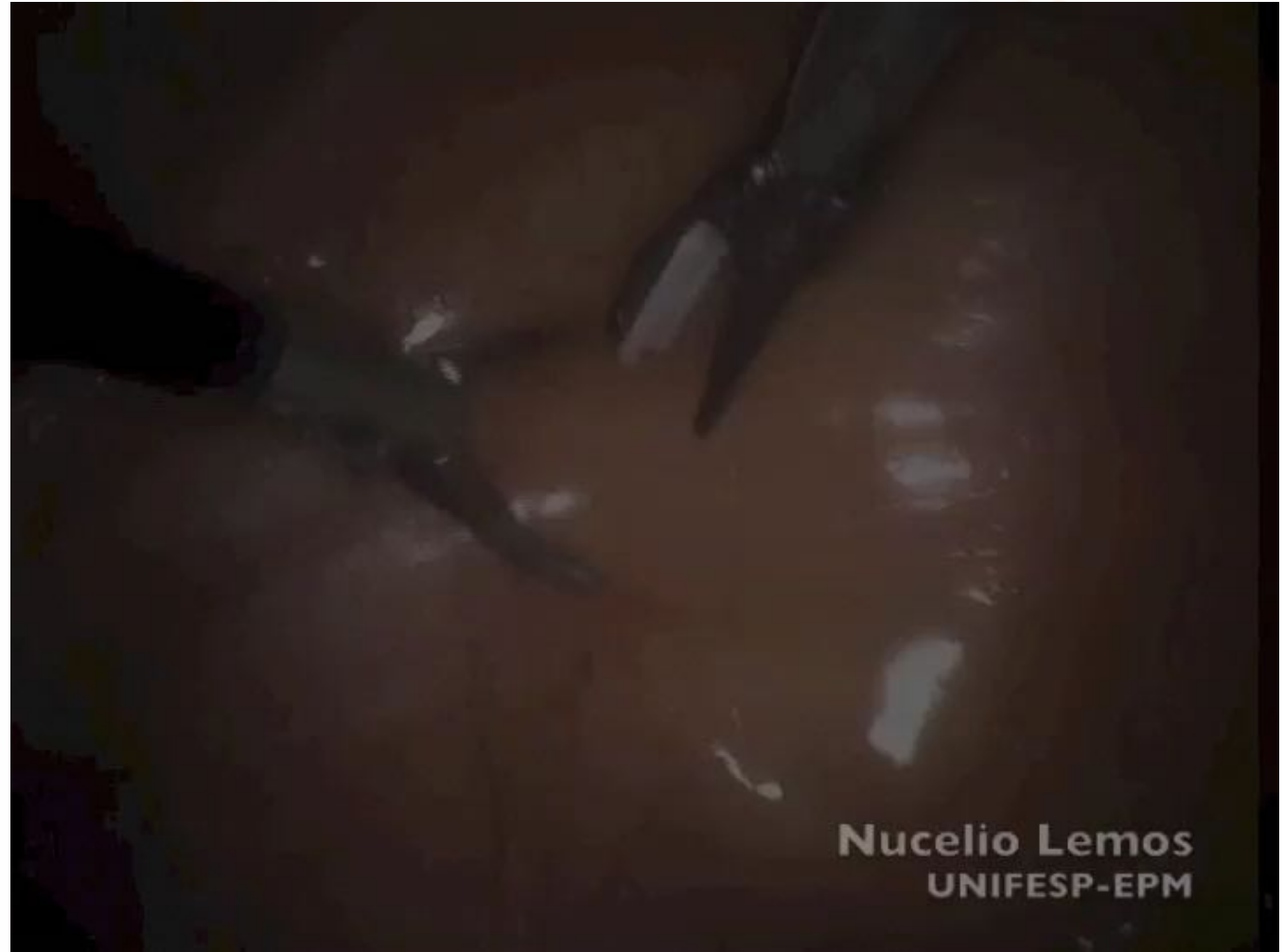

Sinai Health System
Joseph & Wolf Lebovic
Health Complex



increasing
INSTITUTO DE CUIDADOS, REABILITAÇÃO E ASSISTÊNCIA
EM NEUROPELVEOLOGIA E GINECOLOGIA

Somatic Nerves of the Pelvis





UNIVERSITY OF TORONTO



WOMEN'S COLLEGE HOSPITAL
Health care for women | REVOLUTIONIZED



Mount Sinai Hospital

Sinai Health System
Joseph & Wolf Lebovic Health Complex

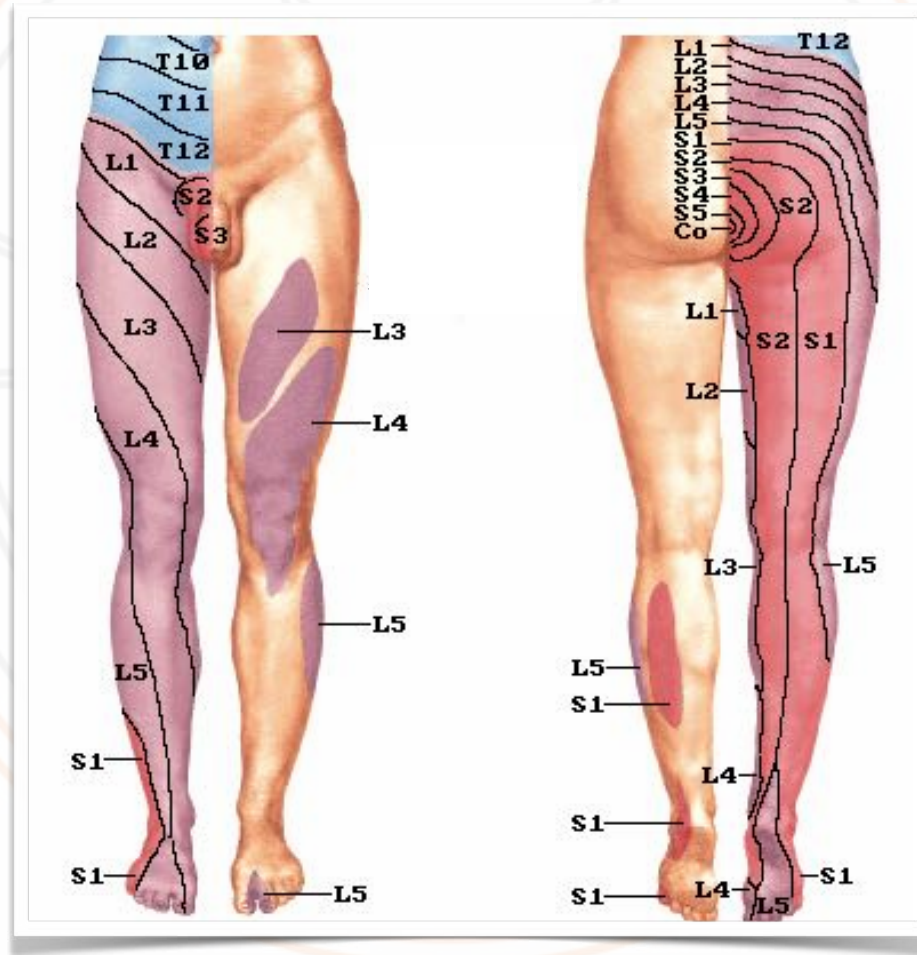


UNIVERSIDADE FEDERAL DE SÃO PAULO



increasing
INSTITUTO DE CUIDADOS, REABILITAÇÃO E ASSISTÊNCIA
EM NEUROPELVEOLOGIA E GINECOLOGIA

Sensitive Innervation





WOMEN'S COLLEGE HOSPITAL
Health care for women | REVOLUTIONIZED



increasing
INSTITUTO DE CUIDADOS, REABILITAÇÃO E ASSISTÊNCIA
EM NEUROPELVEOLOGIA E GINECOLOGIA

Motoric Innervation

- L2/L3 - Hip flexors (ilipsoas)
- L3 - Hip adductors
- L3/L4 - Knee extensors (Quadriceps)
- L5 - ankle dorsiflexion, eversion and inversion + hip abductors
- S1 - ankle plantar flexion + hip extensors
- S2-S4 - External anal and urethral sphincters



UNIVERSITY OF TORONTO



WOMEN'S COLLEGE HOSPITAL
Health care for women | REVOLUTIONIZED



Mount Sinai Hospital

Sinai Health System
Joseph & Wolf Lebovic Health Complex



UNIFESP



UNIVERSIDADE FEDERAL DE SÃO PAULO



increasing
INSTITUTO DE CUIDADOS, REABILITAÇÃO E ASSISTÊNCIA
EM NEUROPELVEOLOGIA E GINECOLOGIA

Autonomic Nerves

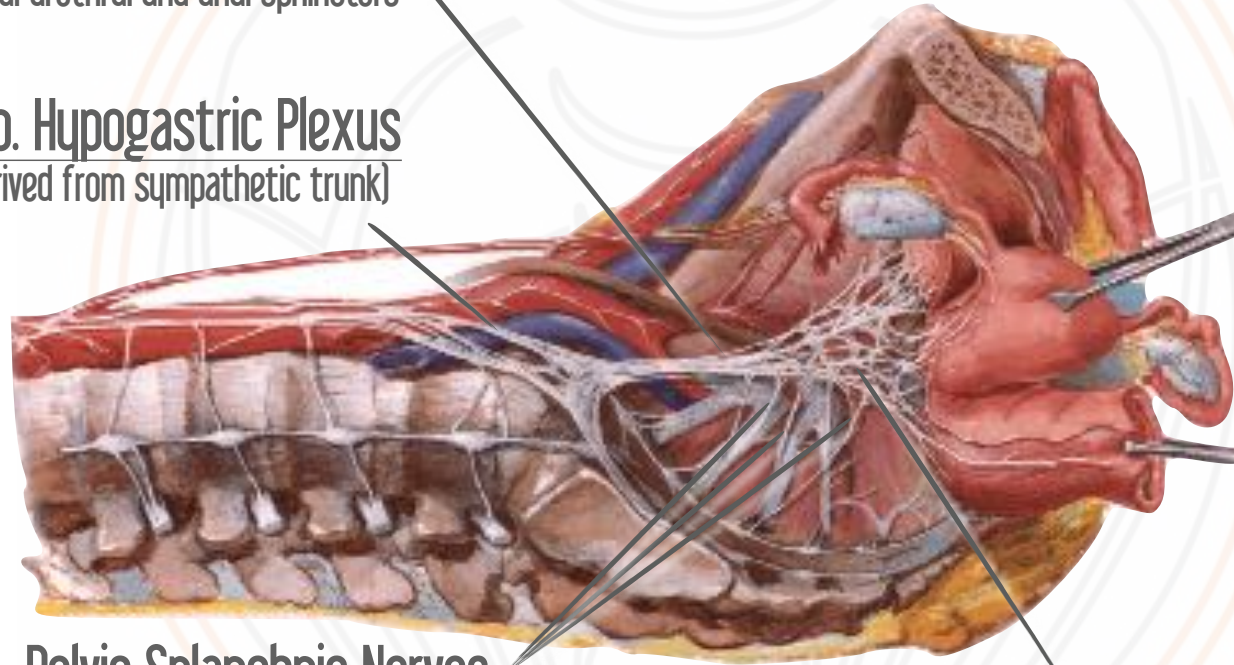
Hypogastric Nerves

(sympathetic)

Proprioception (filling sensation)
Internal urethral and anal sphincters

Sup. Hypogastric Plexus

(derived from sympathetic trunk)



Pelvic Splanchnic Nerves

(nervi erigenti)

Detrusor contraction
Cólón descendens, sigmoid and rectum
Nociception

Inf. Hypogastric Plexus

Image from Netter



WOMEN'S COLLEGE HOSPITAL
Health care for women | REVOLUTIONIZED

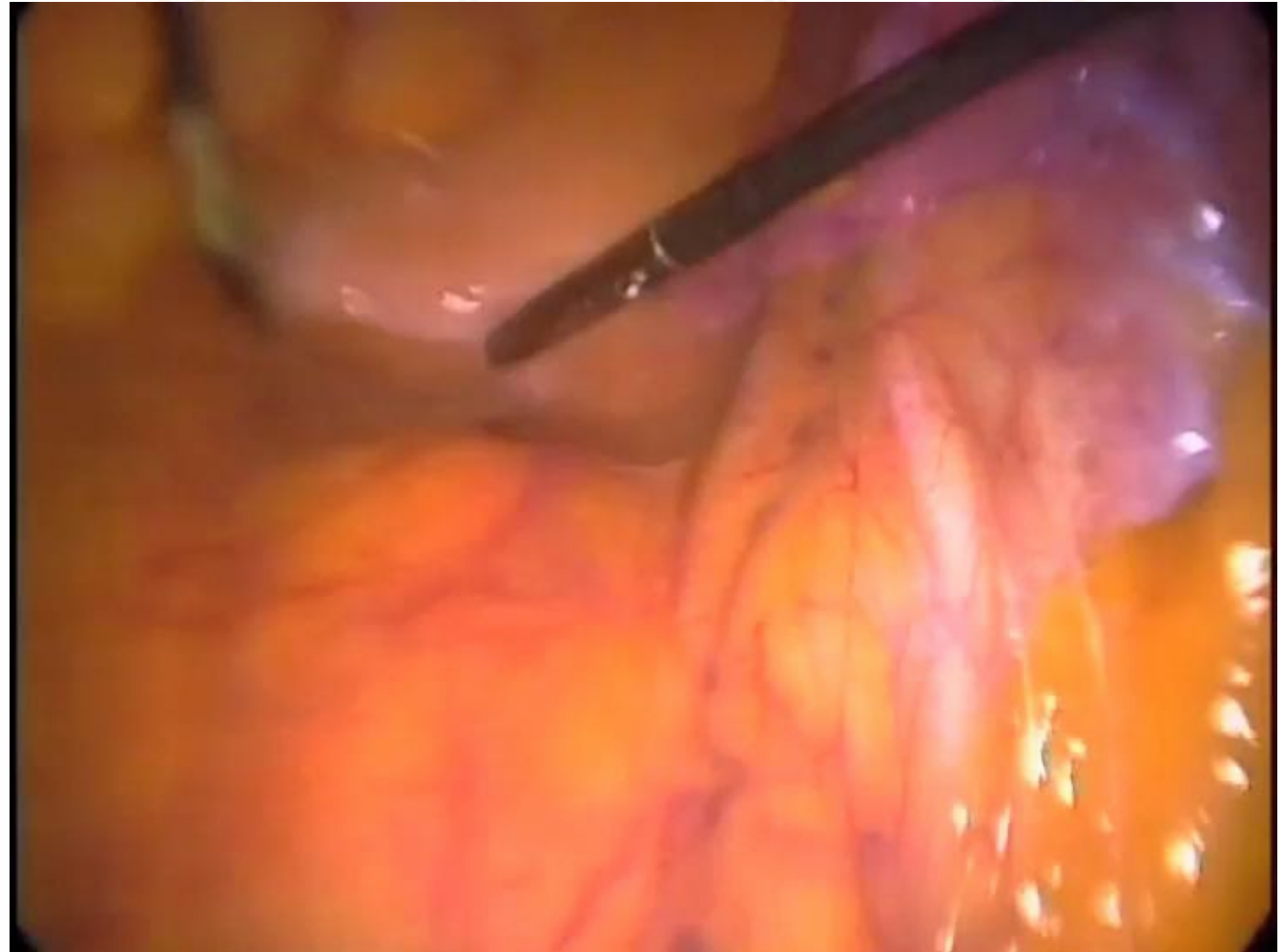

Sinai Health System
Joseph & Wolf Lebovic
Health Complex



increasing
INSTITUTO DE CUIDADOS, REABILITAÇÃO E ASSISTÊNCIA
EM NEUROPELVEOLOGIA E GINECOLOGIA

Hypogastric Nerve





UNIVERSITY OF TORONTO



WOMEN'S COLLEGE HOSPITAL
Health care for women | REVOLUTIONIZED



Mount Sinai Hospital

Sinai Health System
Joseph & Wolf Lebovic Health Complex



UNIFESP



UNIVERSIDADE FEDERAL DE SÃO PAULO



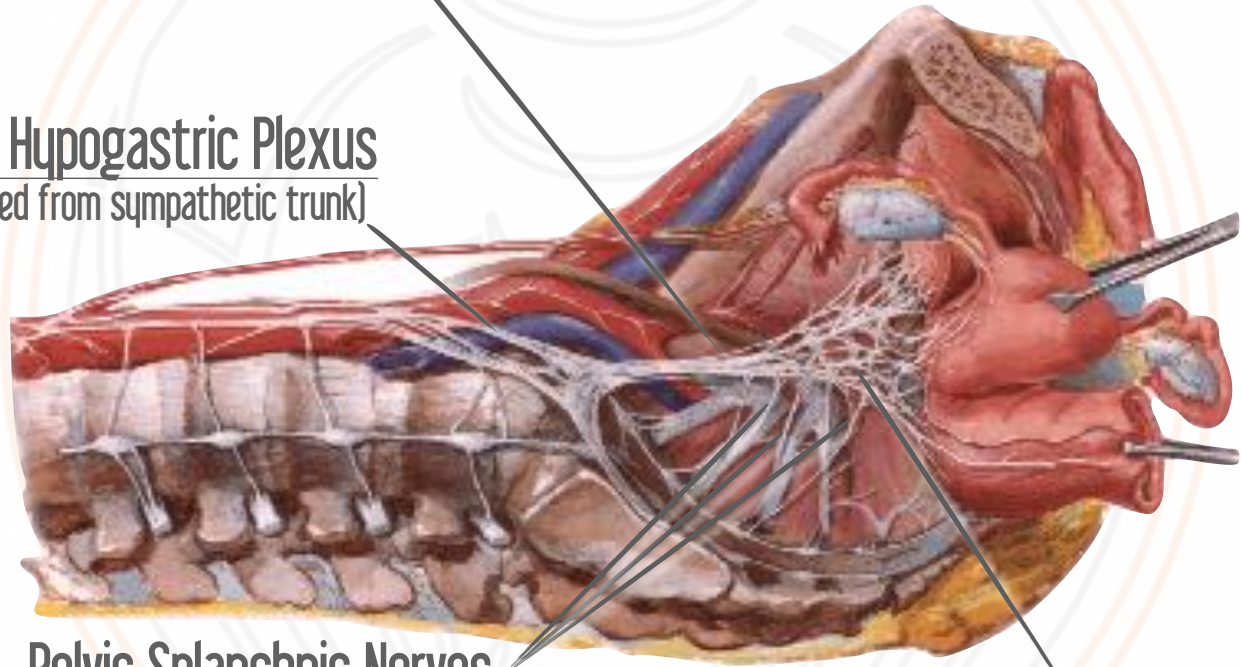
increasing
INSTITUTO DE CUIDADOS, REABILITAÇÃO E ASSISTÊNCIA
EM NEUROPELVEOLOGIA E GINECOLOGIA

Autonomic Nerves

Hypogastric Nerves
(sympathetic)

Proprioception (filling sensation)
Internal urethral and anal sphincters

Sup. Hypogastric Plexus
(derived from sympathetic trunk)



Pelvic Splanchnic Nerves
(nervi erigenti)

Detrusor contraction
Cólon descendens, sigmoid and rectum
Nociception

Inf. Hypogastric Plexus

Image from Netter



WOMEN'S COLLEGE HOSPITAL
Health care for women | REVOLUTIONIZED



Sinai Health System
Joseph & Wolf Lebovic
Health Complex

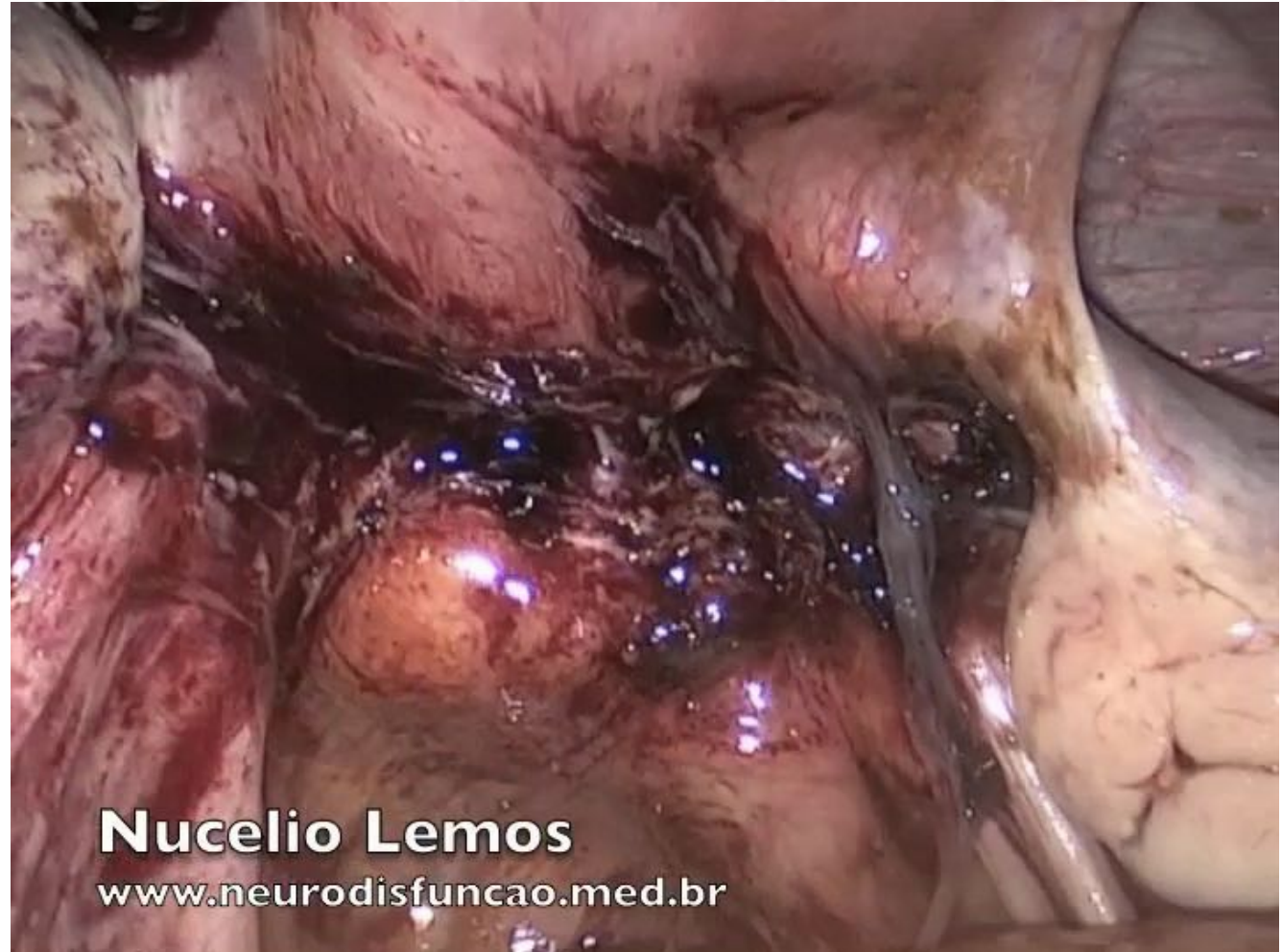

UNIVERSIDADE FEDERAL DE SÃO PAULO



increasing
INSTITUTO DE CUIDADOS, REABILITAÇÃO E ASSISTÊNCIA
EM NEUROPELVEOLOGIA E GINECOLOGIA

The Sacral Nerve Roots



Nucelio Lemos

www.neurodisfuncao.med.br



WCHI

WOMEN'S COLLEGE HOSPITAL
Health care for women | REVOLUTIONIZED



**Mount Sinai
Hospital**

Sinai Health System
Joseph & Wolf Lebovic
Health Complex



increasing
INSTITUTO DE CUIDADOS, REABILITAÇÃO E ASSISTÊNCIA
EM NEUROPELVEOLOGIA E GINECOLOGIA

Intrapelvic Neuropathies





WOMEN'S COLLEGE HOSPITAL
Health care for women | REVOLUTIONIZED



Sinai Health System
Joseph & Wolf Lebovic
Health Complex



increasing
INSTITUTO DE CUIDADOS, REABILITAÇÃO E ASSISTÊNCIA
EM NEUROPELVEOLOGIA E GINECOLOGIA

Syndromic Diagnosis

Peripheral entrapment neuropathy, is a clinical condition characterized by the mechanical entrapment on a single nerve or nerve root. Its symptoms include pain, tingling, numbness, and muscle weakness on the affected nerve's dermatome.



UNIVERSITY OF TORONTO



WOMEN'S COLLEGE HOSPITAL
Health care for women | REVOLUTIONIZED



Mount Sinai Hospital

Sinai Health System
Joseph & Wolf Lebovic Health Complex



PAULISTA ESCOLA DE MEDICINA 1938

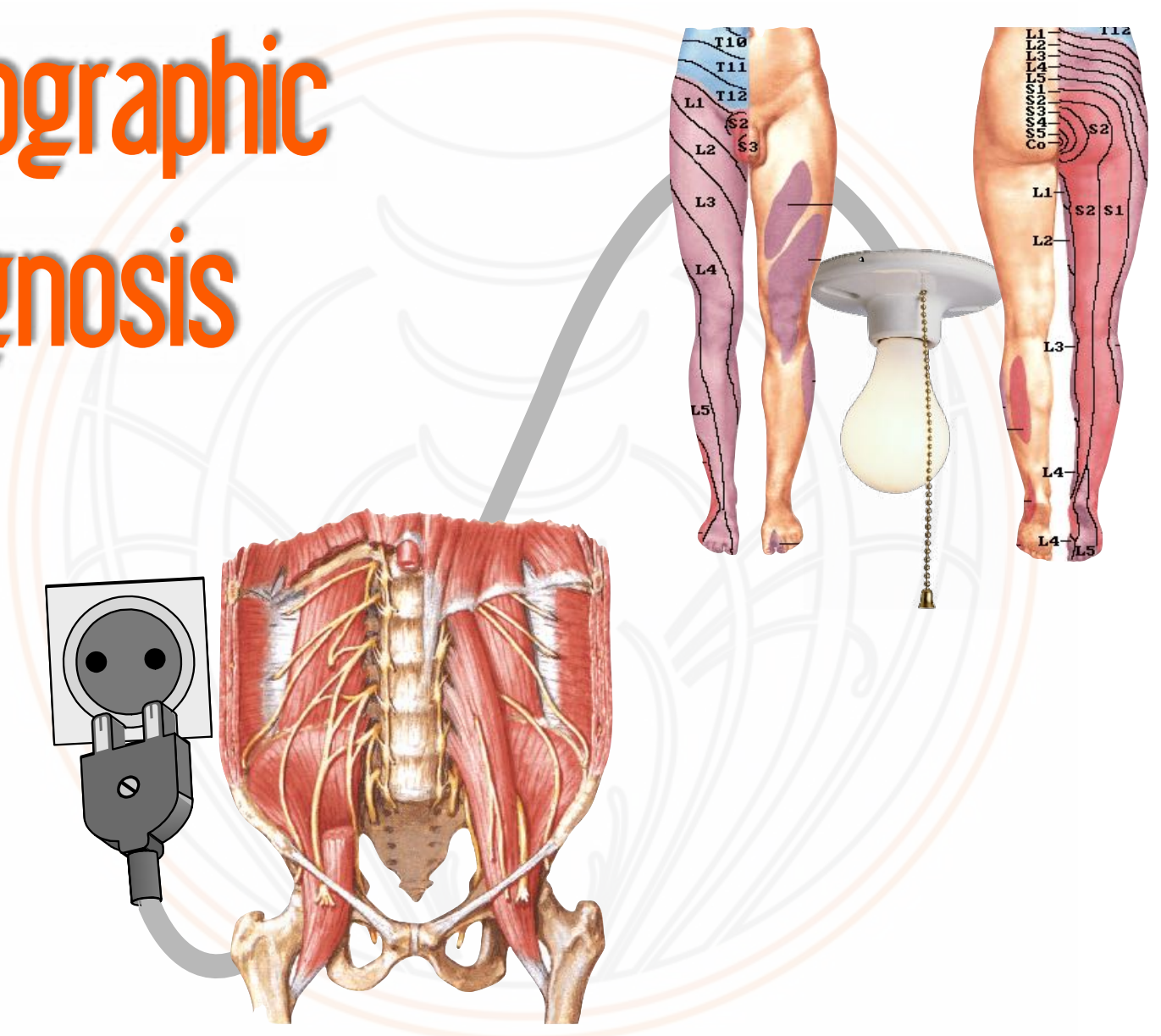


UNIFESP
UNIVERSIDADE FEDERAL DE SÃO PAULO



increasing
INSTITUTO DE CUIDADOS, REABILITAÇÃO E ASSISTÊNCIA
EM NEUROPELVEOLOGIA E GINECOLOGIA

Topographic Diagnosis





UNIVERSITY OF
TORONTO



WOMEN'S COLLEGE HOSPITAL
Health care for women | REVOLUTIONIZED



Mount Sinai
Hospital

Sinai Health System
Joseph & Wolf Lebovic
Health Complex



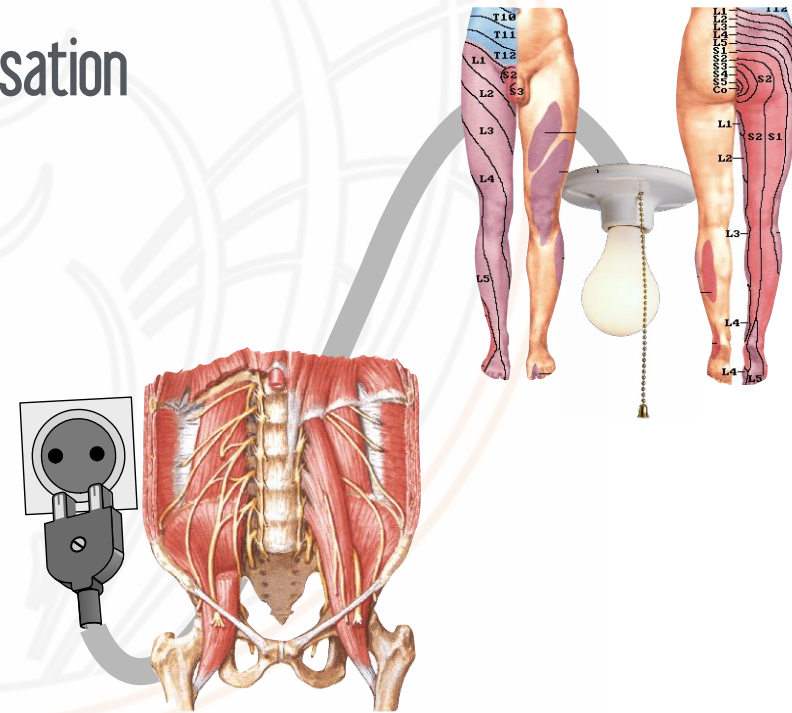
UNIVERSIDADE FEDERAL DE SÃO PAULO



increasing
INSTITUTO DE CUIDADOS, REABILITAÇÃO E ASSISTÊNCIA
EM NEUROPELVEOLOGIA E GINECOLOGIA

Symptoms

- Gluteal/Perineal/Lower Limb Pain/Alodynia
- Vaginal/Retal Foreign Body Sensation
- Refractory Urinary Urgency
- Dischezia
- Proctalgia
- Vesical/Retal Tenesmus



Lemos N, Possover M. Laparoscopic approach to intrapelvic nerve entrapments. Journal of Hip Preservation Surgery. , 2015.



UNIVERSITY OF TORONTO



WOMEN'S COLLEGE HOSPITAL
Health care for women | REVOLUTIONIZED



Mount Sinai Hospital

Sinai Health System
Joseph & Wolf Lebovic Health Complex

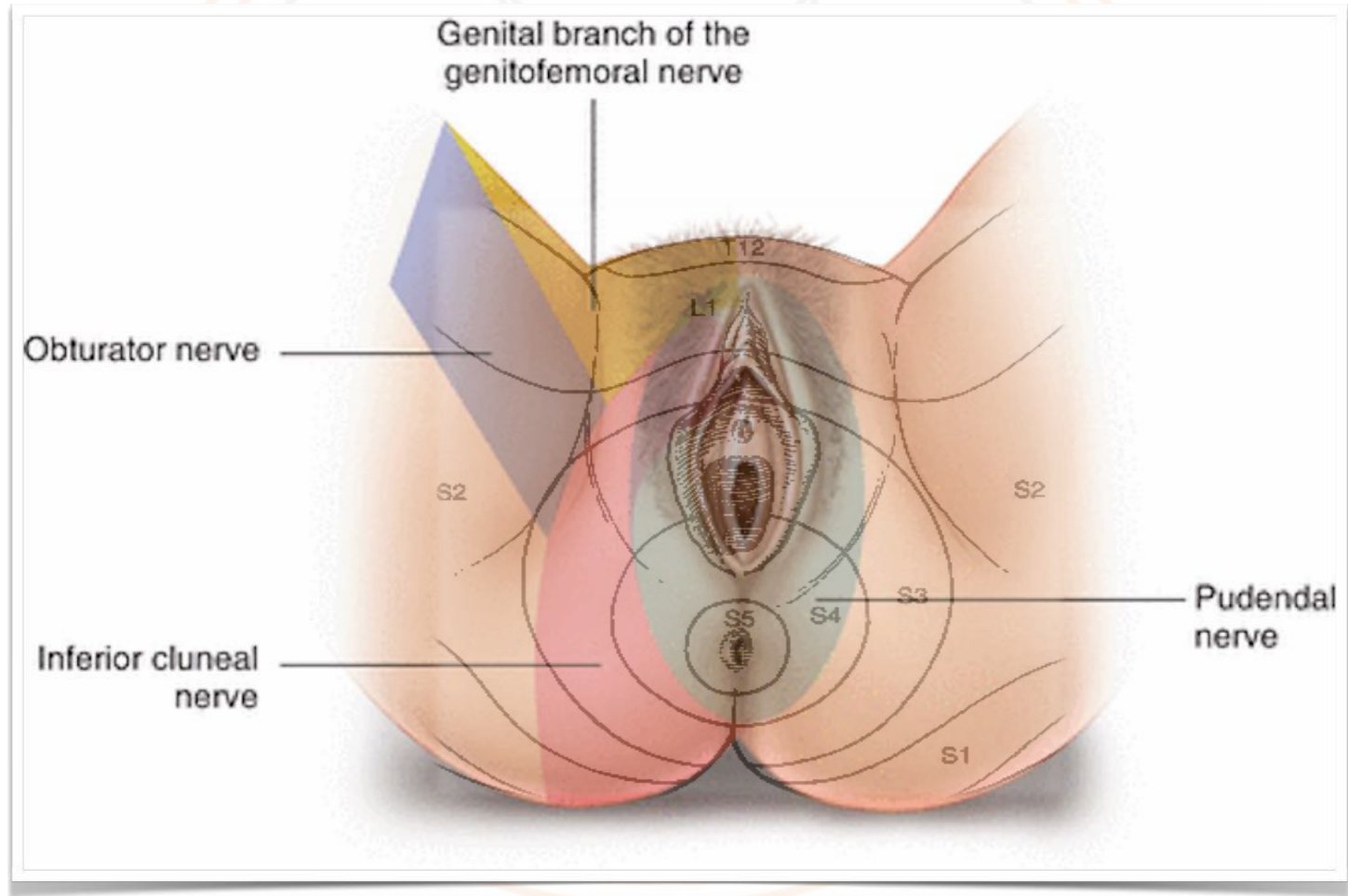


UNIVERSIDADE FEDERAL DE SÃO PAULO



increasing
INSTITUTO DE CUIDADOS, REABILITAÇÃO E ASSISTÊNCIA
EM NEUROPELVEOLOGIA E GINECOLOGIA

Signs





UNIVERSITY OF TORONTO



WOMEN'S COLLEGE HOSPITAL
Health care for women | REVOLUTIONIZED



Mount Sinai Hospital

Sinai Health System
Joseph & Wolf Lebovic Health Complex



UNIFESP

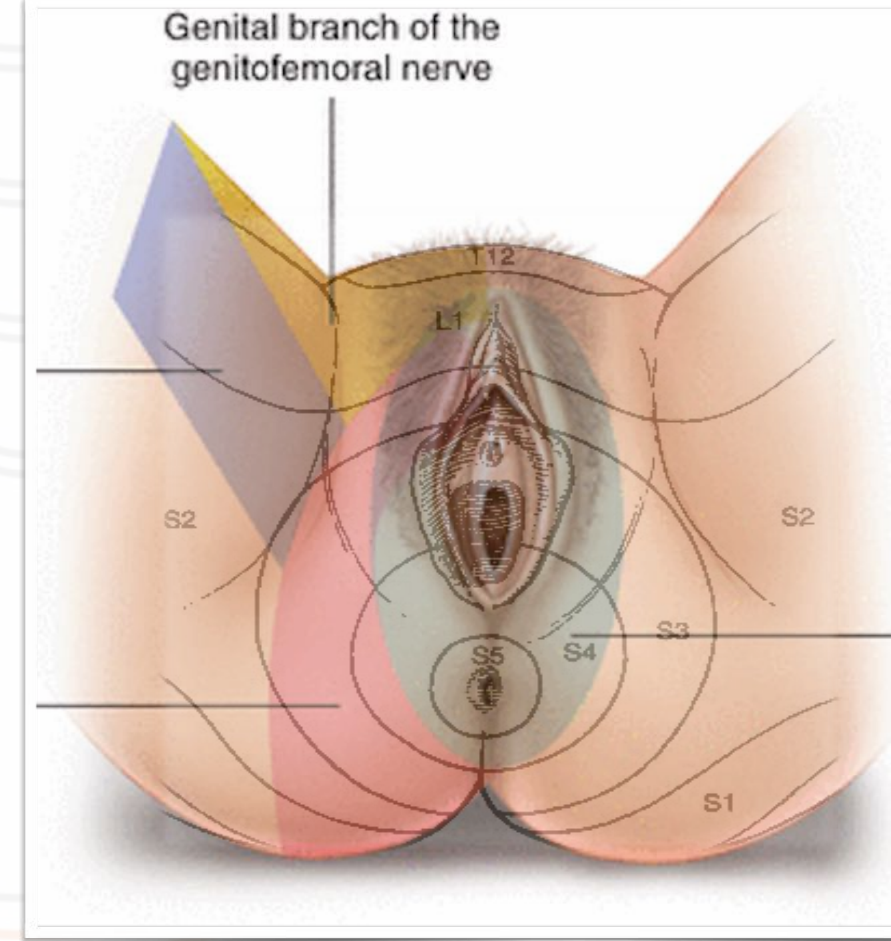
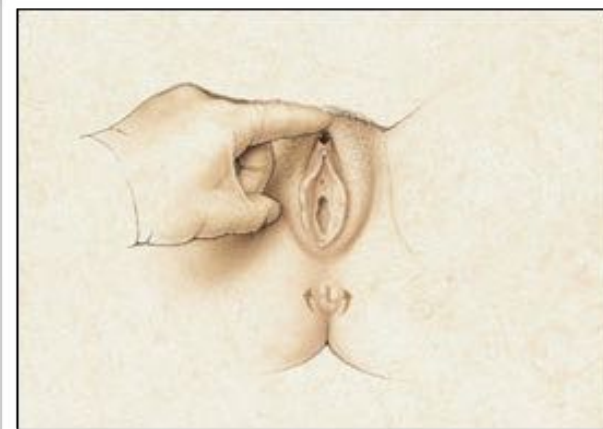
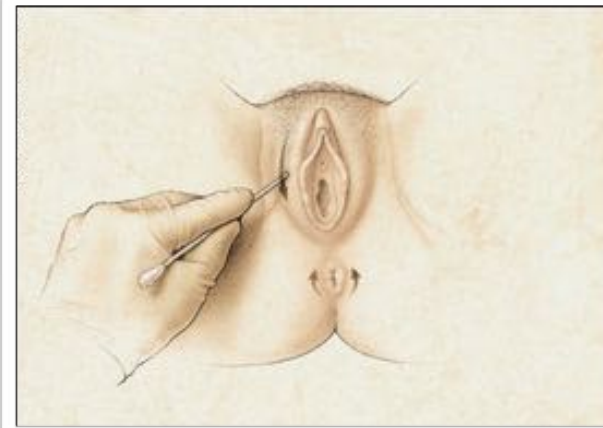


UNIVERSIDADE FEDERAL DE SÃO PAULO



increasing
INSTITUTO DE CUIDADOS, REABILITAÇÃO E ASSISTÊNCIA
EM NEUROPELVEOLOGIA E GINECOLOGIA

Signs





UNIVERSITY OF TORONTO



WOMEN'S COLLEGE HOSPITAL
Health care for women | REVOLUTIONIZED



Mount Sinai Hospital

Sinai Health System
Joseph & Wolf Lebovic Health Complex

UNIFESP

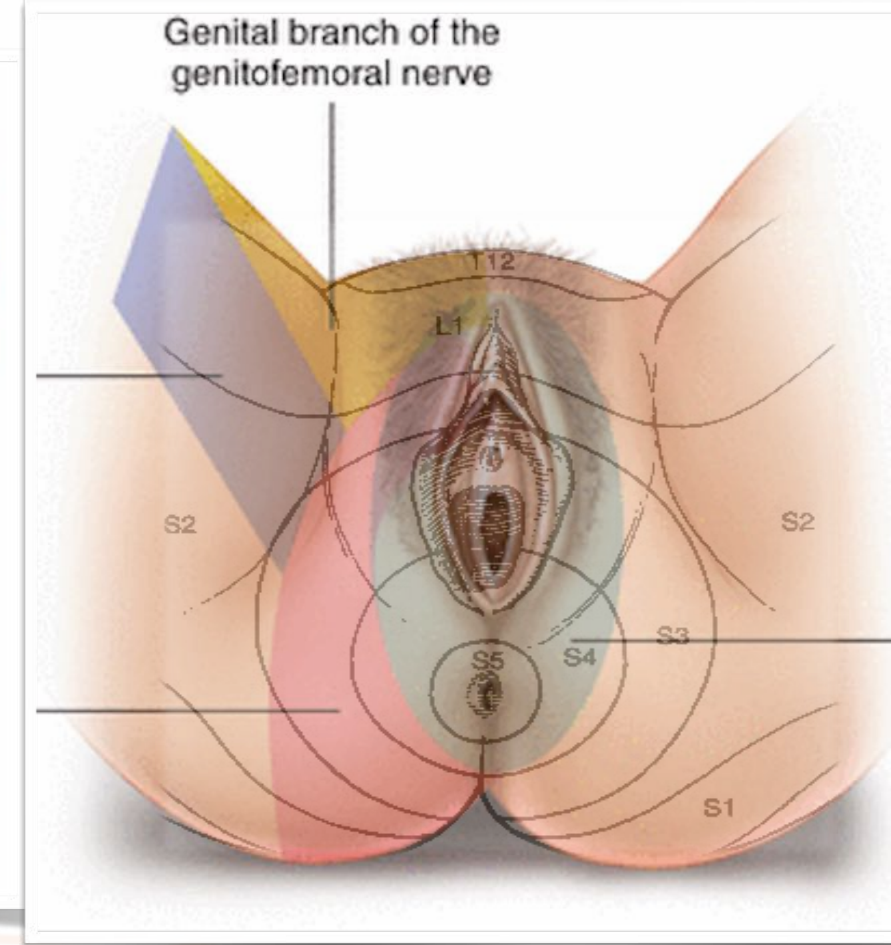
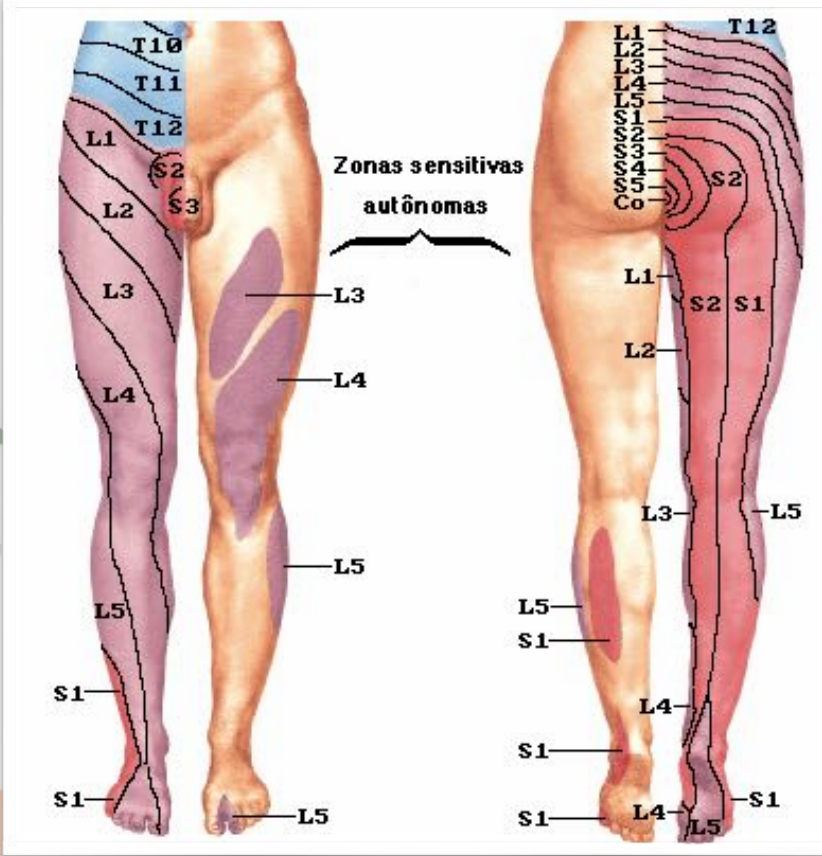


UNIVERSIDADE FEDERAL DE SÃO PAULO



increasing
INSTITUTO DE CUIDADOS, REABILITAÇÃO E ASSISTÊNCIA
EM NEUROPELVEOLOGIA E GINECOLOGIA

Signs





UNIVERSITY OF TORONTO



WOMEN'S COLLEGE HOSPITAL
Health care for women | REVOLUTIONIZED



Mount Sinai Hospital

Sinai Health System
Joseph & Wolf Lebovic Health Complex

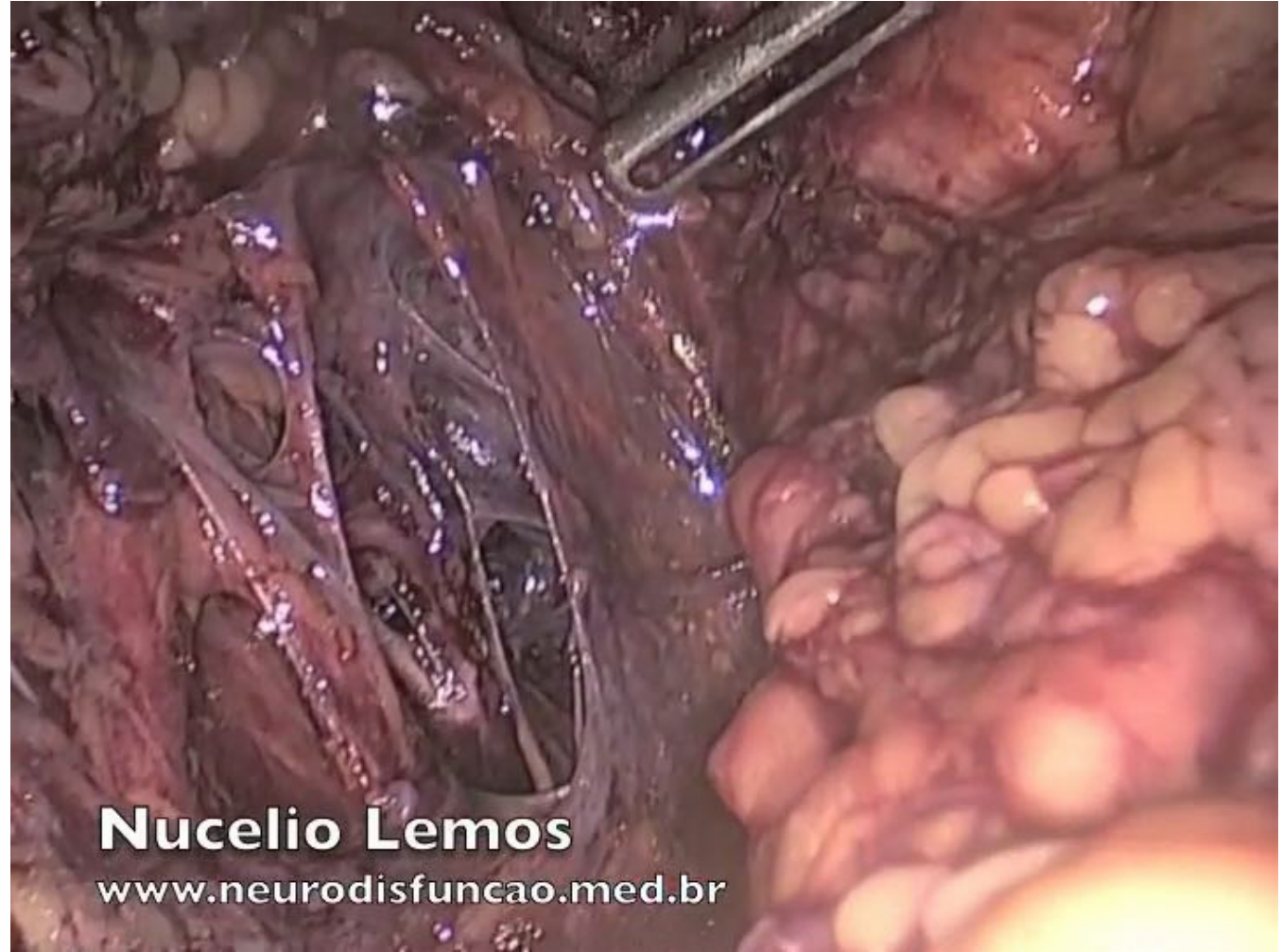

UNIVERSIDADE FEDERAL DE SÃO PAULO



increasing
INSTITUTO DE CUIDADOS, REABILITAÇÃO E ASSISTÊNCIA
EM NEUROPELVEOLOGIA E GINECOLOGIA

Urodynamic Study



Nucelio Lemos

www.neurodisfuncao.med.br

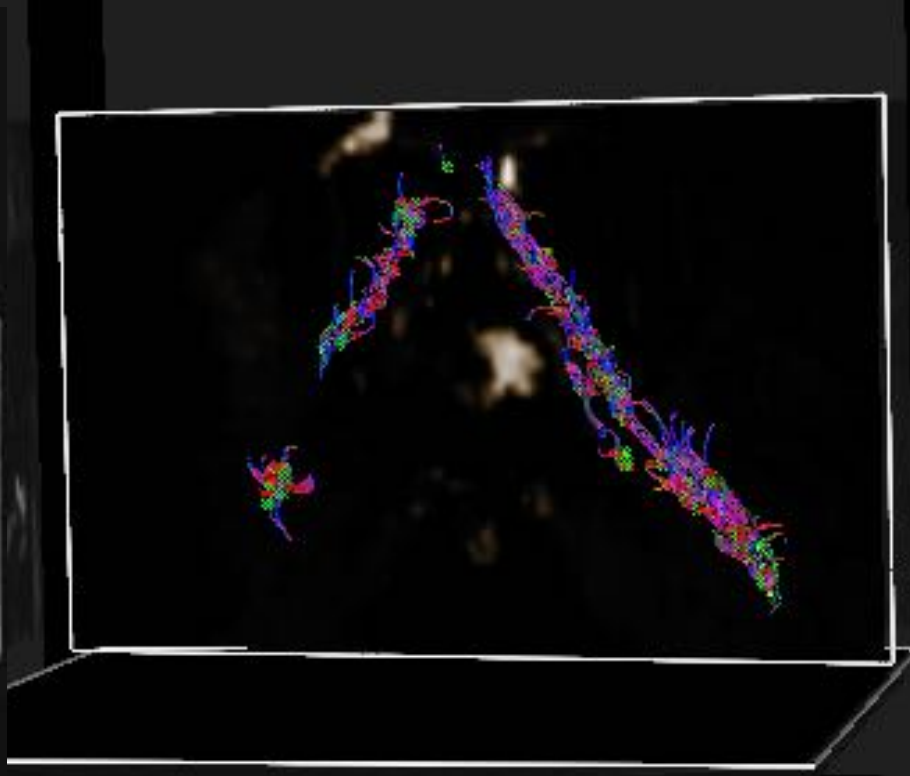
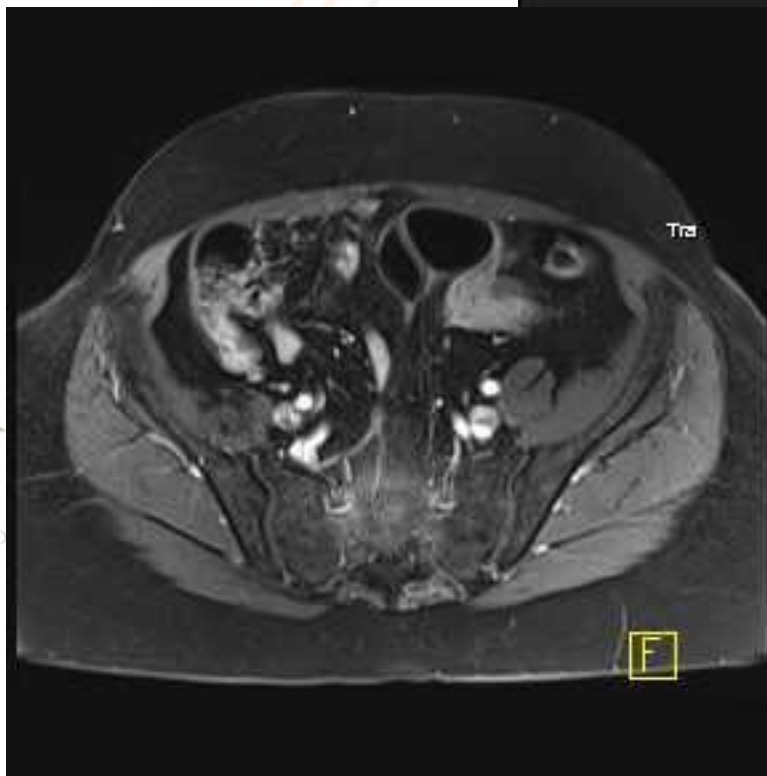

WOMEN'S COLLEGE HOSPITAL
Health care for women | REVOLUTIONIZED



increasing
INSTITUTO DE CUIDADOS, REABILITAÇÃO E ASSISTÊNCIA
EM NEUROPELVEOLOGIA E GINECOLOGIA

Functional MRI (Tractography)



S.Goldman & N. Lemos



WOMEN'S COLLEGE HOSPITAL
Health care for women | REVOLUTIONIZED



Mount Sinai
Hospital

Sinai Health System
Joseph & Wolf Lebovic
Health Complex

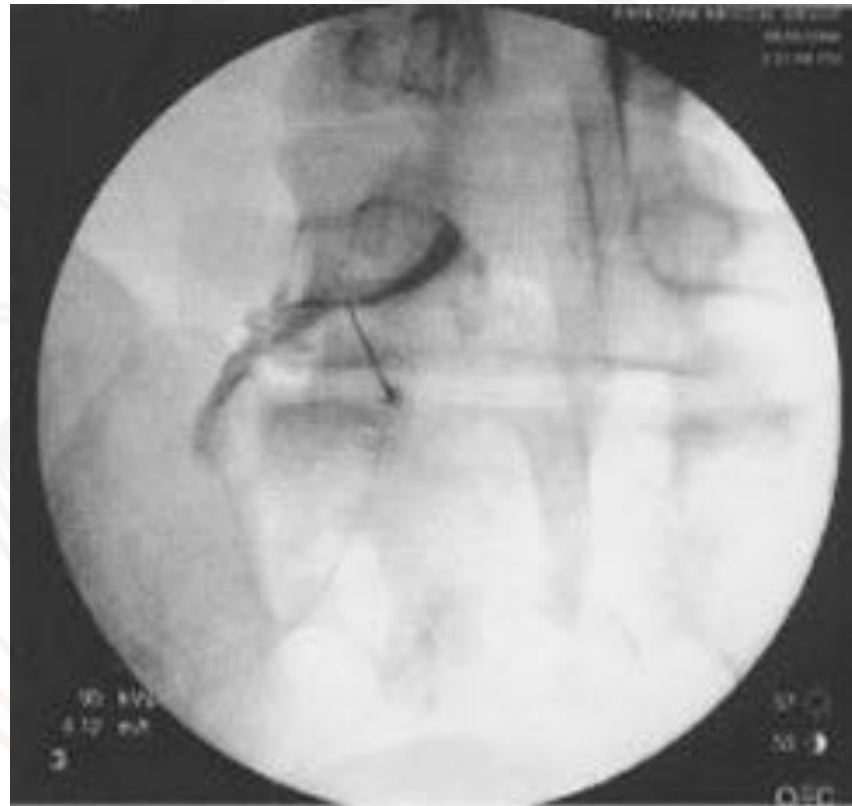

UNIVERSIDADE FEDERAL DE SÃO PAULO



increasing
INSTITUTO DE CUIDADOS, REABILITAÇÃO E ASSISTÊNCIA
EM NEUROPELVEOLOGIA E GINECOLOGIA

Selective Diagnostic Blocks



A. Raffaini & N. Lemos

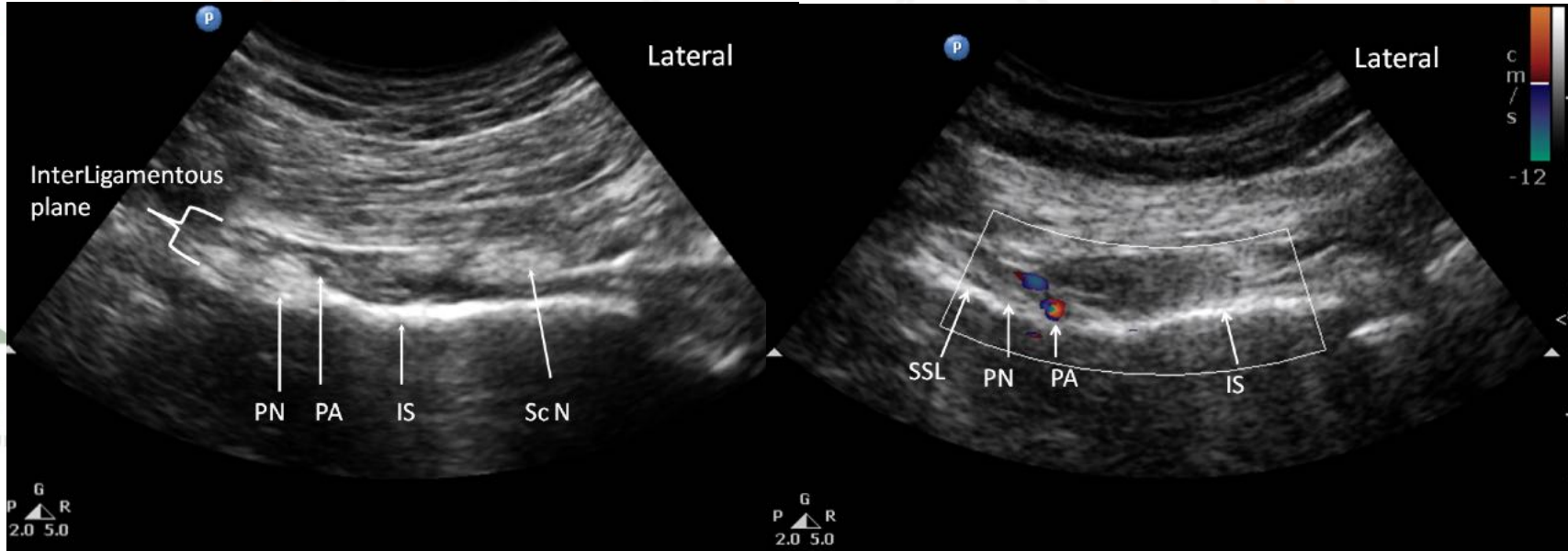


WOMEN'S COLLEGE HOSPITAL
Health care for women | REVOLUTIONIZED



INSTITUTO DE CUIDADOS, REABILITAÇÃO E ASSISTÊNCIA
EM NEUROPELVEOLOGIA E GINECOLOGIA

Selective





UNIVERSITY OF TORONTO



WOMEN'S COLLEGE HOSPITAL
Health care for women | REVOLUTIONIZED



Mount Sinai Hospital

Sinai Health System
Joseph & Wolf Lebovic Health Complex



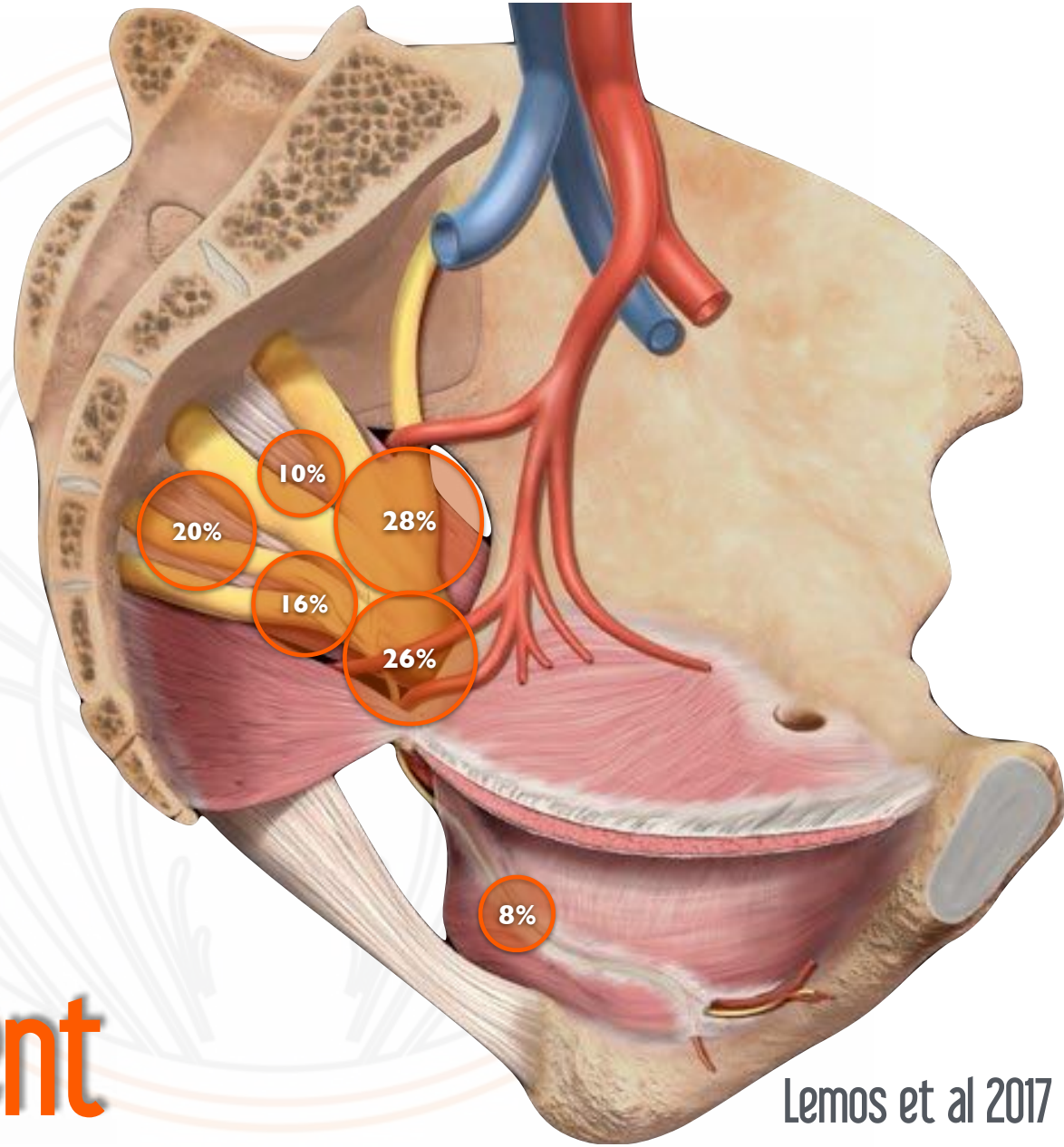
UNIVERSIDADE FEDERAL DE SÃO PAULO



increasing

INSTITUTO DE CUIDADOS, REABILITAÇÃO E ASSISTÊNCIA EM NEUROPELVEOLOGIA E GINECOLOGIA

Sites of Entrapment



Lemos et al 2017



WOMEN'S COLLEGE HOSPITAL
Health care for women | REVOLUTIONIZED



Etiological Diagnosis



UNIVERSITY OF
TORONTO



WOMEN'S COLLEGE HOSPITAL
Health care for women | REVOLUTIONIZED



Mount Sinai
Hospital

Sinai Health System
Joseph & Wolf Lebovic
Health Complex

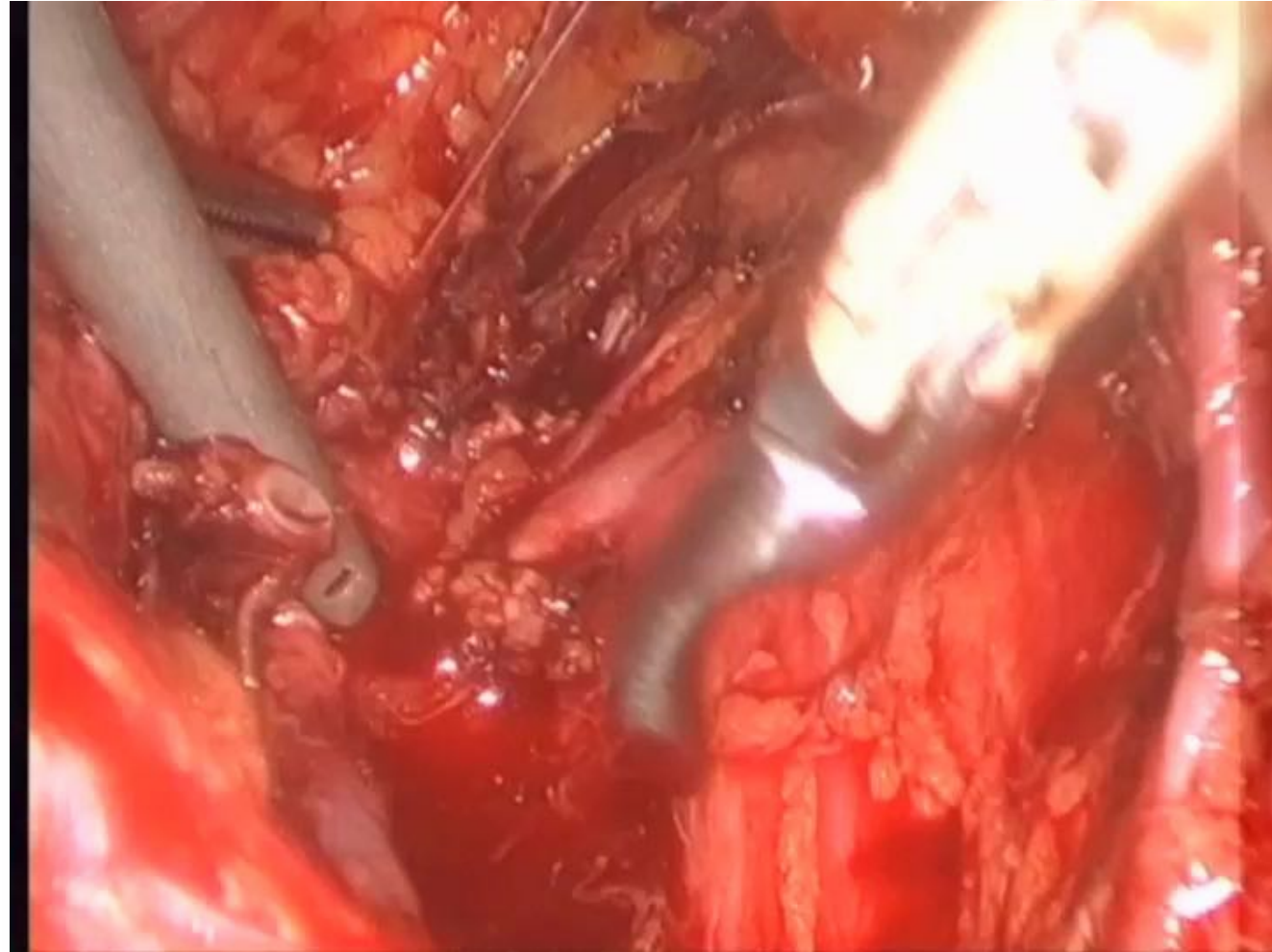


UNIVERSIDADE FEDERAL DE SÃO PAULO



increasing
INSTITUTO DE CUIDADOS, REABILITAÇÃO E ASSISTÊNCIA
EM NEUROPELVEOLOGIA E GINECOLOGIA

Endometriosis



Lemos N, et al. Recognition and treatment of endometriosis involving the sacral nerve roots. Int Urogynecol J. 2016



WOMEN'S COLLEGE HOSPITAL
Health care for women | REVOLUTIONIZED



Sinai Health System
Joseph & Wolf Lebovic
Health Complex



INSTITUTO DE CUIDADOS, REABILITAÇÃO E ASSISTÊNCIA
EM NEUROPELVEOLOGIA E GINECOLOGIA

Endometriosis

- Symptoms

- Cyclic Pain – continuous or perimenstrual
- Motoric Deficit \pm (Foot Drop)



WOMEN'S COLLEGE HOSPITAL
Health care for women | REVOLUTIONIZED



increasing
INSTITUTO DE CUIDADOS, REABILITAÇÃO E ASSISTÊNCIA
EM NEUROPELVEOLOGIA E GINECOLOGIA

Fibrosis

- Surgical manipulation
- Delivery
- Hematomas
- PID
- Sutures
- Grafts
- Anorectal Abscess



WOMEN'S COLLEGE HOSPITAL
Health care for women | REVOLUTIONIZED



Mount Sinai
Hospital

Sinai Health System
Joseph & Wolf Lebovic
Health Complex

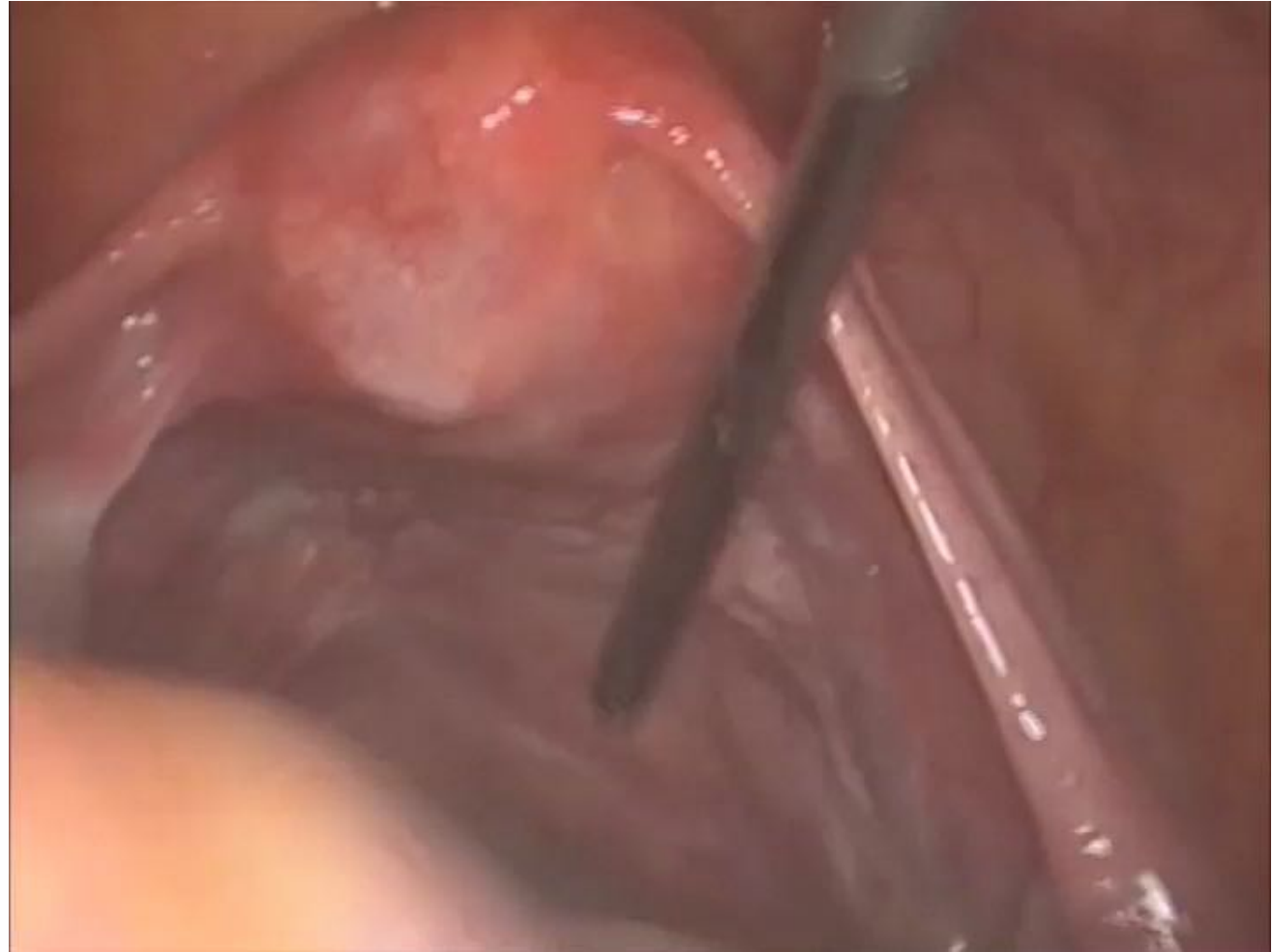

UNIVERSIDADE FEDERAL DE SÃO PAULO



increasing
INSTITUTO DE CUIDADOS, REABILITAÇÃO E ASSISTÊNCIA
EM NEUROPELVEOLOGIA E GINECOLOGIA

Fibrosis



Lemos N, et al. Recognition and treatment of endometriosis involving the sacral nerve roots. Int Urogynecol J. 2016



UNIVERSITY OF TORONTO



WOMEN'S COLLEGE HOSPITAL
Health care for women | REVOLUTIONIZED



Mount Sinai Hospital

Sinai Health System
Joseph & Wolf Lebovic Health Complex

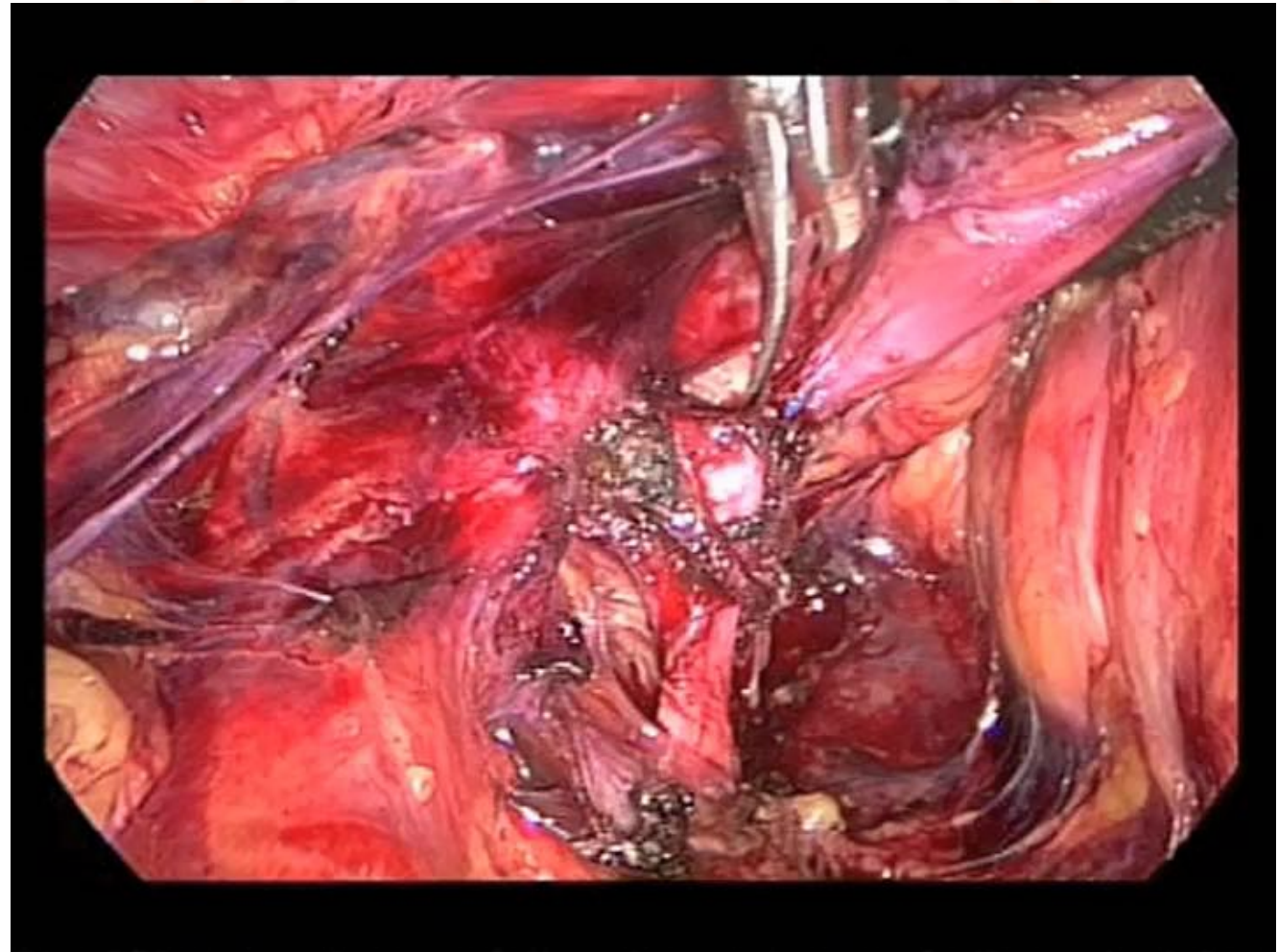

UNIVERSIDADE FEDERAL DE SÃO PAULO



increasing
INSTITUTO DE CUIDADOS, REABILITAÇÃO E ASSISTÊNCIA
EM NEUROPELVEOLOGIA E GINECOLOGIA

Grafts/Sutures



Possover M, Lemos N. Risks, symptoms, and management of pelvic nerve damage secondary to surgery for pelvic organ prolapse. Int Urogynecol J. 2011



WOMEN'S COLLEGE HOSPITAL
Health care for women | REVOLUTIONIZED



increasing
INSTITUTO DE CUIDADOS, REABILITAÇÃO E ASSISTÊNCIA
EM NEUROPELVEOLOGIA E GINECOLOGIA

Fibrosis

Symptoms

- Continuous Pain
- Varying Intensity
- Allodynia
- Trigger Point



UNIVERSITY OF
TORONTO



WOMEN'S COLLEGE HOSPITAL
Health care for women | REVOLUTIONIZED



Mount Sinai
Hospital

Sinai Health System
Joseph & Wolf Lebovic
Health Complex



UNIFESP



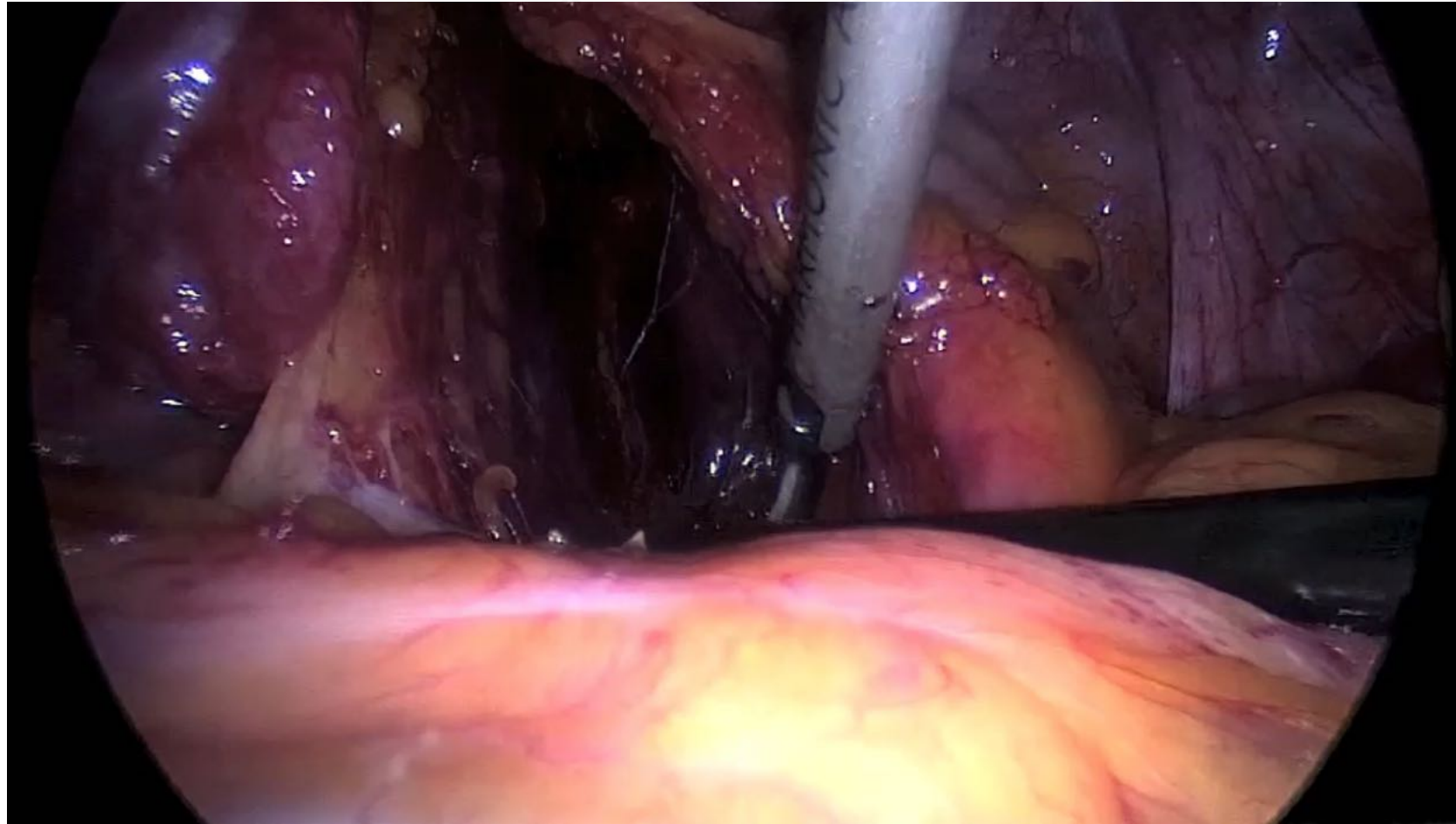
UNIVERSIDADE FEDERAL DE SÃO PAULO



increasing

INSTITUTO DE CUIDADOS, REABILITAÇÃO E ASSISTÊNCIA
EM NEUROPELVEOLOGIA E GINECOLOGIA

Vascular Entrapment



Lemos N et al. Vascular entrapment of the sciatic plexus causing catamenial sciatica and urinary symptoms. Int Urogynecol J. 2015



UNIVERSITY OF
TORONTO



WOMEN'S COLLEGE HOSPITAL
Health care for women | REVOLUTIONIZED



Mount Sinai
Hospital

Sinai Health System
Joseph & Wolf Lebovic
Health Complex



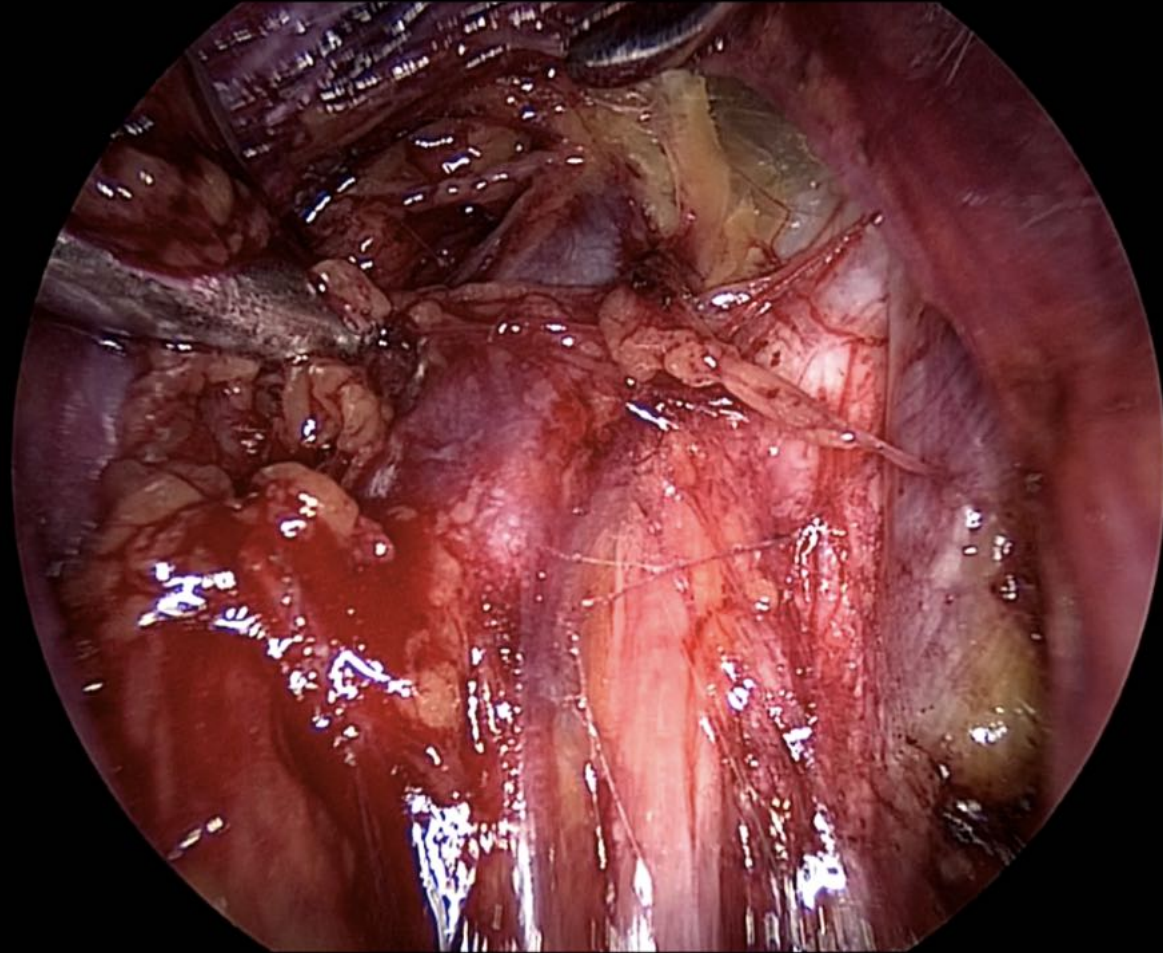
UNIVERSIDADE FEDERAL DE SÃO PAULO



increasing
INSTITUTO DE CUIDADOS, REABILITAÇÃO E ASSISTÊNCIA
EM NEUROPELVEOLOGIA E GINECOLOGIA

Vascular Entrapment

REC





UNIVERSITY OF
TORONTO



WOMEN'S COLLEGE HOSPITAL
Health care for women | REVOLUTIONIZED



Mount Sinai
Hospital

Sinai Health System
Joseph & Wolf Lebovic
Health Complex



UNIFESP



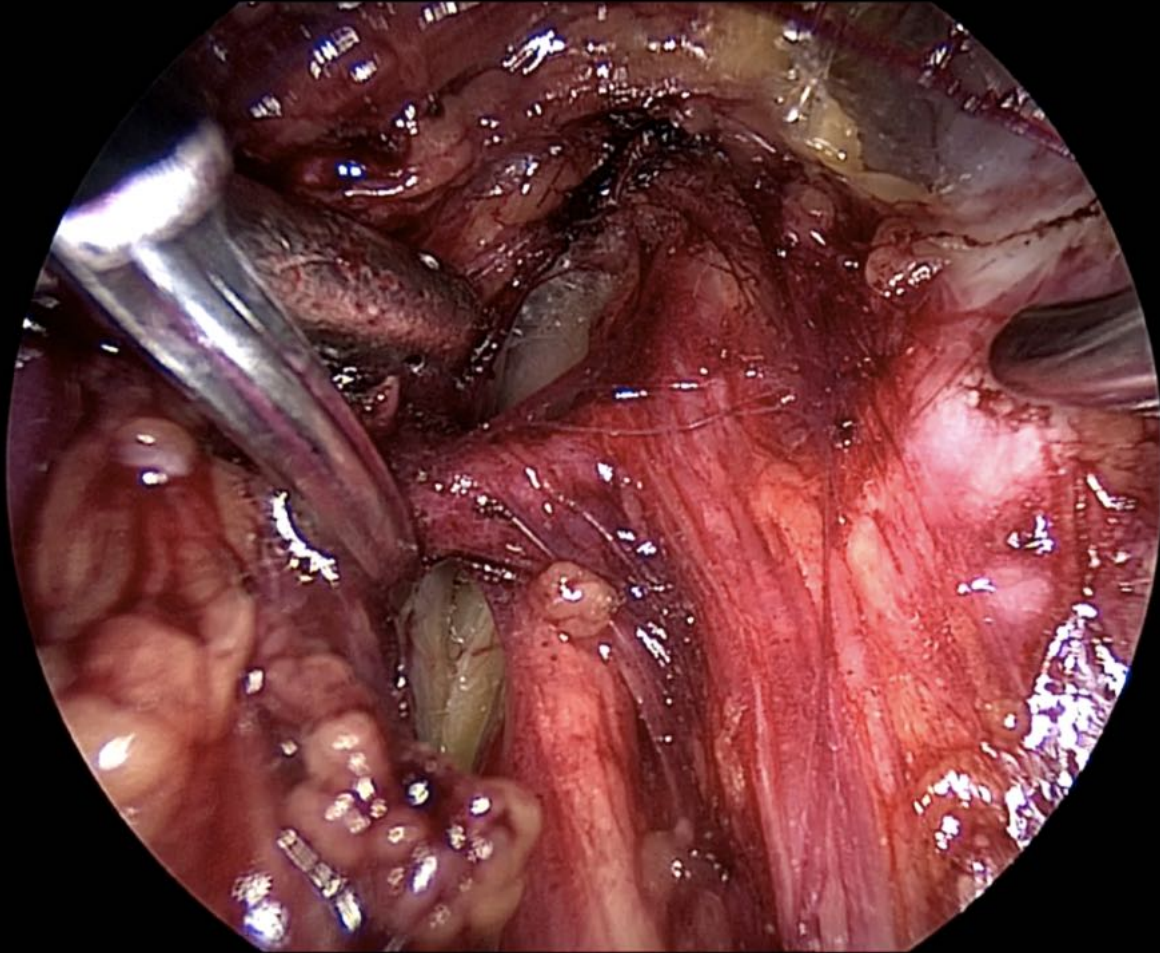
UNIVERSIDADE FEDERAL DE SÃO PAULO



increasing
INSTITUTO DE CUIDADOS, REABILITAÇÃO E ASSISTÊNCIA
EM NEUROPELVEOLOGIA E GINECOLOGIA

Vascular Entrapment

REC





WOMEN'S COLLEGE HOSPITAL
Health care for women | REVOLUTIONIZED



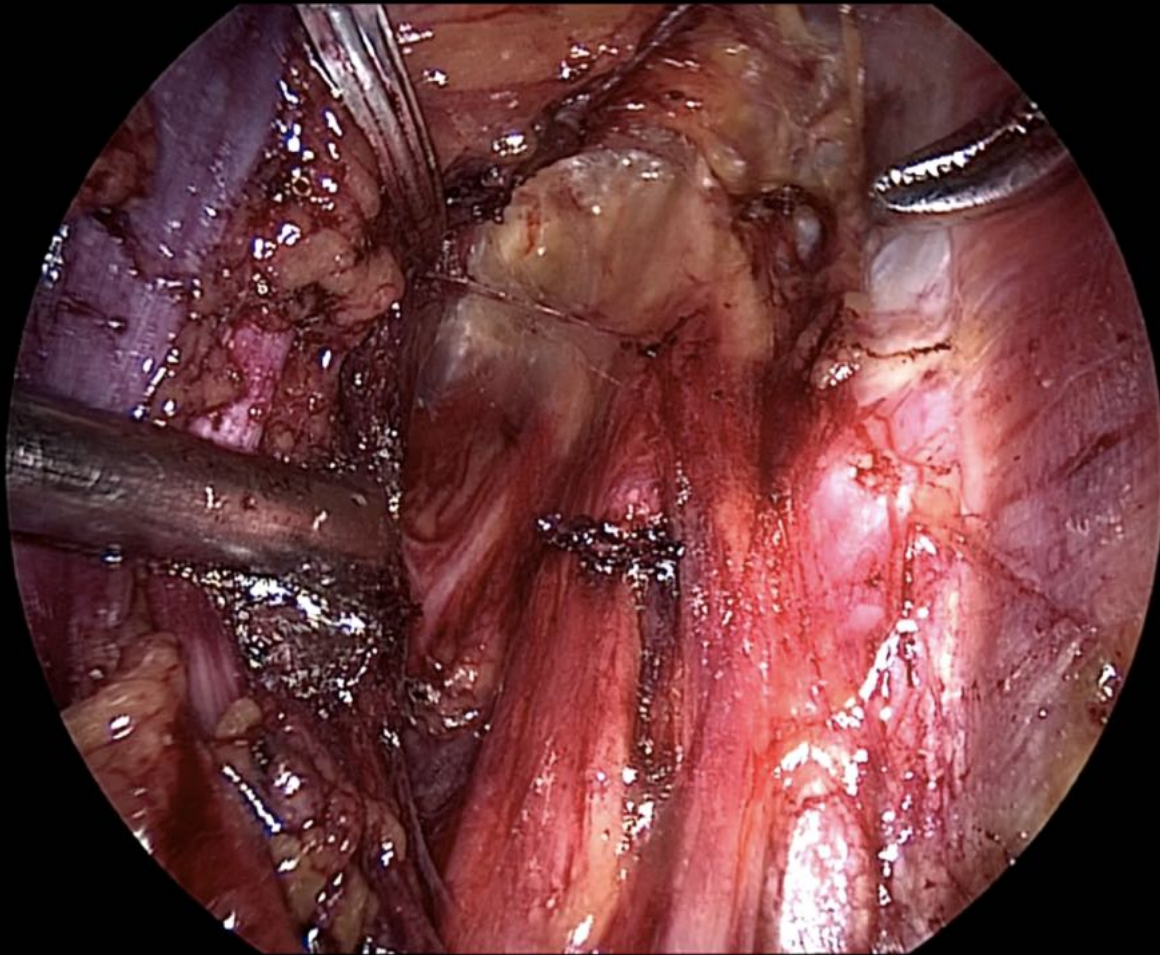
Sinai Health System
Joseph & Wolf Lebovic
Health Complex



increasing
INSTITUTO DE CUIDADOS, REABILITAÇÃO E ASSISTÊNCIA
EM NEUROPELVEOLOGIA E GINECOLOGIA

Vascular Entrapment

REC





WOMEN'S COLLEGE HOSPITAL
Health care for women | REVOLUTIONIZED



Sinai Health System
Joseph & Wolf Lebovic
Health Complex



increasing
INSTITUTO DE CUIDADOS, REABILITAÇÃO E ASSISTÊNCIA
EM NEUROPELVEOLOGIA E GINECOLOGIA

Vascular Entrapment

- Symptoms

- Cyclic ♀ / Continuous ♂
- May worsen on exercise
- LUT and anorectal symptoms



WOMEN'S COLLEGE HOSPITAL
Health care for women | REVOLUTIONIZED



Mount Sinai
Hospital

Sinai Health System
Joseph & Wolf Lebovic
Health Complex



UNIVERSIDADE FEDERAL DE SÃO PAULO



increasing
INSTITUTO DE CUIDADOS, REABILITAÇÃO E ASSISTÊNCIA
EM NEUROPELVEOLOGIA E GINECOLOGIA

Vascular Entrapment

International Journal of Gynecology and Obstetrics 125 (2014) 65–68

Contents lists available at ScienceDirect

International Journal of Gynecology and Obstetrics

journal homepage: www.elsevier.com/locate/ijgo

www.figo.org

CLINICAL ARTICLE

Safety, efficacy, and prognostic factors in endovascular treatment of pelvic congestion syndrome

Felipe Nasser ^a, Rafael N. Cavalcante ^{a,b,*}, Breno B. Affonso ^{a,b}, Marcos L. Messina ^c, Francisco C. Carnevale ^b, Miguel A. de Gregorio ^d

^a Department of Interventional Radiology, Hospital Israelita Albert Einstein, São Paulo, Brazil
^b Department of Interventional Radiology, Hospital das Clínicas, University of São Paulo Medical School, São Paulo, Brazil
^c Department of Gynecology and Obstetrics, Hospital das Clínicas, University of São Paulo Medical School, São Paulo, Brazil
^d Group of Research in Minimally Invasive Techniques, University of Zaragoza, Zaragoza, Spain

CrossMark

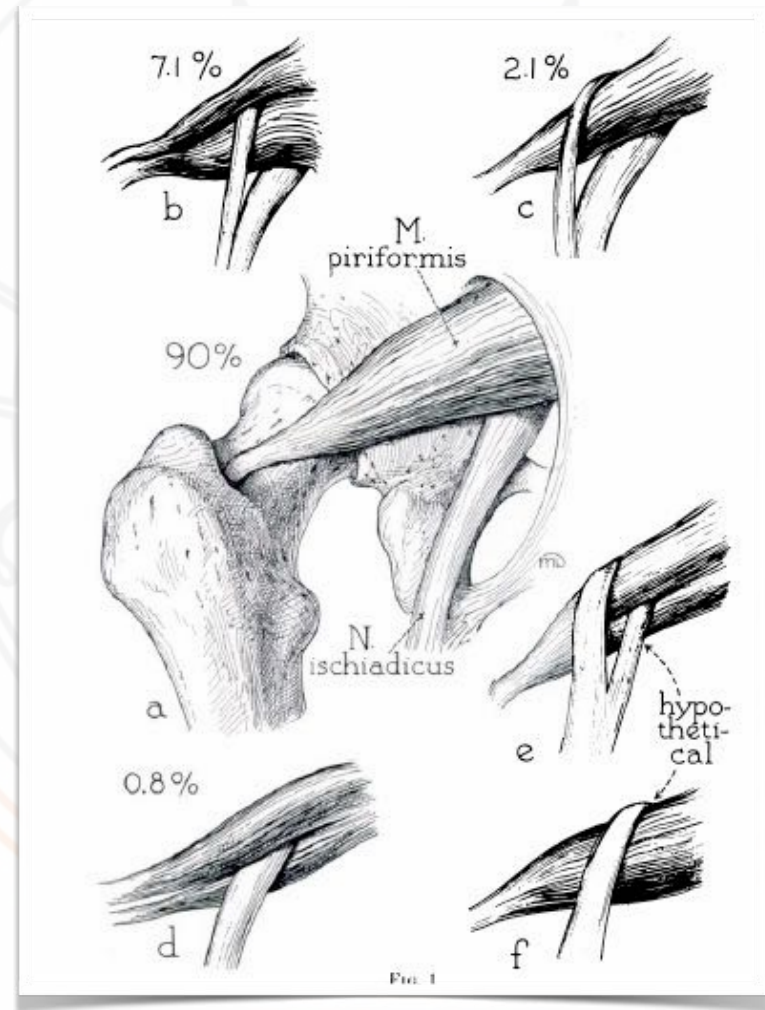
In conclusion, transcatheter embolization with coils was found to be a safe and effective treatment for PCS with high technical and clinical success rates and few complications. Lower limb symptoms, urinary urgency, and varicosities were associated with incomplete clinical success.



WOMEN'S COLLEGE HOSPITAL
Health care for women | REVOLUTIONIZED



Muscular Entrapment



Beaton & Anson. JBJS, 1938



WOMEN'S COLLEGE HOSPITAL
Health care for women | REVOLUTIONIZED



Sinai Health System
Joseph & Wolf Lebovic
Health Complex

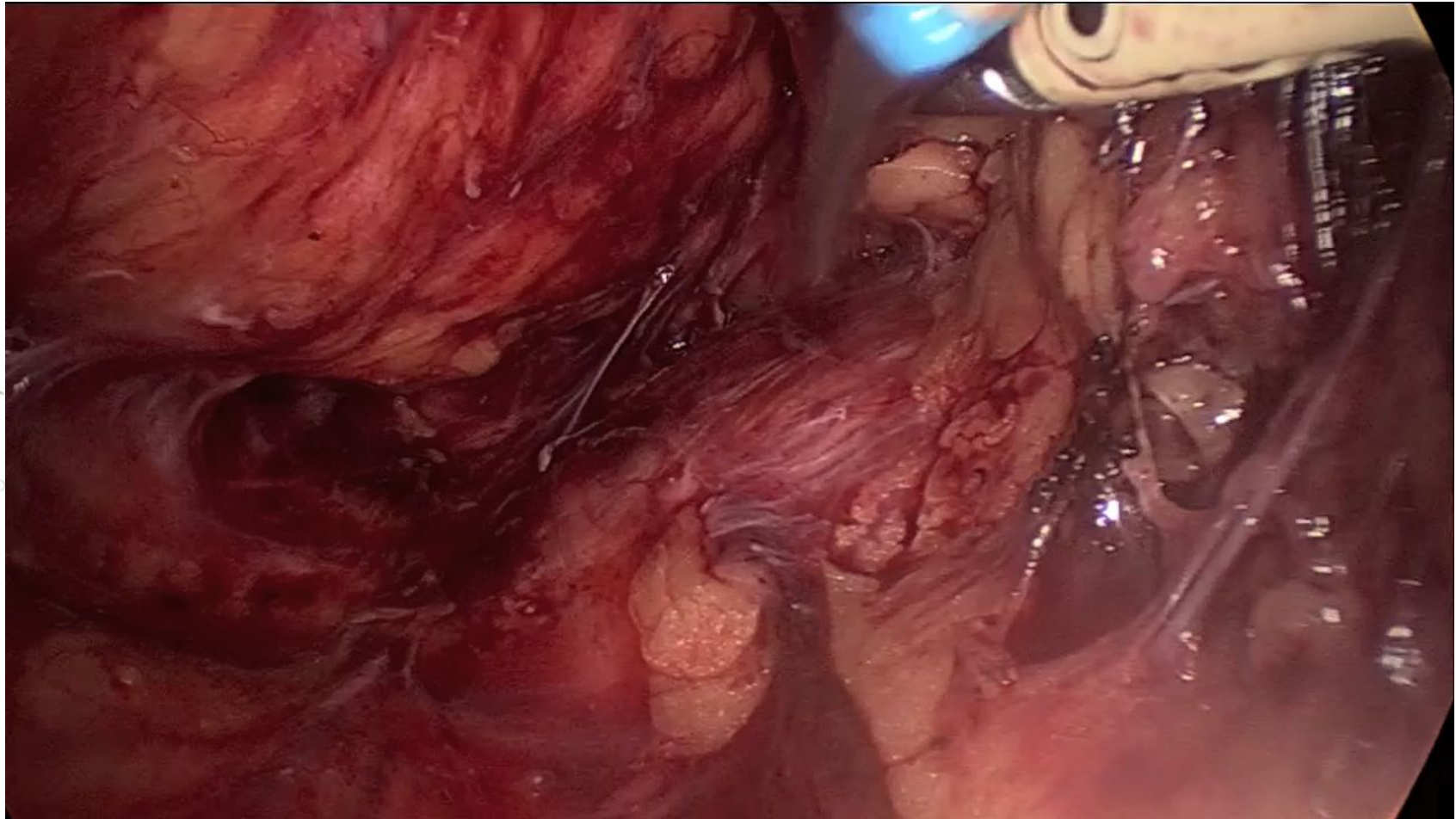


UNIVERSIDADE FEDERAL DE SÃO PAULO



increasing
INSTITUTO DE CUIDADOS, REABILITAÇÃO E ASSISTÊNCIA
EM NEUROPELVEOLOGIA E GINECOLOGIA

Muscular Entrapment





WOMEN'S COLLEGE HOSPITAL
Health care for women | REVOLUTIONIZED



Sinai Health System
Joseph & Wolf Lebovic
Health Complex



increasing
INSTITUTO DE CUIDADOS, REABILITAÇÃO E ASSISTÊNCIA
EM NEUROPELVEOLOGIA E GINECOLOGIA

Muscular Entrapment

Symptoms

- Symptoms are triggered by a specific movement
- Piriformis Syndrome – hip adduction and flexion



WOMEN'S COLLEGE HOSPITAL
Health care for women | REVOLUTIONIZED



Sinai Health System
Joseph & Wolf Lebovic
Health Complex

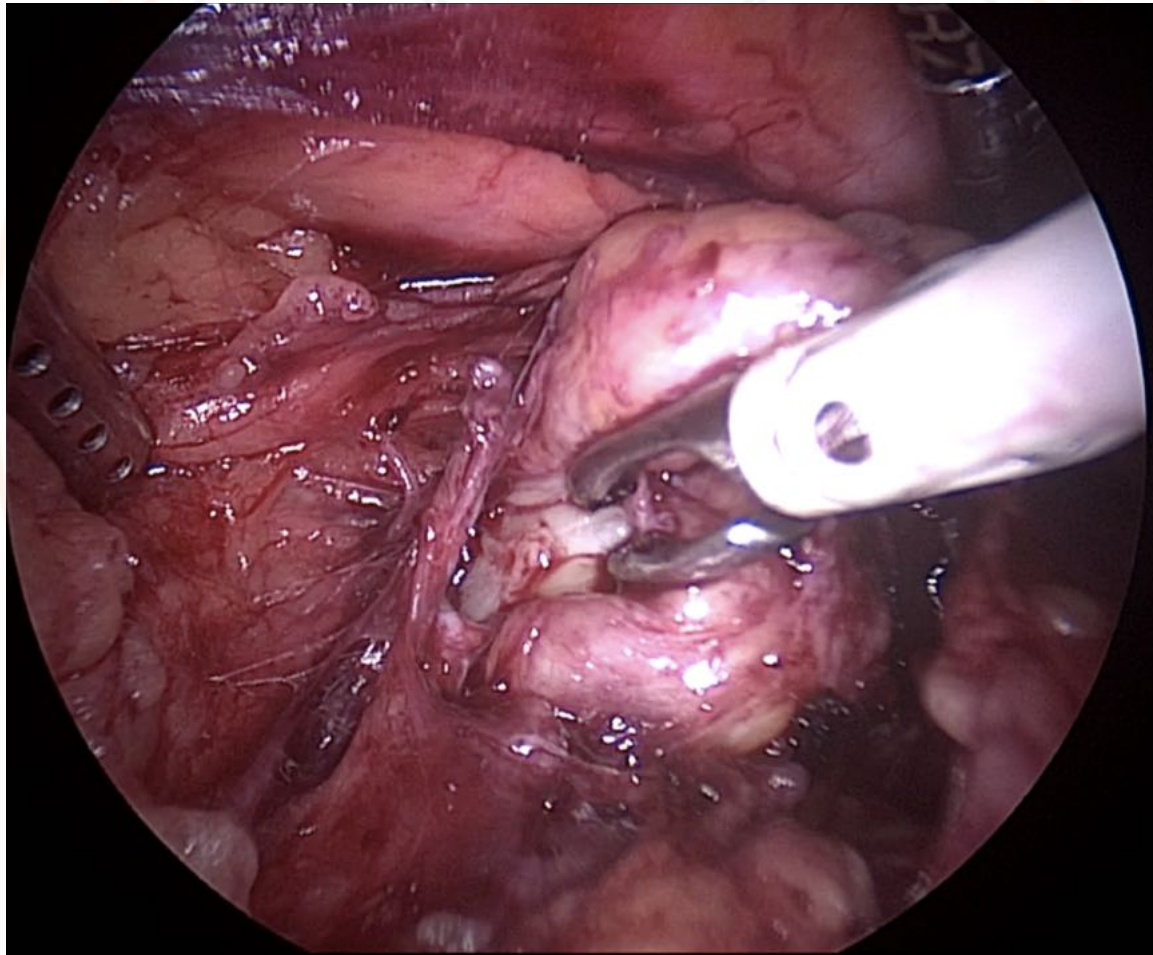


UNIVERSIDADE FEDERAL DE SÃO PAULO



increasing
INSTITUTO DE CUIDADOS, REABILITAÇÃO E ASSISTÊNCIA
EM NEUROPELVEOLOGIA E GINECOLOGIA

Neoplasms





WOMEN'S COLLEGE HOSPITAL
Health care for women | REVOLUTIONIZED



Sinai Health System
Joseph & Wolf Lebovic
Health Complex

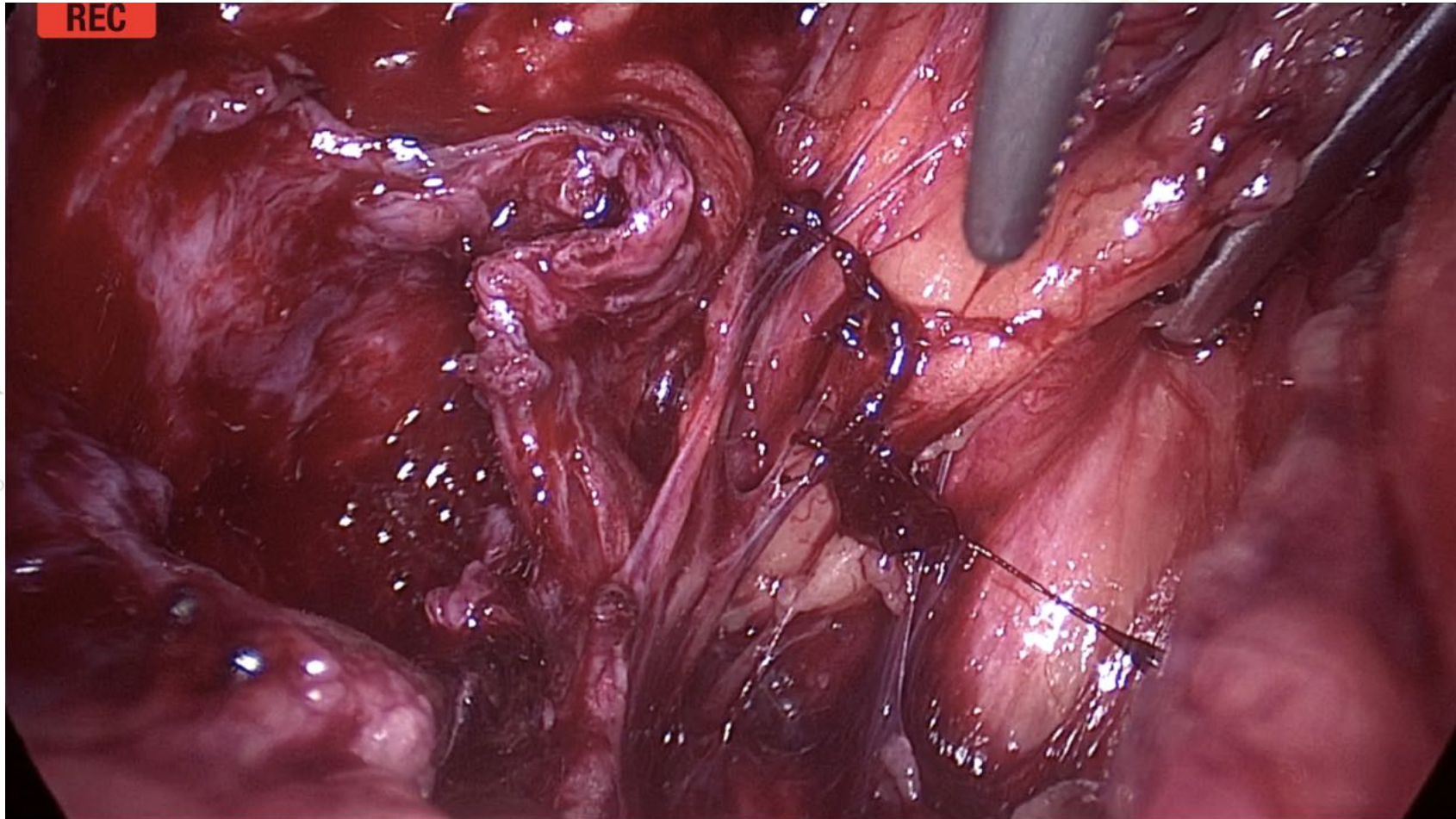


UNIVERSIDADE FEDERAL DE SÃO PAULO



increasing
INSTITUTO DE CUIDADOS, REABILITAÇÃO E ASSISTÊNCIA
EM NEUROPELVEOLOGIA E GINECOLOGIA

Neoplasms





WOMEN'S COLLEGE HOSPITAL
Health care for women | REVOLUTIONIZED



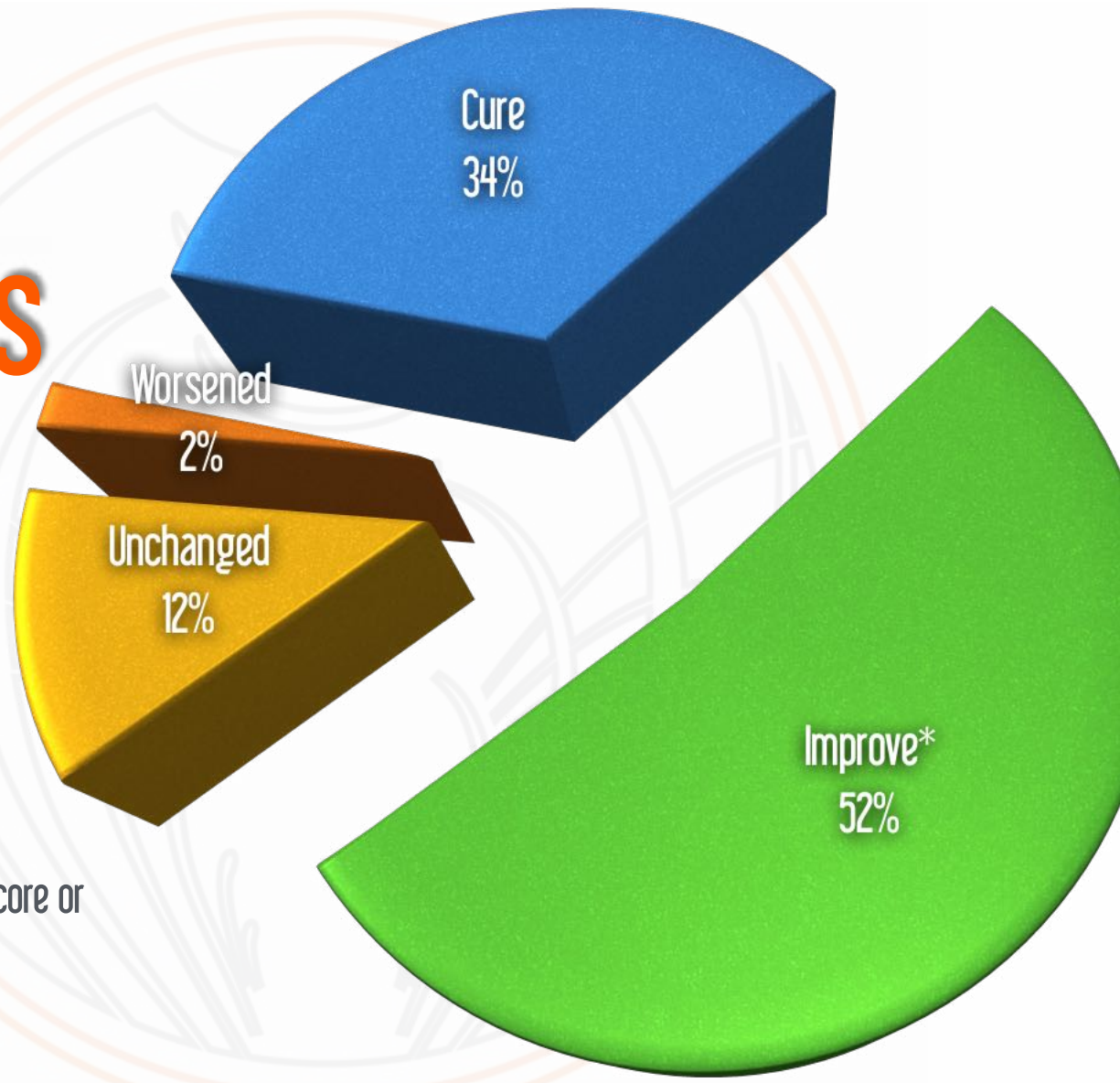
Surgical Outcomes

Variable	Mean	Median	Std. Dev.	p-value
Age	39.1	37.5	9.7	-
Follow-up (mos)	13.3	7.3	14.7	-
Pre-op Pain (VAS)	8.7	10	2.1	*
Post-op Pain (VAS)	2.2	1	2.7	<0.000000001
Operating Time (min)	171	152	90.6	-
Previous Surgeries	1.2	1	1.5	-
Diagnostic Gap (years)	4.5	4	3.9	-
Success Rate	86%			

* paired t-Test



Surgical Outcomes



- * $\geq 50\%$ reduction in VAS score or analgesics dose

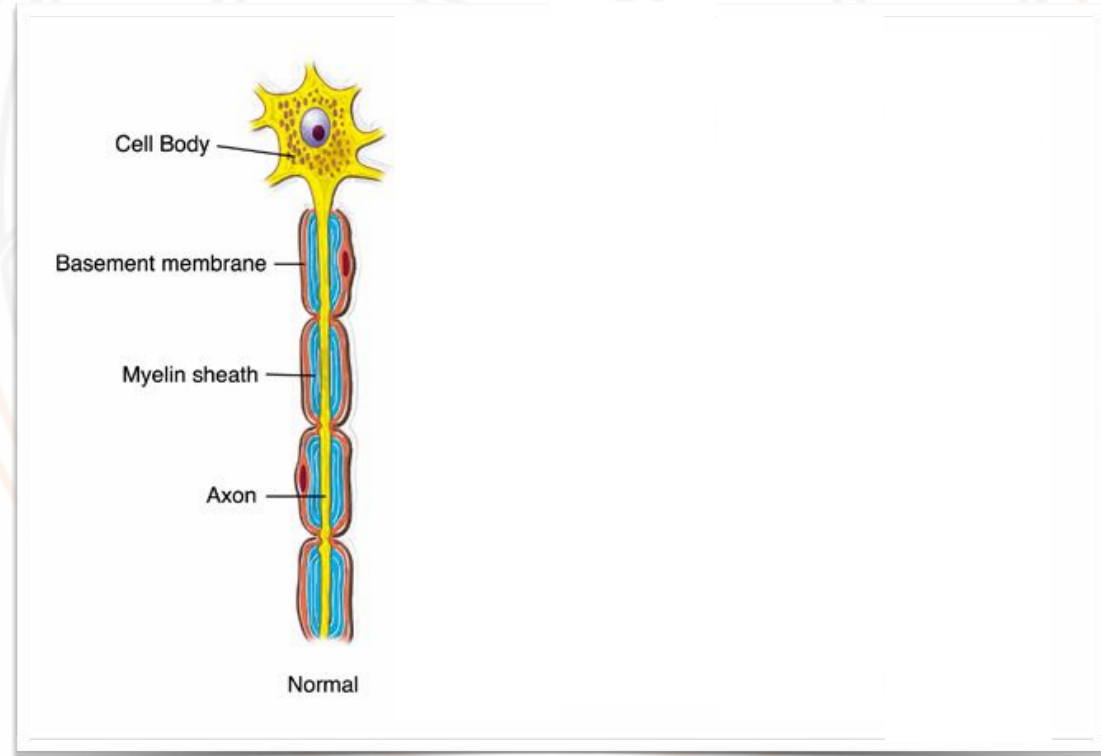
Lemos N et al. Intrapelvic Nerve Entrapments – A Neglected Cause Of Perineal Pain And Urinary Symptoms. Neurourology and Urodynamics. 2017



WOMEN'S COLLEGE HOSPITAL
Health care for women | REVOLUTIONIZED



Treatment ALWAYS Starts by Detrapment!!!!



Rempel D, Dahlin L. Pathophysiology of Nerve Compression Syndromes: Response of Peripheral Nerves to Loading. J Bone Joint Surg Am, 1999




WOMEN'S COLLEGE HOSPITAL
Health care for women | REVOLUTIONIZED



increasing
INSTITUTO DE CUIDADOS, REABILITAÇÃO E ASSISTÊNCIA
EM NEUROPELVEOLOGIA E GINECOLOGIA

Nerve Transection

- Laparotomy
(iliohypogástric, ilioinguinalis)
 - Incision
 - Retractors
- Laparoscopy
(iliohypogástric, ilioinguinalis)
- Episiotomy
(pudental nerve rami)
- Lower Limb Amputation
(Sciatic e femoralis)



Neuroma





WOMEN'S COLLEGE HOSPITAL
Health care for women | REVOLUTIONIZED



Sinai Health System
Joseph & Wolf Lebovic
Health Complex



increasing
INSTITUTO DE CUIDADOS, REABILITAÇÃO E ASSISTÊNCIA
EM NEUROPELVEOLOGIA E GINECOLOGIA

Nerve Transection

Symptoms

- Continuous intense pain
- Anesthesia and muscular atrophy on the nerve territory
- Phantom pain

Diagnosis

- Proximal anesthetic block



WOMEN'S COLLEGE HOSPITAL
Health care for women | REVOLUTIONIZED



increasing
INSTITUTO DE CUIDADOS, REABILITAÇÃO E ASSISTÊNCIA
EM NEUROPELVEOLOGIA E GINECOLOGIA

Adjuvant Therapies

- Pharmacotherapy
 - Anticonvulsants
 - Gabapentinóids
 - Gabapentine
 - Pregabalin
 - Others
 - Carbamazepine
 - Antidepressants
 - Amitriptiline
 - Imipramine
 - Opioids
 - Oxycodone
 - Codeine
 - Tramadol
 - Anaesthetic/Opioid Patches
- Physiotherapy
 - TENS
 - Ultrasound
 - PFM exercises, myofascial liberation, postural re-education
- Acupuncture/Electroacupuncture
- Intervention Pain Therapies
 - Blocks (bupi/ropivacaine+corticoid)
 - Radio-frequency
- Surgical Neuromodulation



WCHI

WOMEN'S COLLEGE HOSPITAL
Health care for women | REVOLUTIONIZED



Sinai Health System
Joseph & Wolf Lebovic
Health Complex



increasing
INSTITUTO DE CUIDADOS, REABILITAÇÃO E ASSISTÊNCIA
EM NEUROPELVEOLOGIA E GINECOLOGIA



In Conclusion...



WOMEN'S COLLEGE HOSPITAL
Health care for women | REVOLUTIONIZED



Mount Sinai
Hospital

Sinai Health System
Joseph & Wolf Lebovic
Health Complex



UNIVERSIDADE FEDERAL DE SÃO PAULO



increasing
INSTITUTO DE CUIDADOS, REABILITAÇÃO E ASSISTÊNCIA
EM NEUROPELVEOLOGIA E GINECOLOGIA

In Conclusion...

- Laparoscopy provides minimally invasive access with optimal visualization to all of the following nerves:

One must always keep in mind that the intrapelvic portion of the lumbosacral plexus may also be subject to entrapments

- Femoral
- Ant. Cut. Fem
- Sciatic
- Pudendal
- Obturator
- Ilio-Hypogastric

- Ilio-Inguinal
- Genito-Femoral
- Hypogastrics
- Pelvic Splanchnic
- Sacral Nerve Roots
- Lumbosacral Trunk
- Inferior Hypogastric Plexus
- Superior Hypogastric Plexus



WOMEN'S COLLEGE HOSPITAL
Health care for women | REVOLUTIONIZED



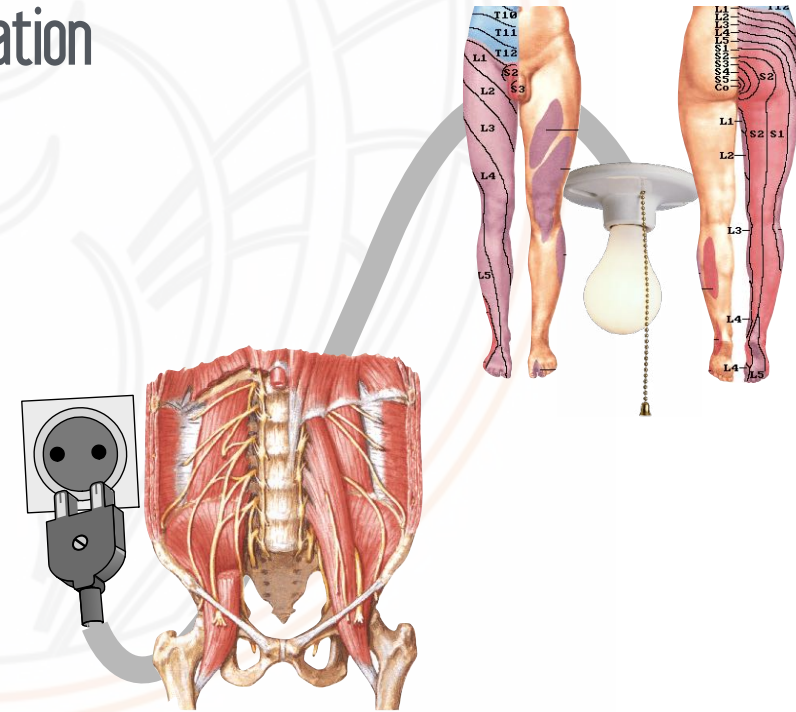
Sinai Health System
Joseph & Wolf Lebovic
Health Complex



increasing
INSTITUTO DE CUIDADOS, REABILITAÇÃO E ASSISTÊNCIA
EM NEUROPELVEOLOGIA E GINECOLOGIA

In Conclusion...

- Perineal, Gluteal and/or Lower Limb pain or allodynia
- Vaginal/Rectal Foreign Body Sensation
- Refractory OAB
- Dyschezia
- Proctalgia
- Vesical and/or Rectal Tenesmus





WOMEN'S COLLEGE HOSPITAL
Health care for women | REVOLUTIONIZED



In Conclusion...

- Treatment rationale in intrapelvic neuropathies:
 - Precise Preoperative Diagnosis
 - Functional MRI (Tractography)
 - Diagnostic Blocks
 - Mechanical Decompression
 - Physiotherapy, acupuncture e Pharmacotherapy
 - Intervention Pain Therapies
 - Neuromodulation



WOMEN'S COLLEGE HOSPITAL
Health care for women | REVOLUTIONIZED



Sinai Health System
Joseph & Wolf Lebovic
Health Complex



increasing
INSTITUTO DE CUIDADOS, REABILITAÇÃO E ASSISTÊNCIA
EM NEUROPELVEOLOGIA E GINECOLOGIA



Thank You!

nucelio@gmail.com

www.neurodisfuncao.med.br

UNIFESP
UNIVERSIDADE FEDERAL DE SÃO PAULO

ICS 2017
FLORENCE

Role, Techniques and Rationale of Physical Therapy on the Post-Operative Treatment of Intrapelvic Nerve Entrapments

Marília Frare

ICS

COI Declaration

No conflicts of interest to declare.

ICS

Surgical Outcomes

Surgical Outcomes

- Cure
- ≥50% improvement
- Unchanges
- Worsening

ICS

Intrapelvic Nerve Entrapments

- Diagnostic/treatment delay of approximately 4 years (Lemos et al, 2017)
- Median 1 unsuccessful, non-specific surgical procedure (Lemos et al, 2016; Possover et al, 2011)

ICS

Neuronal Degeneration

Cell Body
Basement membrane
Myelin sheath
Axon

Normal Compressed Sheath Loss Disconnection Degeneration

Rempel et al. ICS

Chronic Pain

- Pathological in itself – often persists well after an inciting stimulus or injury has resolved.
- Result of functional and structural rearrangements of the CNS

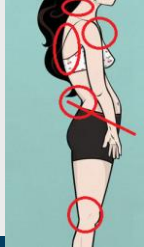
(Latremoliere, 2009)

ICS

Typical Pelvic Pain Posture

• 85% of patient with CPP presents musculoskeletal dysfunctions that could be adaptation to alleviate the pain

- Lumbar hyperlordosis
- Knee hyperextension
- Pelvic anterioration
- Levator ani muscle spasm
- Piriformis muscles spasm



(Moore, 2000)



Fibrosis

- Surgical manipulation itself is an important cause of fibrosis over the sacral plexus



(Possover M, Lemos N., 2011)



Goals of PostOp Physiotherapy Treatment

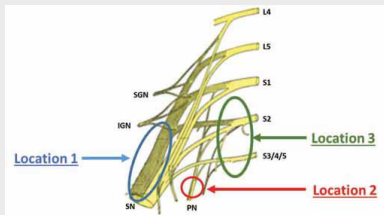
- To decrease neuropathic pain
- To restore function (motoric, urinary, bowel and sexual)
- To prevent postoperative fibrotic nerve entrapments



Evaluation



Surgical Report

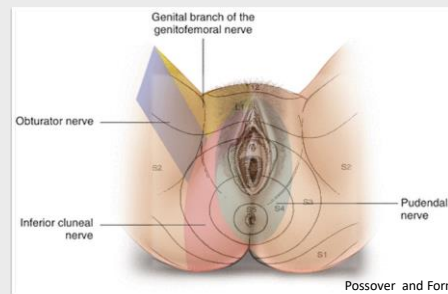


SN: sciatic nerve, PN: pudendal nerve, SGN: superior gluteal nerve, IGN: inferior gluteal nerve. L: lumbar, S: sacra

Possover and Forman, 2015



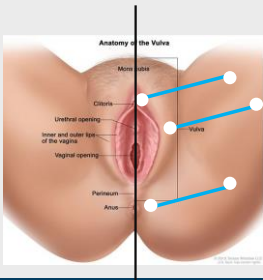
Sensitive Nerve Assessment Assessment



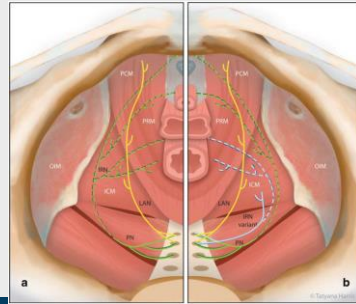
Possover and Forman, 2015



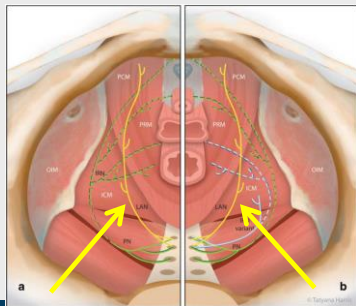
Sacral Reflexes



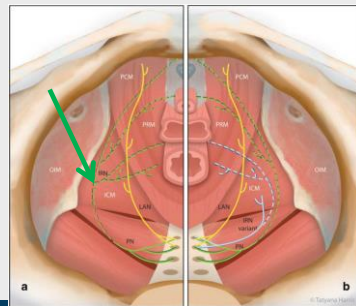
Motoric Assessment



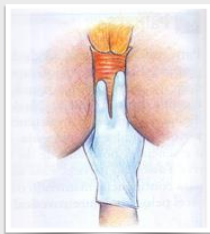
Motoric Assessment



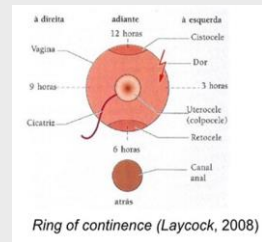
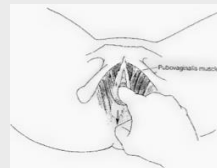Motoric Assessment



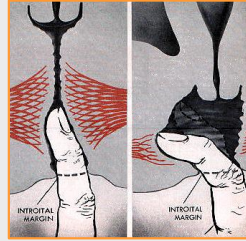
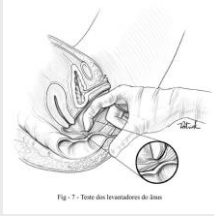
Digital Palpation



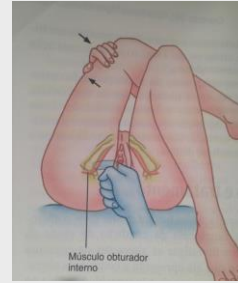
Spasms and Trigger Points



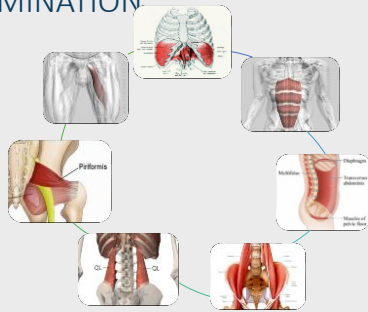
Spasm and Trigger Points



Obturator Internus Muscle Assessment



MANUAL PELVIC MUSCLE EXAMINATION



(Lin, 2001)

Post-surgical transient urinary and anorectal symptoms

- Urinary urgency
- Faecal urgency
- Voiding dysfunction
- Dyschesia
- Dysuria
- etc.

24 Hour Bladder Diary				Date 12/03/14	
Time	Drinks		Urine		Pads
	Amount (ml)	Type	Amount (ml)	Bladder Sensation	
6am	WAKE		500	2	
7am	300	Water			
8am			✓	2	
9am					
10am	Cup	Tea	LEAK	3	✓
11am					
Midday					

Pain Management Strategies



Post-decompression Syndrome

- Occurring after a few (2-10) days of postoperative pain relief
- Characterized by the reappearance of severe allodynia with cutaneous paresthesia

Possover and Forman, 2015



Post-decompression Syndrome

- 25% of patients will present with post-decompression neuropathic pain (mean duration: 5.5 months)
- 17% will present neuropathic strength loss (mean dur.: 2.5 months)



KEEP
CALM

Lemos et al, 2015

DESENSITIZATION

- Gradually
- Improve tolerance to touch in a painful region
- Restoring the normal pathways of the communication between sensory receptors and the brain

(Bradley, 2017)



DESENSITIZATION



ELECTRICAL STIMULATION

- Improvement of muscle proprioception
- Decrease of nociceptive signal flows (ie, gate control theory)
- Secretion of endorphins

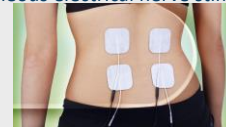

(Bélanger, 2014)



ELECTRICAL STIMULATION

- Transcutaneous electrical nerve stimulation (TENS)




- Percutaneous nerve stimulation (PNS)

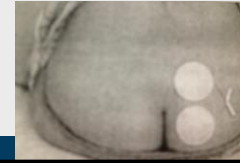
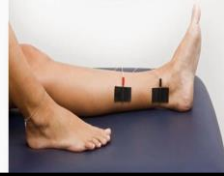
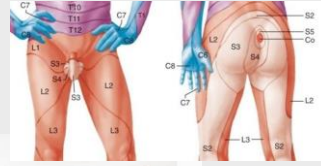ELECTRICAL STIMULATION

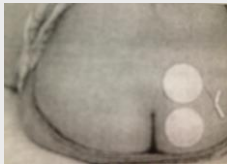- Intravaginally or Intra rectally



ELECTRICAL STIMULATION



ELECTRICAL STIMULATION

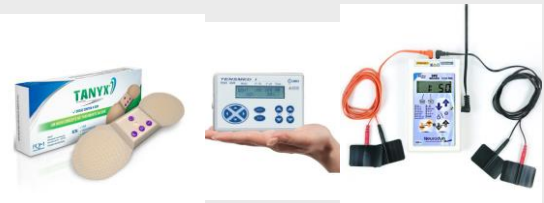

TENS
Frequency: 8 Hz
Pulse duration: 250 ms

Mira et al., 2015

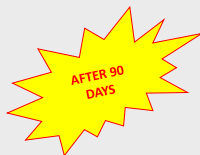

Home-based therapy



Thiele's Massage

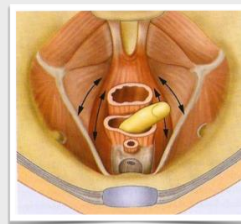
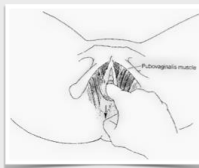- Thiele's massage can be used intravaginally or intra rectally to stretch the levator ani muscles and reduce scar tissue or trigger points and reduce pain with intercourse



(Oyama, 2004)



Thiele's Massage

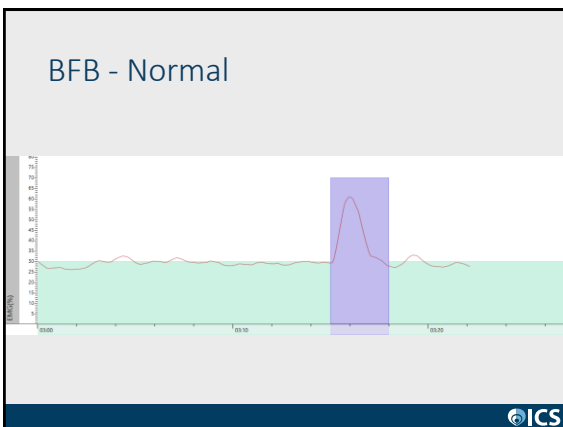
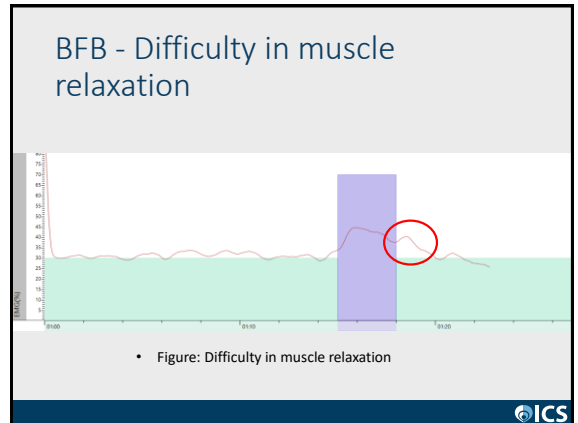
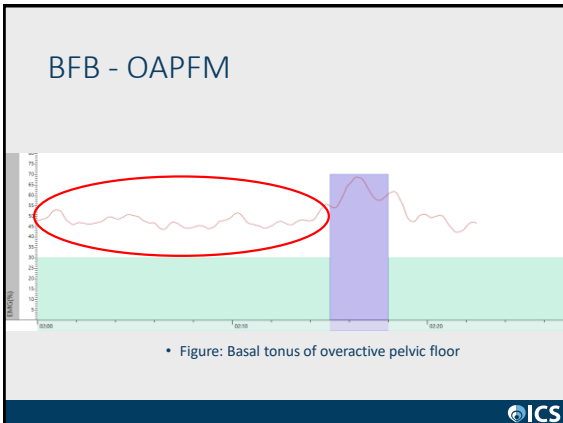


Manual Therapy

Rosenbaum and Owens, 2008

BIOFEEDBACK

- Understanding of how to relax
- Reducing pain
- Muscle coordination for voiding

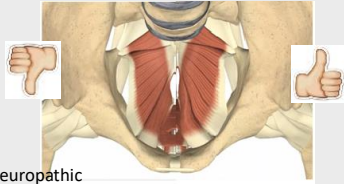


BIOFEEDBACK

- Women with vulvar pain
- Electromyographic (EMG) biofeedback protocol
- 52% of women → pain-free sexual intercourse

Glazer et al

Keeping the balance

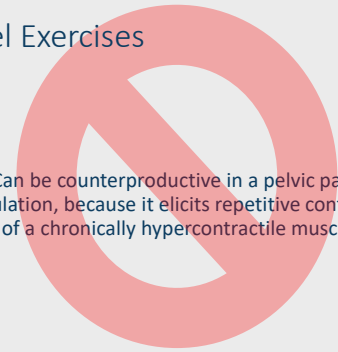


neuropathic strength loss (2,5 months)



Kegel Exercises

Can be counterproductive in a pelvic pain population, because it elicits repetitive contraction of a chronically hypercontractile muscles




(Till, 2017)



Preventing Fibrosis

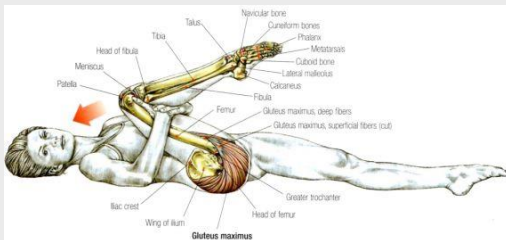


VÍDEO

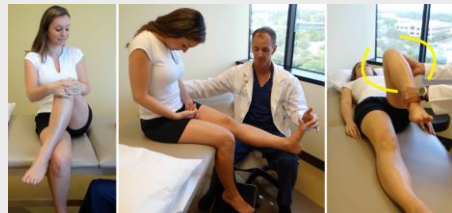

Neural Mobilization

Postoperative adherence prevention



Piriformis stretch, sciatic nerve glides and hip circumduction



Hal D. Martin, Baylor School of Medicine – Dallas, TX, USA



In Conclusion...

- Goals of postoperative physical therapy
 - To decrease neuropathic pain
 - To restore function (motoric, urinary, bowel and sexual)
 - To prevent postoperative fibrotic nerve entrapments
- Main strategies
 - desensitization, electrical stimulation
 - Thiele's massage
 - Biofeedback
 - lifestyle and behavior modifications and neural mobilization
- Support Comfort patients!!!



Obrigada!
Thank you!

Pelvic Neurodysfunction Team - UNIFESP/EPM

- Dr Nucélio Lemos
- Ms Christine Ploger
- Esp Juliana Domingues
- Esp Laíse Veloso
- Esp Marília Frare



mariliafrare@gmail.com

