



W6: Management of Complications of Mesh Prolapse and Sling Surgery - Demonstration through Surgical Video Cases

Workshop Chair: Howard Goldman, United States
13 September 2016 11:00 - 12:30

Start	End	Topic	Speakers
11:00	11:30	Management of Synthetic Sling Complications	Sandip Vasavada
11:30	11:45	Questions	All
11:45	12:15	Management of Prolapse Mesh Complications	Howard Goldman
12:15	12:30	Questions	All

Aims of course/workshop

Many surgeons learn best by observing expert surgeons. Given the number of mesh sling and prolapse repair cases performed experts are confronted with complications of such cases. Most patients with such complications who are appropriately treated have resolution of symptoms. The critical point is that those surgeons dealing with such cases have the expertise to successfully manage them. This course will review the management of such complications with a focus on using surgical video demonstrations to specifically review the surgical techniques necessary for successful outcomes.

Learning Objectives

This course details the management of different types of sling and prolapse mesh complications utilizing surgical videos and case discussion. The following complications will be reviewed via such a format.

Transvaginal prolapse mesh extrusion
Mesh bladder perforation
Mesh arm/stone in bladder
Mesh arm in bladder around ureter
Mesh perforation of the urethra
Sling incision
Single port mesh removal
Urethral damage due to sling - Neourethra formation
Thigh pain due to transobturator mesh arm – thigh dissection
Transvaginal sling excision: Tips and tricks

Target Audience

Expert pelvic floor surgeons who deal with mesh complications

Advanced/Basic

Advanced

Transvaginal prolapse mesh extrusion:

From 3-15% of transvaginal prolapse meshes may extrude vaginally. When asymptomatic some may be left alone. Vaginal estrogen cream has been reported to allow reepithelialization in some cases. If symptomatic, and very small, excision may be attempted in the office. In other cases excision should be done in the operating room. The area of extrusion is carefully identified and lidocaine with epinephrine is injected under the vaginal skin around the extrusion. Typically a small cuff of skin is excised after which vaginal skin flaps are developed using sharp and blunt dissection in all direction for at least 1 cm. Finally, the mesh is incised at one side and then the underlying tissue (bladder/rectum) is carefully dissected off of the undersurface of the mesh taking great care to stay right on the mesh and leave all other underlying tissue intact. Enough mesh is removed so that there will be no mesh under the skin closure.

Mesh perforation of the bladder:

If a mesh arm or sling has traversed the bladder removal is usually necessary. Some advocate excision with laser. If that is attempted care must be taken to cut deep to the musosa, into the muscle so that no mesh filaments are able to work their way back into the bladder. Oftentimes this approach has to be repeated.

Our preference is to surgically explore and remove the mesh completely within the bladder and bladder wall. For mesh arms in the lower half of the bladder this can usually be done transvaginally. A vaginal wall flap is made whose base is at the site of bladder entry. This is to prevent later overlapping suture lines. If the mesh is near the ureter an open ended ureteral catheter is placed. The sling/mesh is then located either medially or laterally (in the case of one perforating the obturator internus muscle) and carefully dissected into and then back out of the bladder. The bladder incision is closed in multiple layers and the vaginal wall flap closed over that. A catheter is left in place for 1-2 weeks.

If there is a stone on the mesh it often will come out intact with the mesh. If it is very large it can be lasered at the same setting prior to the mesh dissection.

Some perforations in the anterior bladder may be removed transvaginally. However, more often an open/robotic/laparoscopic approach is needed. A simple approach is via a Pfannenstiel incision where the perforating mesh is located where it enters and exits the bladder, the bladder is then opened, the entry sites are cored out, the mesh is removed, the entry sites are closed and the bladder is closed.

Occasionally the mesh arm may be very close to the ureter or may even wrap around the intramural ureter. A careful transvaginal approach can typically be used to dissect around the ureter.

In some instances a portion or entire piece of mesh placed for prolapse may end up in the bladder. A vaginal flap is developed and if the mesh can be identified the superficial vaginal wall is dissected off of it. The mesh is then transected in the midline and the bladder tissues deep to it are dissected free of the mesh. The mesh pieces are cut as laterally as possible after which the cystotomy is closed in multiple layers and the flap is closed. In some cases when the entire mesh is in the bladder the bladder must be bivalved to get to the mesh. A similar procedure is then followed. Bilateral stents are typically placed in these cases. A catheter is left to drainage for 2 weeks and a cystogram is obtained prior to removal.

Single-Port Sling Excision:

The use of single port technology has allowed minimally invasive intervention to help with sling excisions. When a sling is calcified and or otherwise perforated into the bladder, definitive excision should be undertaken in most circumstances. Single port access either directly into the bladder or with a combined intra and extravesical approach can allow definitive excision of the sling and adjacent sling. It remains important to allow a margin of sling to be excised deep to the mucosa (in the muscle layer) to avoid another segment perforation. Bladder repair of the entry sites can be challenging with this modality and requires specialized skills. Other forms of minimally invasive surgery (laparoscopy and robotics) can be undertaken as well for extravesical management of the sling.

Urethral Perforation:

Slings placed either inadvertently through the urethra or one that is under excess tension may result in a urethral perforation. We are generally not in favor of "minimally invasive" approaches, which may leave residual mesh particles projecting into the urethra. Our preference is for a definitive procedure such that all mesh near the urethra is removed to ensure no further mesh issues. In some cases where the mesh can be located outside of the urethra – usually laterally – it can be traced into the urethra through a small lateral entry, one on each side, removed and each of these sites of entry closed. Oftentimes the mesh is very deep and difficult to identify.

The surgical procedure may be better served by initially starting with an inverted U incision to allow flap coverage of the urethra at the end. Once the flap is taken down, paraurethral exposure is gained to allow palpation of the sling ends (may require entry into the retropubic space). Usually one side is cut and then sometimes the sling can be pulled out of the other side. If this is not an option one may need to directly open the urethra. By placing the scope at the level of the perforation one can palpate and see (the light) the area to incise. One must be sure to excise the perforated sling completely as to not leave any mesh remnants. Regardless of which approach is used to remove the sling, closure of the perforations and pressure testing should be performed to assure integrity to the urethra. A catheter should be left in for 2 weeks postoperatively.

Urethral destruction following sling:

Most sling excision and repairs are fairly straightforward; however, some can completely transect and damage the urethra. One must consider urethroplasty techniques to surgically re-establish continuity to the urethra. The adjunctive use of a Martius flap should be strongly considered as the urethra is a high pressure zone and this flap placement may minimize fistula formation.

Severe thigh pain after transobturator sling:

Temporary thigh pain after a transobturator sling is not uncommon. It typically resolves within a few days. On very rare occasions severe thigh pain can persist and if unresolved after conservative management a thigh dissection to identify and remove the thigh portion of the mesh may be necessary.

An incision is made about one cm lateral to the thigh crease. On rare occasions the sling may be identified in the subcutaneous tissues and then followed through the muscles to the obturator foramen. Typically, the sling is not evident until a more complete dissection has been performed. We typically detach the gracilis and adductor brevis from the pubis to allow for complete inspection in the area of the obturator externus. The adductor longus tendon is the superior margin and we do not incise that. On occasion though the sling may be found above or in the tendon. Once the sling is identified (often via blunt palpation) it is dissected and followed out to the subcutaneous tissues and back to the obturator membrane allowing for complete removal. The skin and deeper layers are closed and a closed suction drain is left in place.

References

- Frenkl T, Vasavada S, Rackley R, Goldman HB. Management of iatrogenic foreign bodies of the bladder and urethra following pelvic floor surgery. *Neurourol Urodyn* 2008; 27(6); 491-5.
- Ridgeway B, Walters MD, Paraiso MF, Barber MD, McAchran SE, Goldman HB, Jelovsek JE. Early experience with mesh excision for adverse outcomes after transvaginal mesh placement using prolapse kits. *Am J Obstet Gynecol* 2008; 199(6):703
- Firoozi F, Goldman HB. Transvaginal excision of mesh erosion involving the bladder after mesh placement using a prolapse kit: a novel technique. *Urology* 2010
- Firoozi F, Ingber MS, Moore CK, Vasavada SP, Rackley RR, Goldman HB. Purely trans-vaginal/perineal management of complications from commercial prolapse kits with use of a new prostheses/grafts complication classification system. *J Urol.* 2012 May; 187(5):1674-9
- Firoozi F, Goldman HB. Pure transvaginal excision of mesh erosion involving the bladder. *Int Urogynecol J* 2013 Jun; 24(6):925-6
- Moore CK, Goldman HB. Simple sling incision for the treatment of iatrogenic bladder outlet obstruction. *Int Urogynecol J.* 2013 Dec; 24(12):2145-6
- King AB, Tenggardjaja C, Goldman HB. *J Urol.* 2016 (in print)

Managing complications of Prolapse and Sling Mesh – Case Management Examples Utilizing Surgical Videos

Howard B Goldman MD

Center for Female Pelvic Medicine and Reconstructive Surgery
Glickman Urologic and Kidney Institute
Lerner College of Medicine
Cleveland Clinic
Cleveland, Ohio
USA

Agenda

- Sling incision
- Sling in urethra
- Sling removal – Tips and Tricks
- Transvaginal prolapse mesh extrusion
- Mesh bladder perforation
- Mesh arm in bladder around ureter
- Single port mesh removal
- Urethrovaginal fistula after sling
- Urethral damage due to sling - Neourethra formation
- Thigh pain due to transobturator mesh arm – thigh dissection

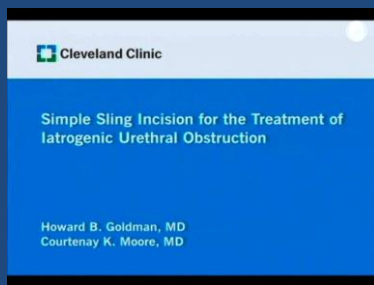
Mesh Sling Complications Presenting Symptoms

- Obstruction
- Recurrent UTI
- Dyspareunia/Hispareunia
- Pain
- Vaginal Discharge

Obstruction

- 2-5% of midurethral synthetic slings
- Patients should be voiding normally within a few days
- Slow stream
- “De-novo” urgency
- Recurrent UTIS

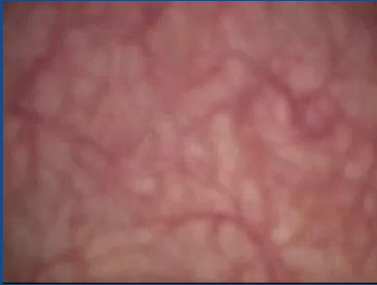Sling Incision



Sling in Urethra


- Obstruction
- Recurrent UTIs
- Pain
- Hematuria
- Incidental
- Likely due either to prolonged excessive tension or placed in urethra during surgery

Sling in Urethra




- Can be difficult to find as very deep
 - Sometimes can trace from outside urethra
 - Sometimes need to open urethra to find
 - Use scope tip to localize

Removal of Sling from Urethra



Tips and Tricks for Sling Removal



Extruded Mesh

- Typically easy to find.
 - In office easier to palpate than to see
- Small extrusion may be able to excise in office or in a few cases may resolve with topical estrogen cream
- If not – remove in OR under sedation or general

Transvaginal Prolapse Mesh Extrusion

- Occurs 2-15% depending on series
- Only treat if symptomatic
- Some very small cases may be managed in office
 - Often recur
- Typically need removal in OR
 - Ideal to not only remove exposed area but another cm around to ensure no mesh under closure

- 72 yo woman sp anterior mesh 2 years earlier
- Experiencing vaginal discharge
- Dyspareunia (partner feels something scratchy)

Mesh Excision



- Performed as outpatient procedure under general anesthesia
- Excellent healing
- Mild prolapse recurrence

Key Points

- Excise any poor vaginal skin
- Excise a bit more mesh than what is exposed
- During dissection of mesh from bladder – always work the bladder off of the mesh – stay right on the mesh

Mesh Bladder Perforation

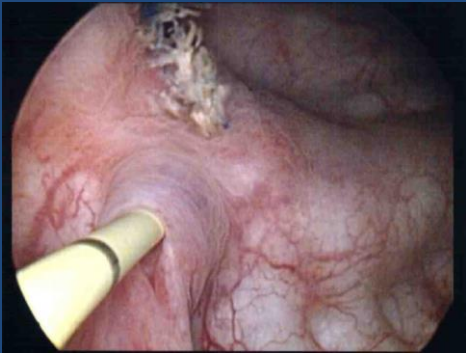
- Mesh can end up in bladder
- Arm
 - ? Arm passed through bladder and not noted
- Body of mesh
 - Bladder entered and not noted
 - Bladder wall extremely thin

- Endoscopic removal – scissors/laser/etc
 - Must get deep to epithelium
 - Often requires multiple procedures
- Transvesical removal
- Transabdominal removal
- Transvaginal removal

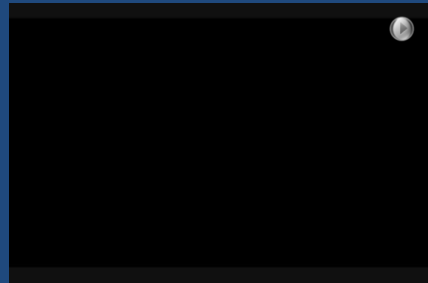
Arm in Bladder

- My preference:
- If on lower half of bladder – transvaginal removal
- If on upper (anterior) half of bladder – transabdominal approach

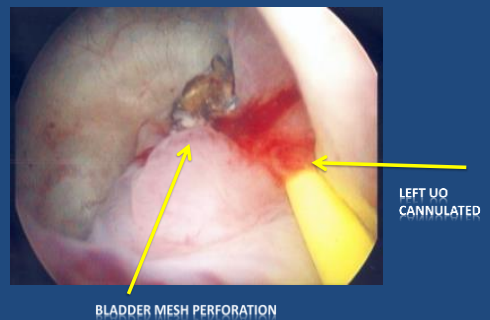
- Pt 3 years sp anterior prolapse mesh
- Recurrent utis and OAB
- Arm passing through bladder and lasered
- Not able to get it all



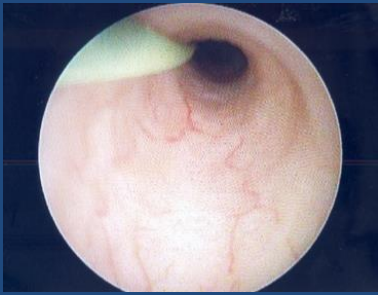Transvaginal Removal Mesh Arm From Bladder



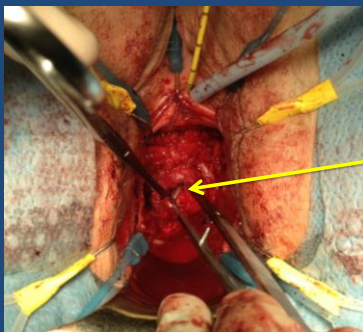
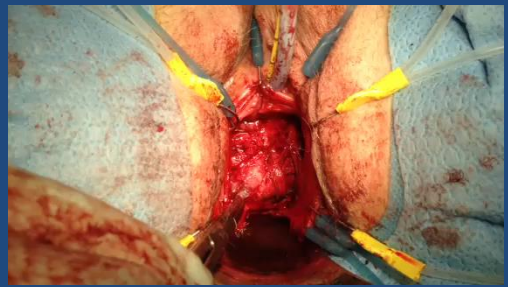
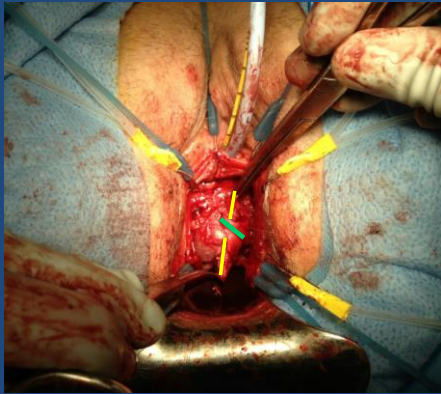
- Patient with OAB, UTIs, microhematuria



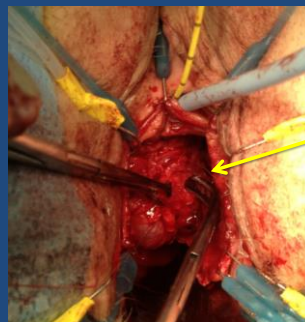
Ureteroscopy



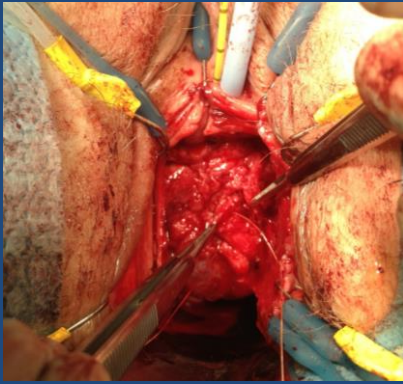
- Raised C flap starting at mesh extrusion
- Dissected out arm entering bladder medially
- Found lateral portion of arm perforating obturator internus muscle and traced back to bladder



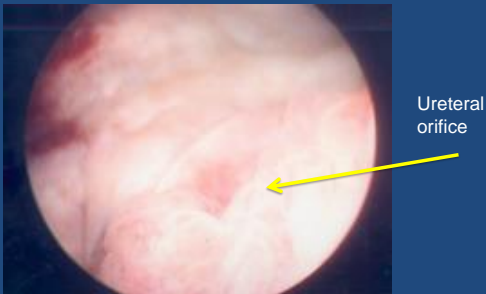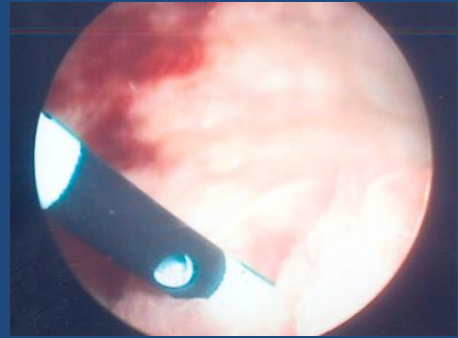
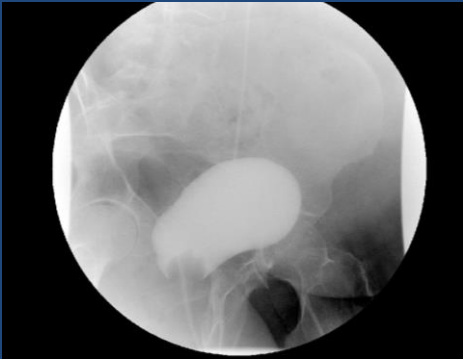Medial cystotomy



Lateral cystotomy



- Bladder closed in two layers with 2-0 vicryl
- Anterior vaginal wall closed with 2-0 vicryl
- Open ended catheter exchanged for stent
- Catheter left in place for two weeks



- Foley x 14 days
- Stent removed at same time
- Resolution of symptoms

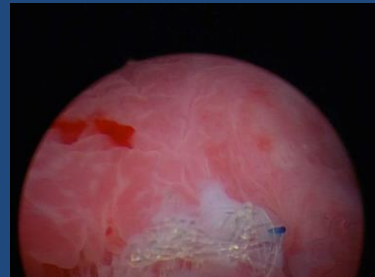
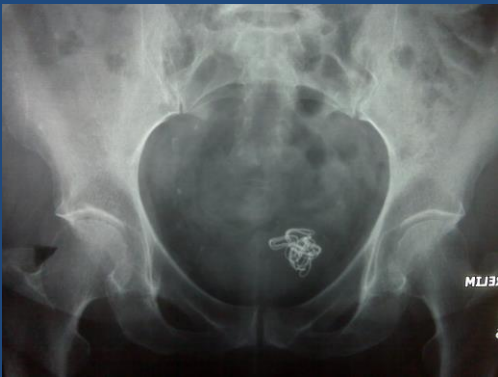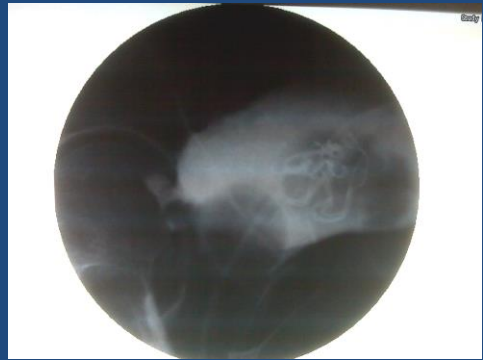Single Port Lap Mesh Arm Removal from Bladder

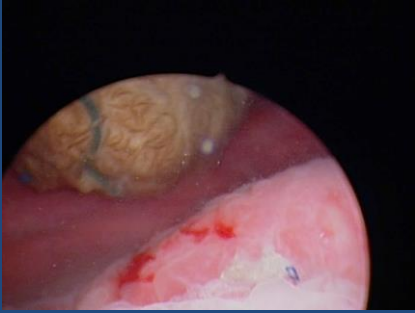Transvaginal Removal Mesh From Bladder

- 74 yo female with history of POP and SUI s/p Prolift anterior repair and TVT secure
- Initially did well, however, after approximately 4 weeks went on to develop recurrent UTIs
- Pt then developed severe continuous incontinence, requiring Foley catheter placement.

Physical Exam

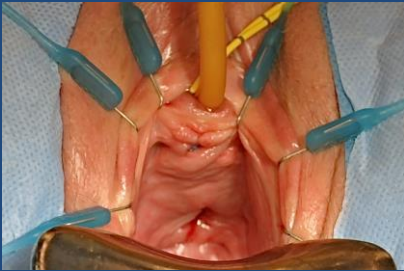
- Abd – soft, NT/ND
- GU
 - Bladder non-palpable without masses/tenderness.
 - Cystocele:none
 - Rectocele:Stage I
 - Small area of extrusion of mesh in midline near apex



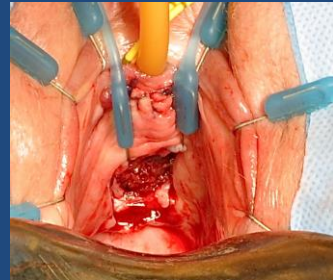


Management Options ??

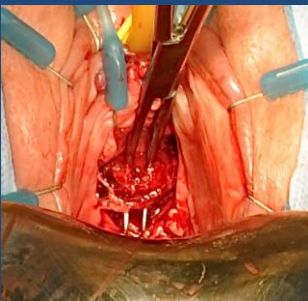Pre-op View



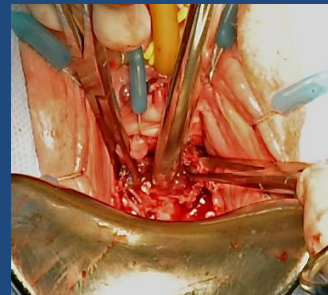
U-Flap with Mesh Exposed

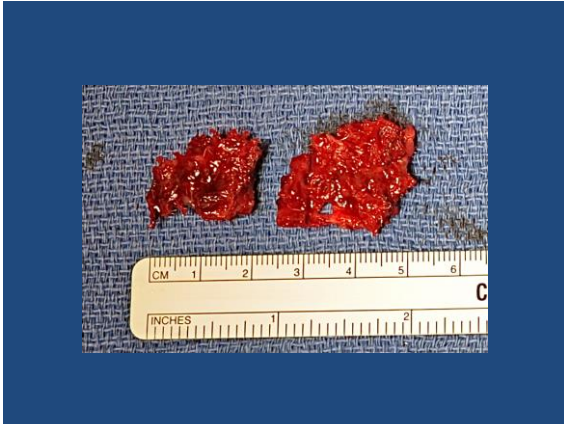

Incision in Midline of Mesh

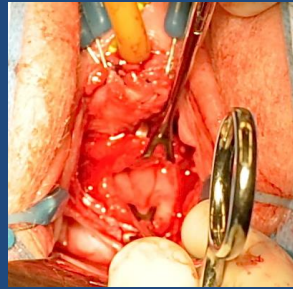


Vesicovaginal Fistula

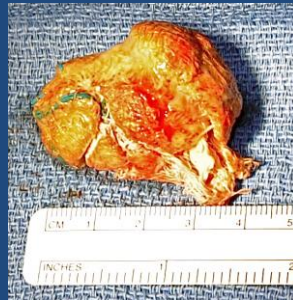
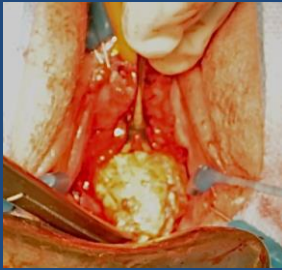




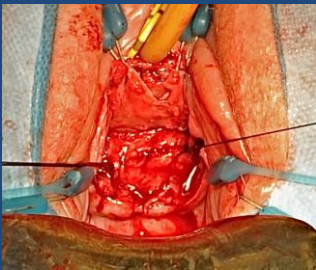
Cystotomy



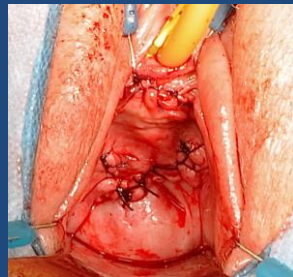
Removal of Surgical Sponge



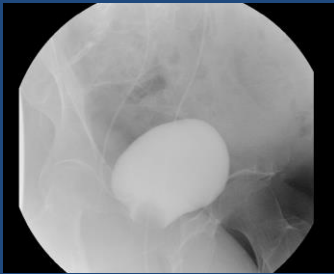
Closure of Bladder Wall



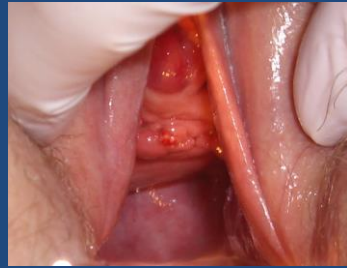Closure of Vaginal Wall



Post-op Cystogram



6 Weeks Post-op



Postoperative Course

- Discharged home in 20 hours
- Cystogram negative at 3 weeks
 - Foley catheter and JJ ureteral stents removed at 3 weeks post-op
- Patient has had resolution of VVF. No recent UTIs approximately 6 weeks post-op. In general, back to normal functional status


Key Points

- Base of vaginal wall flap should be at site of mesh perforation
- Find mesh/arm outside of bladder and then follow it in and then out of bladder
- Make sure no mesh left anywhere near bladder mucosa

Severe Urethral Damage

- Problems with slings can also lead to severe urethral injury
- More likely – difficulties when operating to remove intraurethral sling can lead to severe urethral damage

Urethrovaginal Fistula

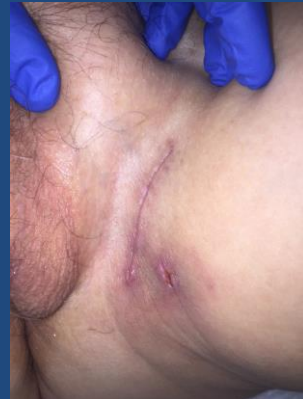


Complete Urethral Destruction



Thigh Pain due to TOT arm

- 5% of patients will have thigh pain after TOT
 - Majority will resolve spontaneously
 - Small percentage can become chronic and in some cases debilitating
- If conservative management and removal of vaginal portion does not help removal of thigh portion can provide substantial benefit



Results

Baseline Preoperative Characteristics	
Age at time of thigh dissection, mean years (SD)	53.6 (9.2)
Time from original mesh placement to presentation, mean years (SD)	2.7 (1.5)
Time from original mesh placement to excision, mean years (SD)	3.4 (1.9)
Time from first appt to excision, mean months (SD)	8.4 (9.9)
Original type of mesh placed	
TOT sling alone, total	7
TOT and anterior mesh, total	1
Types of TOT slings placed	
Inside out	2
Outside in	4
Unknown	3
Prior mesh excisions, total	
Entire transvaginal portion	2
Partial excision	2
Unknown	1
Number of prior surgeries, mean (range)	0.875 (0-3)

Results

- Mean response on GRA: 1.6 (0.7)
- All patients noted improvement

Check the number that best describes how your post-operative condition is now, compared with how it was before you had the surgery	
1.	Very much better
2.	Much better
3.	A little better
4.	No change
5.	A little worse
6.	Much worse
7.	Very much worse

Complications

- 2 wound complications
 - 1 cellulitis treated with antibiotics
 - 1 seroma required drainage

Outcomes

- 1 patient had TVT placed for recurrent SUI
- 3 patients went on to have contralateral thigh dissection

Conclusions

- Sling and mesh complications can be avoided
 - If they happen, identify issue
- If you are not comfortable managing them, consider referral to someone who is... more damage can occur if not appropriately managed
- If identified and treated appropriately majority will have significant relief