



## Approaches to Pelvic Organ Prolapse Surgery

W30, 16 October 2012 09:00 - 12:00

Start	End	Topic	Speakers
09:00	09:30	Goals of repair and anatomic principles	<ul style="list-style-type: none"> <li>• Jacqueline Cunkelman</li> </ul>
09:30	10:00	Vaginal repair for POP with films	<ul style="list-style-type: none"> <li>• Philippe Zimmern</li> </ul>
10:00	10:30	Laparoscopic repair and use of mesh	<ul style="list-style-type: none"> <li>• Jacqueline Cunkelman</li> </ul>
10:30	11:00	Break	None
11:00	11:20	Robotic repair with films	<ul style="list-style-type: none"> <li>• Philippe Zimmern</li> </ul>
11:20	11:40	Assessment of outcomes	<ul style="list-style-type: none"> <li>• Jacqueline Cunkelman</li> </ul>
11:40	12:00	Case discussion with audience	<ul style="list-style-type: none"> <li>• Philippe Zimmern</li> </ul>

### **Aims of course/workshop**

This course is intended to update the reconstructive pelvic surgeon and all interested trainees on the pros and cons of modern surgical approaches in the management of pelvic organ prolapse. This interactive course will feature concise lectures on current debates with each approach, including robotic surgery. The course will include multiple surgical video clips, and provocative case discussions to enhance the interaction with the audience.

### **Educational Objectives**

At the request of SUFU and in tribute to Rodney Appell, this program was organized four years ago and presented yearly since then, including in Glasgow at the last ICS meeting. Attendance in Glasgow was outstanding, with far more delegates present than anticipated. The feedback from the attendees was very strong. Some wanted a syllabus on the premises but it is not ICS policy anymore to do so. Others wanted more surgical videos than currently featured in the program. This request will be incorporated in this revised program for Beijing. Speakers had good scores and the meeting ended on time. After reviewing this information, our group asked SUFU permission to re-submit an application for next year's ICS meeting in Beijing. We were given clearance to do so just recently.

## **Approaches to Pelvic Organ Prolapse Surgery: Course Notes**

**Jacqueline A. Cunkelman MD, MPH**

### ***Goals of Repair***

The goals of any repair for pelvic organ prolapse include the restoration of normal anatomy, elimination of symptoms, and improvement in quality of life. Ideally, these goals are achieved with minimal complications and a short time to recovery and resumption of routine activities.

While surgeons often place higher value on the achievement of the first goal, patients may be more concerned with the latter goals. In 2001, the US NIH (National Institutes of Health) formulated objective definitions of surgical success(1):

- “Optimal”—ICS Stage 0
- “Satisfactory”—ICS Stage 1
- “Unsatisfactory”—ICS Stage 2 or greater

There is evidence that achievement of a POP-Q stage of 0 is not necessary for patient satisfaction with surgical repair or for the patient to perceive that their surgery was “successful” (2), as symptoms do not always correlate with anatomic landmarks(3-5).

Pelvic organ prolapse may be corrected using a variety of surgical techniques through either the vaginal or abdominal route and using either an open or a minimally invasive technique:

- Colpocleisis
- Vaginal uterosacral suspension
- Sacrospinous ligament suspension
- Vaginal mesh repair
- Sacrocolpopexy

The “best” technique is unique to each individual surgeon/patient and depends upon:

- Surgeon knowledge of and comfort with each procedure
- The patient’s anatomy and past medical/surgical history
- Patient defined goals for surgery
- What outcomes are meaningful to the patient and the value placed upon the avoidance of potential complications associated with each procedure

Patient perception of successful surgery and satisfaction with surgical outcome correlates strongly with achievement of patient defined pre-operative goals (6-8). Conversely, satisfaction with surgery is inversely correlated to feeling “unprepared” for surgery, the perception that there were complications with the surgery or post-operative recovery (regardless of whether there actually were complications), and the development of new symptoms not noted prior to surgery (OAB)(7, 8). Regardless of what route or surgical technique is chosen, surgical counseling must be a dialogue that helps the surgeon to understand the patient’s goals and values as they relate to the surgery and sets realistic patient expectations of what the surgery will accomplish.

### ***Anatomic Principles***

Normal pelvic support is provided primarily by the pelvic floor muscles which work in conjunction with connective tissue (endopelvic fascia) attachments. The connective tissue attachments stabilize the position of the pelvic organs so that they may receive optimal support from the muscles. The endopelvic fascia, though one continuous unit, is not a homogenous tissue type—histologically it consists of collagen, elastin, adipose tissue, nerves, vessels, lymph channels, and smooth muscle.

In 1992, DeLancey described the levels of connective tissue stabilization of the vagina(9). His findings, which are based upon cadaveric dissections, have been corroborated and further delineated by others.

- *Level I (suspension)*—the uterus, cervix, and upper portion of the vagina are suspended by the uterosacral and cardinal ligaments which attach laterally and posteriorly. The fibers of the cardinal and uterosacral ligaments intermingle. The fibers of the cardinal ligaments travel laterally (predominantly) and while the fibers of the uterosacral ligaments travel posteriorly to the sacrum. The uterosacral/cardinal ligament complex attaches the upper vagina, cervix, and lower uterine segment to the pelvic sidewalls at the piriformis, coccygeus, levator ani and, potentially, the obturator internus fascia.
- *Level II (attachment)*—the paravaginal attachments to the mid-vagina maintain the midline position of the vagina. They attach to the arcus tendineus fasciae pelvis (the “white line”) anteriorly and the arcus tendineus rectovaginalis posteriorly.
- *Level III (fusion)*—at the level of the introitus, the vagina blends and fuses with the urethra anteriorly and fuses with the levator ani muscles (laterally) and the perineal body (posteriorly).

The endopelvic fascia is continuous, thus the levels of support are interdependent. Together, all three levels maintain a horizontal position of the vagina, bladder, and rectum over the levator plate and pelvic floor muscles. This horizontal position counters the intra-abdominal and gravitational forces which are applied perpendicularly. Acute stress (Valsalva) may be countered by contraction of the pelvic floor muscles, thus protecting the endopelvic fascia from undue stress. Injury to the pelvic floor muscles shifts the work of support to the endopelvic fascia which may stretch, attenuate, or break over time. The result is pelvic organ prolapse.

### **References**

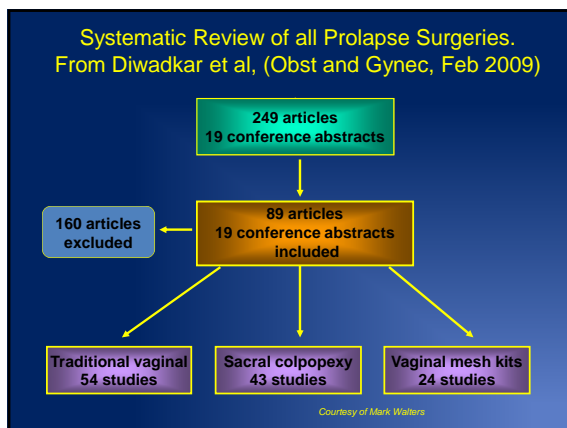
1. Weber AM, Abrams P, Brubaker L, Cundiff G, Davis G, Dmochowski RR, et al. The standardization of terminology for researchers in female pelvic floor disorders. *Int Urogynecol J Pelvic Floor Dysfunct.* 2001;12(3):178-86.
2. Barber MD, Brubaker L, Nygaard I, Wheeler TL, 2nd, Schaffer J, Chen Z, et al. Defining success after surgery for pelvic organ prolapse. *Obstet Gynecol.* 2009 Sep;114(3):600-9.
3. Bradley CS, Nygaard IE. Vaginal wall descensus and pelvic floor symptoms in older women. *Obstet Gynecol.* 2005 Oct;106(4):759-66.
4. Ellerkmann RM, Cundiff GW, Melick CF, Nihira MA, Leffler K, Bent AE. Correlation of symptoms with location and severity of pelvic organ prolapse. *Am J Obstet Gynecol.* 2001 Dec;185(6):1332,7; discussion 1337-8.
5. Swift SE, Tate SB, Nicholas J. Correlation of symptoms with degree of pelvic organ support in a general population of women: What is pelvic organ prolapse? *Am J Obstet Gynecol.* 2003 Aug;189(2):372,7; discussion 377-9.
6. Hullfish KL, Bovbjerg VE, Steers WD. Patient-centered goals for pelvic floor dysfunction surgery: Long-term follow-up. *Am J Obstet Gynecol.* 2004 Jul;191(1):201-5.
7. Elkadry EA, Kenton KS, FitzGerald MP, Shott S, Brubaker L. Patient-selected goals: A new perspective on surgical outcome. *Am J Obstet Gynecol.* 2003 Dec;189(6):1551,7; discussion 1557-8.
8. Mahajan ST, Elkadry EA, Kenton KS, Shott S, Brubaker L. Patient-centered surgical outcomes: The impact of goal achievement and urge incontinence on patient satisfaction one year after surgery. *Am J Obstet Gynecol.* 2006 Mar;194(3):722-8.
9. DeLancey JO. Anatomic aspects of vaginal eversion after hysterectomy. *Am J Obstet Gynecol.* 1992 Jun;166(6 Pt 1):1717,24; discussion 1724-8.

## Traditional Anterior, Posterior, and Apical Compartment Repairs

Sandip Vasavada, MD  
 Center for Female Urology and Pelvic Reconstructive Surgery  
 The Glickman Urological and Kidney Institute  
 The Cleveland Clinic

### “Traditional repairs vs Augmented repairs”

- Should we abandon “traditional repairs”?
- If no, then what situations to use
  - First time occurrence of prolapse
  - Thin tissues/ atrophic
  - Sexually active patients?
- Constant need to “innovate” or “keep up”
- Is this because traditional repairs are doomed to failure.....



### Results of Traditional Vaginal Repairs

Diwadkar et al 2009.

- 7827 patients
- Longest mean follow-up of 32.6 months
- Most common complications:
  - Urinary tract infection 3.5%
  - Hemorrhage or hematoma 2.8%
  - Dyspareunia 1.5%

### Results of Sacral Colpopexy

- 5639 patients
- Mean follow-up of 26.5 months
- Most common complications:
  - Pain 2.3%
  - Mesh erosion 2.2%
  - Visceral injury 1.7%
  - Wound complications 1.5%

### Results of Vaginal Mesh Kits

- 3425 patients
- Mean follow-up of 17.1 months
- Most common complications:
  - Mesh erosion or infection 5.8%
  - Fistulas 0.2%
  - Dyspareunia 2.2%

	Traditional Vaginal Repairs			Sacral Colpopexy			Mesh Kits		
	%	95% CI	Range	%	95% CI	Range	%	95% CI	Range
Total complication rate	15.3	14.7-16.3	0-52.8	17.1	16.1-18.1	0-52.2	14.5	13.3-15.7	0-23.1
Reoperation for prolapse recurrence	3.9	3.5-4.4	0-29.1	2.3	1.9-2.7	0-31.3	1.3	1.0-1.7	0-16.0
Total reoperation rate	5.8	5.3-6.3	0-29.2	7.1	6.4-7.8	0-26.2	8.5	7.6-9.4	0-30.0

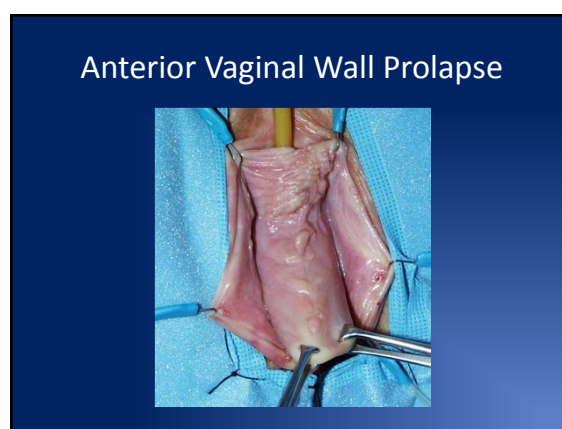
	Traditional Vaginal Repairs			Sacral Colpopexy			Mesh Kits		
	%	95% CI	Range	%	95% CI	Range	%	95% CI	Range
Total complication rate	15.3	14.7-16.3	0-52.8	17.1	16.1-18.1	0-52.2	14.5	13.3-15.7	0-23.1
Reoperation for prolapse recurrence	3.9	3.5-4.4	0-29.1	2.3	1.9-2.7	0-31.3	1.3	1.0-1.7	0-16.0
Total reoperation rate	5.8	5.3-6.3	0-29.2	7.1	6.4-7.8	0-26.2	8.5	7.6-9.4	0-30.0

Complication Grade By Repair Group

	Traditional Vaginal Repairs		Sacral Colpopexy		Mesh Kits	
	%	95% CI	%	95% CI	%	95% CI
Dindo Grade I	6.2	5.7-6.7	5.5	4.9-6.1	3.9	3.3-4.6
Dindo Grade II	6.9	6.4-7.6	5.8	5.2-6.4	2.2	1.7-2.7
Dindo Grade IIIa	0.2	0.1-0.4	1.0	0.7-1.2	1.3	0.9-1.6
Dindo Grade IIIb	1.9	1.7-2.3	4.8	4.2-5.4	7.2	6.3-8.0

- ### Conclusions of Review
- Traditional vaginal procedures
    - Highest reoperation rate for prolapse recurrence
    - Lowest rates of complications that required surgical intervention
    - Lowest total reoperation rate
  - Vaginal mesh kits
    - Shortest follow-up period
    - Highest rate of complications that required surgical intervention
    - Highest total reoperation rate (recurrence + complications)

- ### Challenges in Vaginal Prolapse Surgery
- Anterior Vaginal Wall Prolapse
  - Apical Prolapse
    - At time of hysterectomy
    - Post-hysterectomy
  - Posterior Vaginal Wall Prolapse

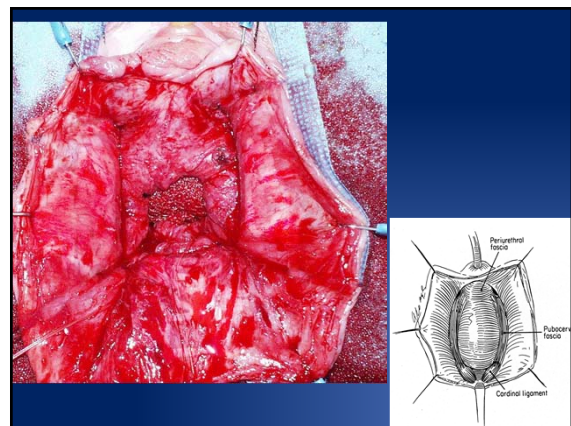
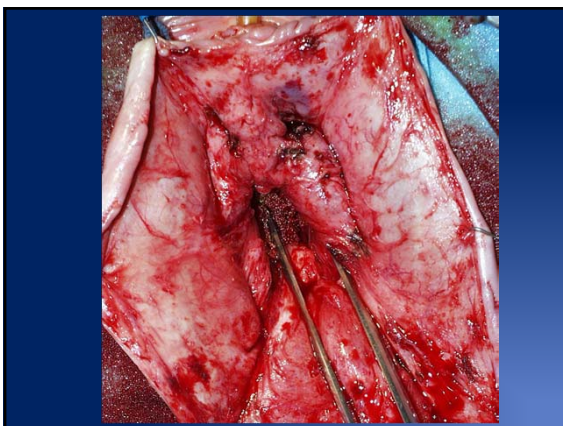
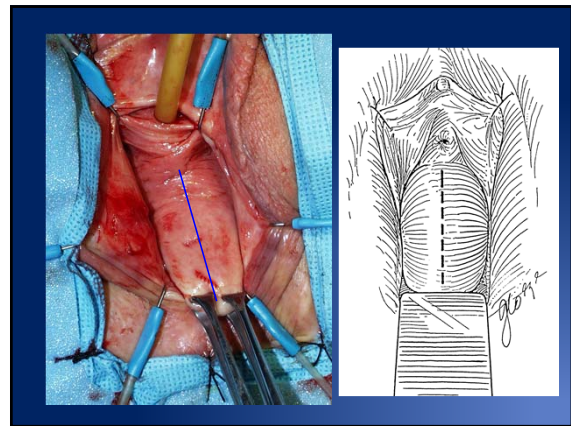
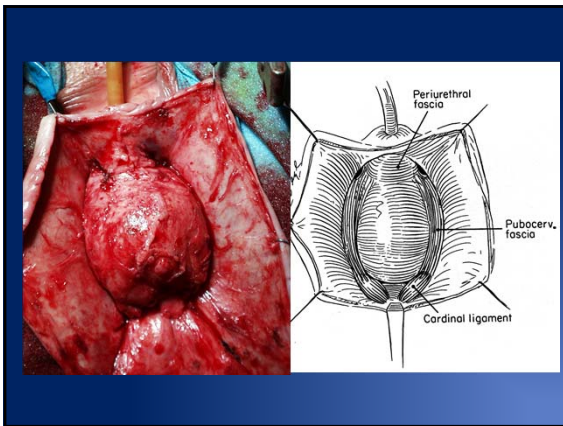


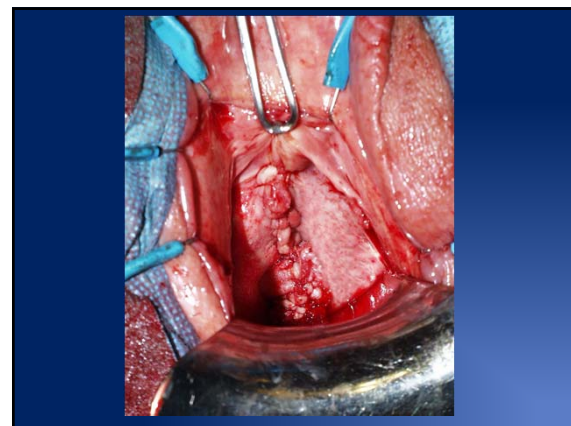
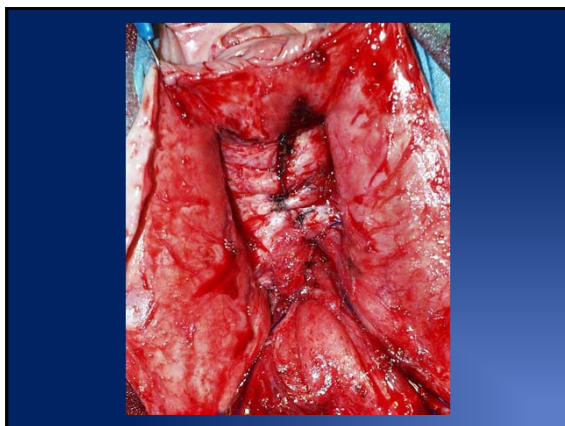
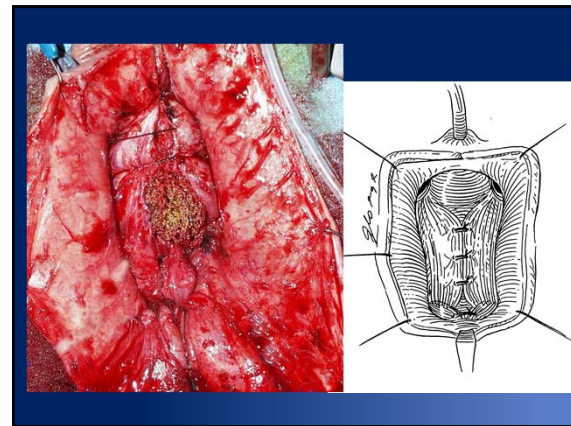
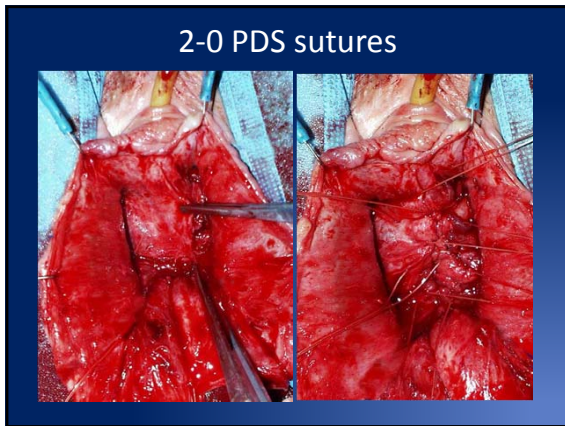
### Four Defects of Anterior Vaginal Wall Prolapse

- **Repair of central defect**
  - re-approximation of widened pubocervical fascia
- **Repair of lateral defect**
  - Suspension/support of bladder base and apex
- **Urethra and BN support**
  - vaginal sling (if necessary), same or separate incision
- **Cardinal ligament repair/ Bladder base/ Apex**
  - dissection and approximation to midline

### Anterior Vaginal Wall Prolapse

- **Identify and correct all defects**
- **Evaluate potential other coexistent defects of pelvic organ support (e.g enterocele, rectocele, vault mobility)**
- **Assess and address potential urethral incompetence**
- **? Patch augmentation of repairs**





### Anterior Colporrhaphy+/- Absorbable Mesh

- Weber, AM, Walters, MD, Piedmonte, MR, Ballard, LA (Am J Obstet Gyn 2001)
  - 109/114 patients underwent ant colporrhaphy 3 techniques
    - Standard
    - Standard + mesh (polyglactin)
    - Ultralateral colporrhaphy
  - Evaluated by POP-Q
  - Median follow up was 23.3 months
  - 7% stage I preop, 37% stage II preop, 54% stage III preop, 2% stage IV
  - 30% satisfactory outcomes after standard colporrhaphy alone, 42% standard + mesh, and 46% ultralateral colporrhaphy
  - VAS: symptom severity improved overall (6.0 +/- 2.7 → 1.1 +/- 0.8)
  - **Addition of mesh did not seem to make a difference**

### Anterior Colporrhaphy

- Sand, PK et al. (Am J Obstet Gyn, June 2001)
  - Prospective randomized trial of stage 2 < cystocele with and without vicryl mesh
  - Follow up at 2,6,12,52 weeks postop
  - 80 with mesh, 80 none
  - Technique: mesh reduction of prolapse only
  - After 1 yr, 43% patients without mesh and 25% with mesh had recurrence to mid vaginal plane (p = 0.2), concurrent slings may be protective as well
  - Mesh does make a difference



## Lateral or Paravaginal Defect

## Paravaginal Defects

- Lateral support of pubocervical fascia to condensation of obturator internus and levator fascia's (White line of arcus tendineus)
- Widespread belief that AVW prolapse patients have co-existent lateral and central defects (up to 80%)
- *If so many patients have lateral defects that are not routinely corrected, why do our central defect only repairs work most of the time ?*

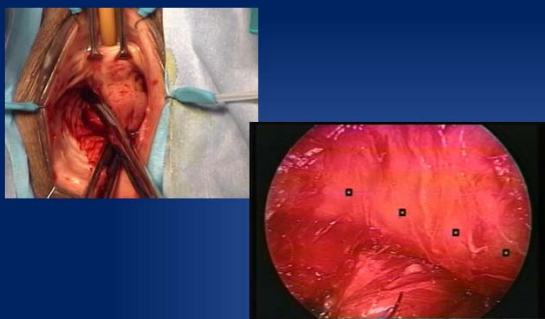
## Paravaginal Defect Retropubic repair

- Can be done open or laparoscopically
- Four to six non absorbable sutures
- Success rates good for retropubic and laparoscopic
- Minimal morbidity (aside from access route)

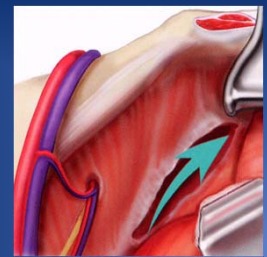
## Paravaginal Defect Correction Vaginal

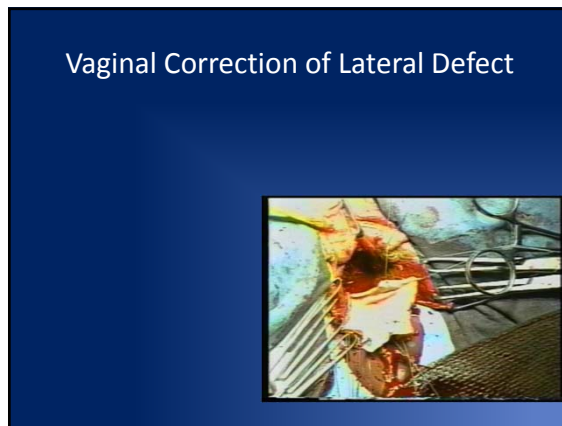
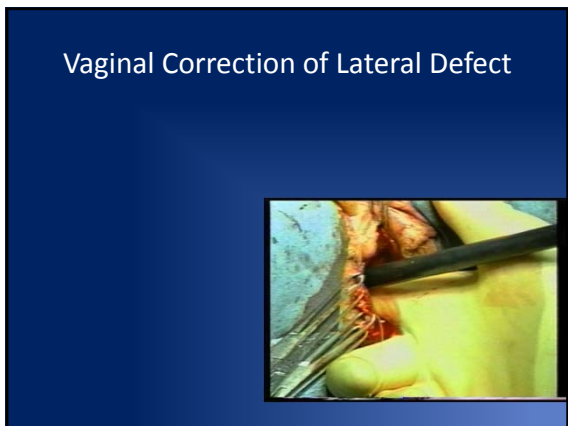
- Identify lateral defect
- Enter paravaginal space
- Re-approximate pubocervical fascia with ATPF (interrupted non absorbable sutures)

## Vaginal Correction of Lateral Defect



## Vaginal Correction of Lateral Defect





### Paravaginal Defect Repairs

Vaginal corrective repairs

Study (year)	No. of pts	Study design	Follow-up <u>range</u>		Cure * (%)	Failed (%)
			Mean	range		
White (1909) <sup>4</sup>	19	Retrospective cohort	NR	Up to 3 years	100	0
Shull et al (1994) <sup>32</sup>	62	Retrospective cohort	1.6 yrs	0.1 – 5.6 yrs	76	24
Farrell & Ling (1997) <sup>31</sup>	27	Retrospective cohort	8 mo.	NR	80	20
Nguyen & Bhatia (1999) <sup>33</sup>	10	Retrospective cohort	1 yr.	NR	100	0
Elkins et al (2000) <sup>24</sup>	25	Retrospective cohort	NR	0.5 – 3 yrs	76	24
Mallipeddi et al (2001) <sup>23</sup>	35	Retrospective cohort	20 mo.	8 – 35 mo	97	3
Young (2001) <sup>25</sup>	100	Retrospective cohort	11 mo.	1 – 36 mo.	78	22

NR – not reported

*Barber, M and Vasavada, S*

- ### Patch Augmentation for AVW Prolapse
- Poor quality tissues used for durable repair
  - High recurrent prolapse rates (29-42%)\*
  - What to do for patients with 2-3 previous failed repairs ?
  - Younger patient population: what will happen to results over time?
  - What happens to sexual function with patch?
  - “Bladder Cripples”

- ### Rationale for Patch Augmentation for AVW Prolapse
- Simultaneous Central and Lateral Defect Support
  - Reinforce weak tissues
  - Materials for augmentation
    - Autologous ?
    - Allograft (fascia, dermis): falling out of favor ?
    - Xenograft (porcine, bovine): Cross linked vs not
      - Incisional dehiscence
      - Granulation
      - encapsulation
- } ?dyspareunia
- Synthetic (prolene, soft prolene mesh, marlex, gortex, etc.)

- ### Defining success
- Some degree of loss of anatomic support is normal
  - Perfect anatomic support is associated w/ worse HRQOL (PFIQ 10pts worse for Stage 0 than Stage 1 or greater)
  - Symptomatic cure is more clinically relevant than anatomic cure
  - Definitions of anatomic success commonly used are too strict and often not clinically relevant

### What is a failure after POP surgery?

- Reoperation or retreatment?
- Complications ?
- Recurrence of symptoms?
- Anatomic recurrence
  - Stage 2+?
  - Beyond hymen?
  - Stage 3+?

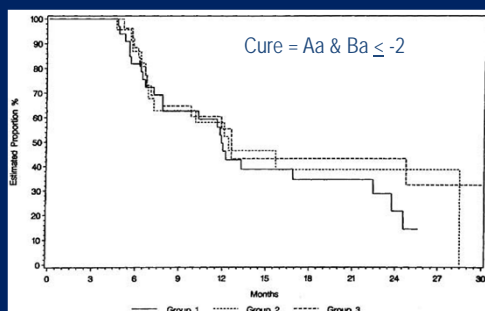
### Anterior colporrhaphy: A randomized trial of three surgical techniques

Anne M. Weber, MD, Mark D. Walters, MD, Marion R. Piedmonte, MA, and Lester A. Ballard, MD  
Cleveland, Ohio  
(Am J Obstet Gynecol 2001;185:1299-306.)

- RCT, n = 114, May 1996 – 2000
- Cure: POPQ Aa & Ba ≤ -2
- % Cure at last follow-up
  - Standard 30%
  - Standard + Polyglactin 910 mesh 42% NS
  - "Ultralateral" anterior colporrhaphy 46%
- Mean follow-up: 23.3 months (4.5 to 43 months)

*Courtesy of Matt Barber*

### Randomized Trial of 3 methods of Anterior Repair



Weber et al, AJOG 2001

### Definition of Cure

- 2001 NIH Workshop on Standardization:
  - "Optimal" anatomic outcome – Stage 0
  - "Satisfactory" anatomic outcome – Stage 1
- NIH definitions too strict
  - over 75% of women presenting for annual exams would not meet "optimal" definition and 40% would not meet the "satisfactory" anatomic outcome definition.

Weber et al, IUG 2001

Swift et al, AJOG 2000  
Swift et al, AJOG 2005  
Trowbridge et al, AJOG 2008

### Definition of Cure

- The hymen is an important threshold for symptom development.
- The pelvic symptom that best correlates with advanced prolapse is a vaginal bulge that can be seen or felt.
- The absence of vaginal bulge symptoms postoperatively has a significant relationship with a patients assessment of treatment success and HRQOL while anatomic success alone does not.

Swift et al, 2000  
Tan et al, 2005  
Bradley et al, 2005  
Barber et al, 2010

### NIH Pelvic Floor Disorders Network Recommendation

#### Success after POP surgery:

- No prolapse beyond the hymen (Aa, Ba, C, Ap, Bp ≤ 0)
- No vaginal bulge symptoms and
- No retreatment

Barber et al, Obstet Gynecol 2010

### Objective

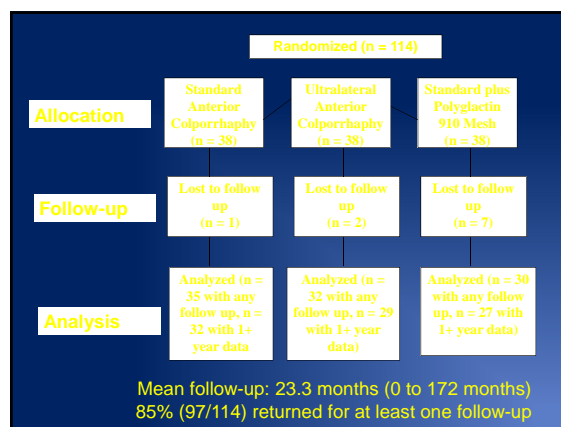
Reanalyze the results of the trial by Weber et al comparing three techniques for surgical correction of anterior vaginal prolapse using more clinically relevant definitions anatomic and symptomatic prolapse recurrence.

### Methods

- Re-analysis of trial by Weber et al
- 114 subjects undergoing surgery for anterior vaginal prolapse randomized (1:1:1) to one of three techniques
- Exclusions: any planned incontinence procedure other than suburethral plication.
- Pre- and Post-operative data abstracted from original case report forms.
- Follow-up at 6, 12, 24 months:
  - POPQ exam by blinded examiner
  - Symptom questionnaires (VAS)

### Methods

- Prolapse VAS : “How much are you bothered by symptoms related to vaginal prolapse” (0 “not at all” – 100 “extremely”)
- Treatment success:
  - POPQ Ba, Bp, C ≤ 0 cm
  - Absence of prolapse symptoms (VAS < 20)
  - No retreatment



### Concurrent Surgery

- TVH 53%
- Posterior colporrhaphy 94%
- Enterocele repair 26%
- Vaginal vault suspension 44%

### Outcomes at one year

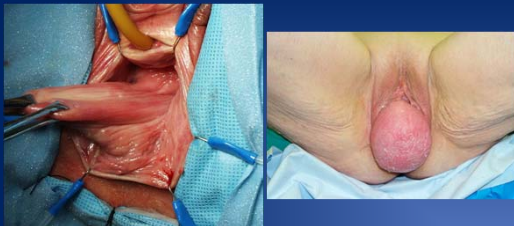	Standard	Ultralateral	Mesh	Overall
Median POPQ value (range)				
Ba	-1.5 (-3 to +1)	-1.3 (-3 to +4)	-1 (-3 to +2)	-1 (-3 to 4)
C	-6 (-9 to +1)	-6 (-10 to +4)	-6 (-7.5 to -2)	-6 (-10 to 4)
Bp	-3 (-3 to +1)	-2.5 (-3 to +4)	-3 (-3 to 0)	-3 (-3 to 4)
No prolapse beyond the hymen	25/28 (89%)	22/26 (85%)	22/23 (96%)	69/77 (90%)
Absence of POP Symptoms	32/32 (100%)	27/29 (93%)	21/23 (91%)	80/84 (95%)
No reoperations for POP	32/32 (100%)	29/29 (100%)	27/27 (100%)	88/88 (100%)
No prolapse beyond hymen, no symptoms, no retreatment	25/28 (89%)	21/27 (78%)	21/23 (91%)	67/78 (86%)

### Conclusions

- The success rate of anterior colporrhaphy varies considerably depending upon the definition of treatment success used.
- When strict anatomic criteria are used, the success rate is low.
- When more clinically relevant criteria are used, treatment success is better with only 10% developing anatomic recurrence beyond the hymen, 5% developing symptomatic recurrence and 1% undergoing retreatment during the study follow-up.

### Vaginal Vault Suspensions

### Apical Prolapse

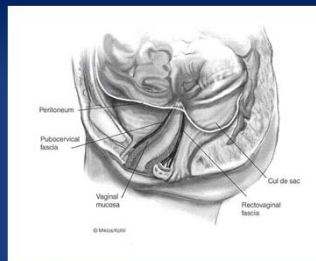


### Objectives of Vaginal Vault Surgery

- Preserve normal vaginal axis
- Minimize complication rates, blood loss, postoperative discomfort, and cost
- Repair all coexistent pelvic floor defects
- Attempt to restore
  - Vaginal anatomy
  - Visceral function
  - Sexual function
  - Quality of life

### Vaginal Vault Suspension

- Many patients with significant prolapse have vault support weakness
- Many subsequent failures due to lack of vault suspension
- Resuspension of the vault anchors the anterior/posterior repair
- Why don't many repair vault?
  - Not properly diagnosed
  - Lack of adequate training
  - Time consuming, complex procedures



Solid Support of the Vaginal Apex is the Cornerstone of a Good Vaginal Prolapse Repair

### Transvaginal Procedures for Vaginal Vault Prolapse

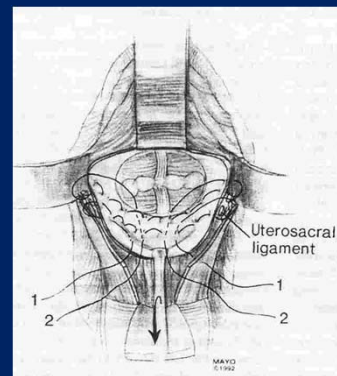
- Modified McCall's Culdoplasty
- Iliococcygeus Vaginal Vault Suspension
- Levator Myorrhaphy
- High Uterosacral Vaginal Vault Suspension (USVVS)
- Total Vaginal Mesh Apical Suspension
- Colpocleisis

### Abdominal Repairs for Vaginal Vault Prolapse

- Open Abdominal Sacrocolpopexy
- Open Uterosacral Ligament Suspension
- Laparoscopic Abdominal Sacrocolpopexy
- Robotic Sacrocolpopexy

### Mayo/McCall culdoplasty

- Elevation of vaginal apex to high uterosacral ligament
- Proven efficacy in enterocele repair
- Wide experience in specific centers
- Reported high success rates
- Usefulness in complete prolapse in question



### Mayo Culdoplasty

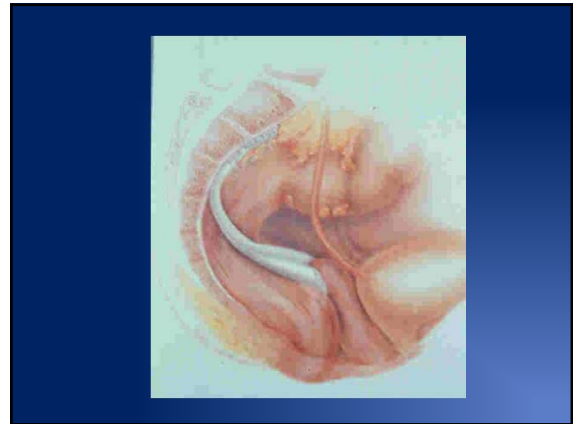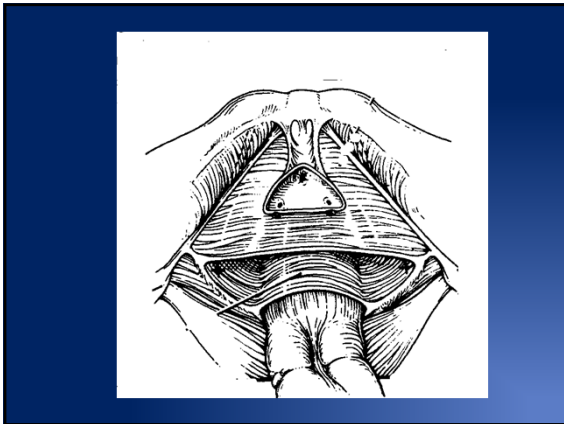
- 660 patients, posthysterectomy vault prolapse (TVH - 43%, TAH - 49%)
- questionnaire and/or telephone contact
- follow-up 11-22 yrs.
- satisfaction - 82%
- complications: bladder/bowel entry (2.3%), ureteral damage (0.6%), hematoma (1.3%)
- subsequent repairs - 5.2% none - 71%
- "bulge" - 11.5% none - 61.2%

Webb, Aronson, Ferguson, Lee. Obstet Gynecol 1998;92:281-5.

### Iliococcygeus suspension

- Transmucosal sutures placed to coccygeus fascia, bilaterally
  - inferior to white line, anterior to ischial spine
- Reported success rates similar to sacrospinous fixation
- Simplicity and decreased morbidity
- May allow for only 6-7 cm depth

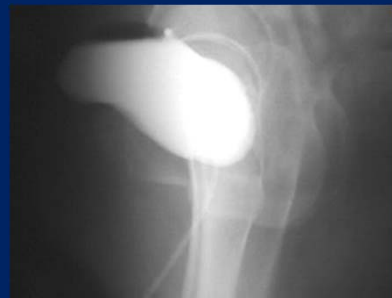Shull, et al. Am J Obstet Gynecol 1993;168:1669-77.  
 Meeks, et al. Am J Obstet Gynecol 1994;171:1444-54.  
 Peters, et al. Am J Obstet Gynecol 1995;172:1894-902.  
 Maher, Dwyer, et al. Obstet Gynecol 2001;98:40-4.



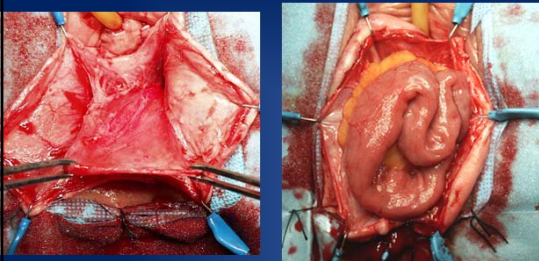
### Levator Myorrhaphy

- Transvaginal placement of sutures through levator complex and shelf towards midline to anchor upper vagina
- Similar in concept to Mayo Culdoplasty
- Uses #1 absorbable sutures thru neovaginal apex and into levator muscles bringing them towards the midline to contralateral side. Then, 2 purse string sutures to close enterocele sac

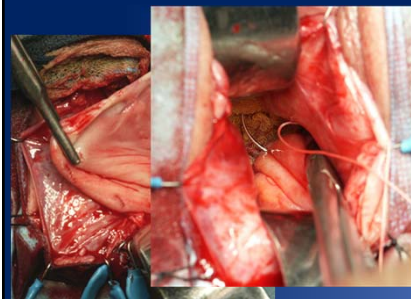
### Levator Myorrhaphy



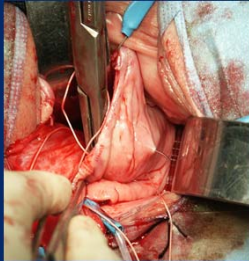
### Exposing peritoneal sac



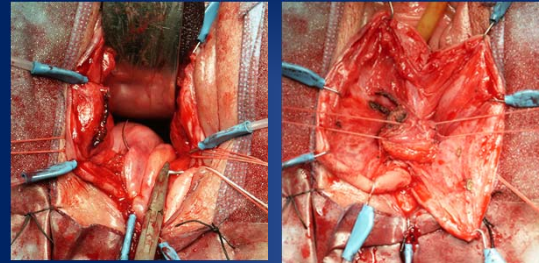
### Vault suspension sutures



Out of peritoneal sac  
1 cm from original entrance



Purse string sutures  
Pre-rectal



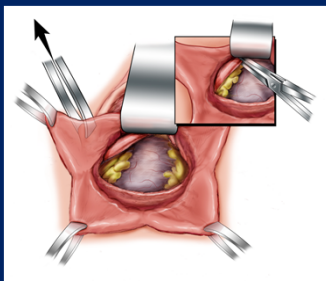
### Levator Myorrhaphy Results

- Lemack, GE et al (Eur Urol Dec 2001)
  - 35 patients (mean age 71, f/u 27.0 months)
  - 5 recurrent prolapse (3 ant enterocele, 1 vault)
  - 7/35 recurrent cystoceles (5 grade 1, 2 grade 2)
  - Satisfaction > 90% in 17/35
  - One ureteral injury

### Uterosacral Vaginal Vault Suspension

- Placement of sutures through “normal” vaginal apical suspension points
- Thought to be more physiologic suspension of apex
- Addresses level I and II support continuity
- Low, but not insignificant complication of ureteral injuries as the ligament is close to the ureters especially distally

### Uterosacral Vaginal Vault Suspension

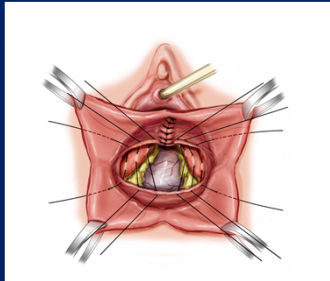


### Uterosacral Vaginal Vault Suspension

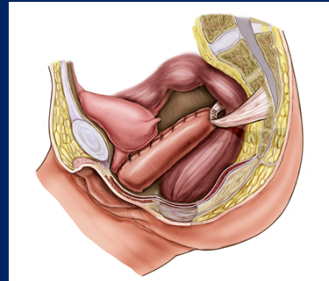




### Uterosacral VVS



### Uterosacral VVS




### Uterosacral VVS Results

First Author	Year	No.	Follow-up Months (range)	Definition of anatomic success	Anatomic success all segments	Anatomic recurrence by segment	Reoperation for POP
Jenkins	1997	50	(6-48)	Not defined	96%	Anterior 4%	None reported
Comiter	1999	100	17 (6.5-35)	Grade 0-1	96%	Apex/enterocele 4%	4 (4%)
Barber	2001	46	15.5 (3.5-40)	Stage 0/1 or asymptomatic Stage 2	90%	Apex 5% Anterior 5% Posterior 5%	3 (6.5%)
Karram	2001	168	21 (6-36)	Grade 0-1	88%	Apex 1% Anterior or posterior 11%	11 (5.5%)
Shall	2001	289	Not stated	Grade 0-1	95%	Apex 1% Anterior 3.5% Posterior 1.4%	None reported
Amundsen	2003	33	28 (6-43)	Stage 0 or 1	82%	Apex 0% Posterior 12%	None reported

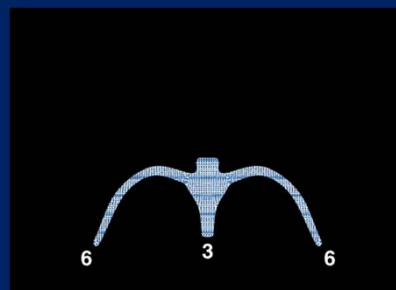
### Total Vaginal Mesh Kit Repairs

- Idea to replace components of normal anatomic structure and support of posterior vaginal wall and apex (may also include anterior vaginal wall)
- Typically done with wide pore polypropylene mesh (may use other substitutes)
- May offer more solid and reproducible points of fixation

### Total Vaginal Mesh Systems



### Total Vaginal Mesh Systems



## Potential Surgical Complications

- Perforation of bowel, vasculature and nerves
- Erosion of mesh into viscera
- Extrusion of mesh into vagina
- Infection
- Hematoma

## Managing Mesh Complications

- Resolution of mesh exposure may be done with antibiotics and estrogen cream
- Treat in office when mesh exposure is:
  - Easy to reach and near the introitus
  - Small and requires minimal excision
- Treat in OR if mesh exposure is:
  - Large and requires reapproximation of mucosa

## Surgical Tips and Pearls

- Trim the distal portion of mesh superior to the perineal body to reduce the risk of mesh extrusions
- Leave mesh loose – no tension should be applied to the mesh
  - Check tensioning before removing plastic sheaths
- A smaller incision may help minimize risk of mesh extrusion
- Minimize trimming of vaginal mucosa
  - Vaginal epithelium should contract into a normal anatomical shape within 2-4 weeks

## Vaginal Versus Abdominal Reconstructive Surgery: A Prospective Clinical Trial

- Benson et al (1996) 88 women at 2.5 years
  - Abdominal repair (38) associated with a 58% optimal surgical result and a 16% reoperation rate
  - Vaginal repair (42) associated with a 29% optimal surgical result and a 33% reoperation rate
  - Optimal defined as asymptomatic with the apex above the levator plate and no protrusion beyond the hymen while standing with maximum Valsalva

## Posterior Compartment Repairs

## Posterior Wall Prolapse

- May occur in up to 50% of patients with concomitant anterior and apical defects
- Rectocele
- Enterocele
- Sigmoidocele
- perineocele

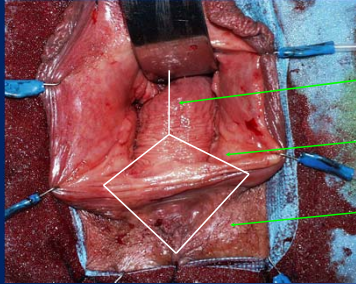
### Rectocele repairs when to do ?

- **Symptomatic**
  - Defecatory dysfunction
  - Digitation
  - Symptomatic bulge
- **Asymptomatic**
  - Size ??
  - Risks and benefits ?
    - Pain
    - Dyspareunia
- **How about at time of sacrocolpopexy ?**

### PELVIC FLOOR REPAIR Traditional

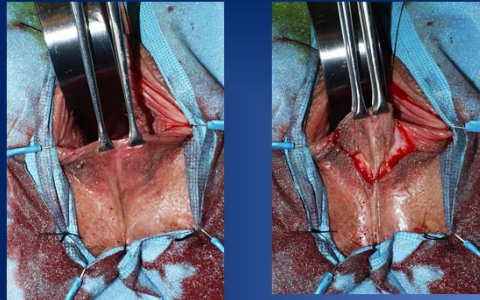
- *Rectocele repair* by plication of prerectal and pararectal fascia
- *Narrowing the levator hiatus* by approximation of levator fascia
- *Perineal repair* by approximation of bulbocavernosus, transverse perineum and anal sphincter

### Pelvic floor repair



- 3) Pre rectal incision
- 2) Vaginal triangle
- 1) Perineal triangle

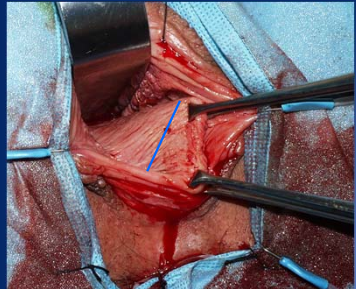
### Perineal incision



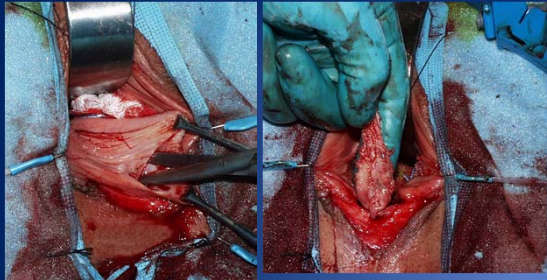
### Dissection and excision



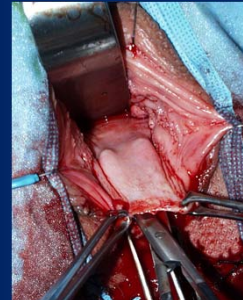
### Posterior vaginal triangle



### Dissect and excise posterior triangle



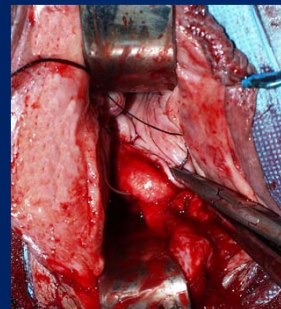
### Dissection and excision posterior vaginal wall



## PELVIC FLOOR REPAIR

- *Rectocele repair* by plication of prerectal and pararectal fascia
- *Narrowing the levator hiatus* by approximation of levator fascia
- *Perineal repair* by approximation of bulbocavernosus, transverse perineum and anal sphincter

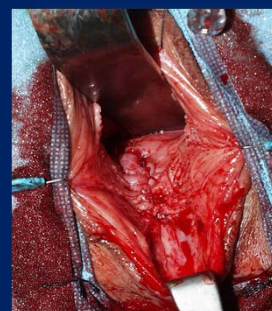
### Inclusion of pararectal and prerectal fascia

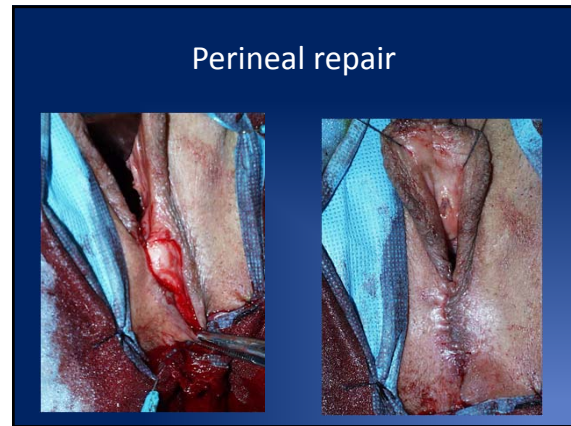
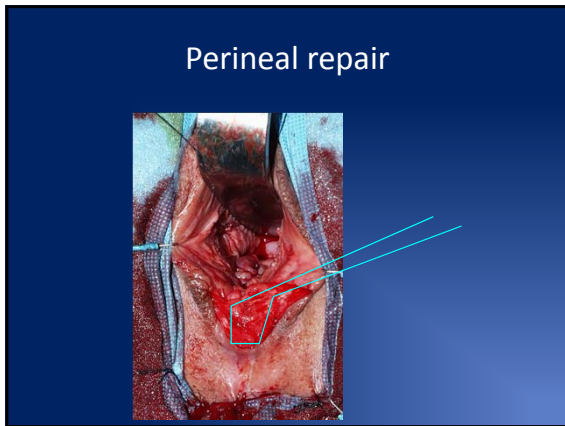


## PELVIC FLOOR REPAIR

- *Rectocele repair* by plication of prerectal and pararectal fascia
- *Narrowing the levator hiatus* by approximation of levator fascia
- *Perineal repair* by approximation of bulbocavernosus, transverse perineum and anal sphincter

### Closing levator hiatus





### Standard Posterior Colporrhaphy

Study	N	Mean Follow-up (mo)	Anatomic Cure (%)	Vaginal Digital-ation (%)	Defecatory Dysfunc-tion (%)	Fecal Inconti-nence (%)	Dyspara-unia (%)	De novo Dyspareunia in Sexually Active Patients, n (%)
McIlgren et al	25	12	96	50	100	8		2 (8)
Preoperative								
Postoperative	25			0	88	8		
Weber et al	53	12						14 (26)
Preoperative								
Postoperative	53							
Sand et al <sup>†</sup>	70	12	90					
Preoperative								
Postoperative	67							
Maher et al	38	12.5	89	100	100	3	37	1 (4)
Preoperative								
Postoperative	38			16	13	0	5	
Paraiso et al <sup>†</sup>	37	17.5	86	47	80		56	(20)
Preoperative								
Postoperative	28			32	32		45	

<sup>†</sup> Prospective studies only.  
<sup>‡</sup> Two randomized controlled trials.

### Site Specific Repairs

Study	N	Mean Follow-up (mo)	Anatomic Cure (%)	Vaginal Digital-ation (%)	Defeca-tory Dys-func-tion (%)	Fecal Inconti-nence (%)	Dyspara-unia (%)	De novo Dyspareunia in Sexually Active Patients, n (%)
Cundiff et al <sup>‡</sup>	69	12	82	39	71	13	29	1 (2)
Preoperative								
Postoperative	61			25	39	8	19	
Kentton et al <sup>‡</sup>	66	12	90	30	41	30	28	3 (7)
Preoperative								
Postoperative	46			15	57	8	8	
Peter et al <sup>‡</sup>	125	6	82	24	60	24	67	3 (4)
Preoperative								
Postoperative	72			21	50	21	46	
Alvarado et al <sup>‡</sup>	124	12	56		33	15	8	12 (11)
Preoperative								
Postoperative	124				37	19	16	
Singh et al	42	18	92		57	9	31	
Preoperative								
Postoperative	33				27	5	38	
Glovind and Maded	67	3	100		40	12	2 (3)	
Preoperative								
Postoperative	67				4	6		
Paraiso et al <sup>†</sup>	37	17.5	78	58	85	48	(14)	
Preoperative								
Postoperative	27				35	28		

<sup>‡</sup> Retrospective studies, the remainder are prospective.  
<sup>†</sup> Two randomized controlled trials.

### Graft Augmented Posterior Repairs

Study	N	Mean Follow-up (mo)	Anatomic Cure (%)	Graft Type	Defecatory Dysfunc-tion (%)	Vaginal Digital-ation (%)	De novo Dyspareunia in Sexually Active Patients, n (%)	Mesh Erosion (%)
Milani et al	63		94	Prolene	45		4 (6)	13
Preoperative								
Postoperative	63				30			
Altman et al	32	38	62	Acellular porcine dermis (Pelvicol)	100			
Preoperative								
Postoperative	23				< 50			
Sand et al <sup>†</sup>	73	12	92	Polyglactin				
Preoperative								
Postoperative	65							
Paraiso et al <sup>†</sup>	31	17.5	54	Acellular porcine small intestinal Submucosa (Fortagen)	97	51		
Preoperative								
Postoperative	26				21	7	(6)	

<sup>†</sup> Prospective studies only.  
<sup>‡</sup> Randomized controlled trial.

- ### Conclusions
- Prolapse is an ever changing field
  - Address apex if at all possible
  - Mesh use data suggests better anatomic outcomes but are they using same "success criteria"?
  - Traditional cystocele repairs probably "work" better than we give credit for
  - Use rectocele repairs as necessary but maybe tide has changed in "prophylactic repairs": use symptoms instead

## Approaches to Pelvic Organ Prolapse Surgery: Course Notes

Jacqueline A. Cunkelman MD, MPH

### *Laparoscopic Repair and the use of Mesh*

Historical evolution of approaches to apical repair:

- Early 20<sup>th</sup> century apical support consisted of
  - Vaginal: Mayo or Manchester procedure
  - Abdominal: Fixation to the anterior abdominal wall
- By the 1950's posterior vaginal apex sutured posteriorly to the sacral promontory
- Lane (1962) advocated using intervening mesh to decrease excessive tension on the vagina
- Birnbaum (1973) placed mesh lower at S3-S4 to restore natural lie of the vagina
- Sutton (1981) advocated move to S1-S2 where the middle sacral artery was better visualized and avoided
- Addison (1989) used a folded conical configuration encasing the vagina
  - Maximize the surface area of the vagina
  - Increased vaginal erosions and changed to mesh strips
- Snyder and Krantz (1991) increased the length of the mesh and extended the graft to the rectovaginal septum
- Nezhat CH (1994) Laparoscopic SCPXY 15 women
- Cundiff (1997) extends the mesh posteriorly to the perineal body by abdominal route
- Sullivan (2001) describes "total pelvic mesh repair" with great anatomic outcomes but 10% reoperation rate from complications
- Visco (2001) performs SCPXY with combined vaginal and abdominal approaches and notes more mesh erosions compared to an all-abdominal approach.

Sacrocolpopexy has become the "gold standard" for the restoration of apical support. In 1996, Benson et al randomized women to abdominal sacrocolpopexy or vaginal bilateral sacropinous ligament suspension(1). Sacrocolpopexy was associated with significantly higher cure rates and lower reoperation rates. Sacrocolpopexy fares equally well in comparison to total vaginal mesh. Two years after randomization to laparoscopic sacrocolpopexy or total vaginal mesh, women in the sacrocolpopexy group had higher rates of satisfaction and objective surgical success and lower rates of perioperative morbidity and reoperation(2).

As sacrocolpopexy technique has evolved, we have learned important lessons for optimizing the surgical process and patient outcomes(3).

1. Use some type of graft, rather than directly affixing the vagina or the uterus to the sacrum
2. Avoid excessive tension on the anterior vaginal graft to minimize the risk of stress urinary incontinence

3. Decrease the risk of massive presacral hemorrhage by placing sutures through the anterior longitudinal ligament closer to the promontory, rather than at S3-4
4. Avoid playing layers of synthetic graft material on a denuded vaginal apex
5. Place sutures over the vaginal portion of the graft to spread out tension, rather than simple fixation at the apex

Increasing numbers of surgeons and patients choose minimally invasive sacrocolpopexy to combine the benefits of abdominally placed mesh with shorter recovery time associated with minimally invasive surgery. Laparoscopic surgery offers several advantages over open abdominal or vaginal approaches:

- Better visualization of anatomy due to magnification
- Decreased blood loss
- Shorter hospital stay
- Decreased pain
- Improved cosmesis

These must be balanced against the disadvantages:

- Steep learning curve—suturing skills
- More technically difficult retroperitoneal dissection
- Increased operating time
- Increased cost—longer OR time, disposable instruments

Some of the disadvantages are minimized as surgeons become more skilled in laparoscopic technique. One paper, which reviewed over 1000 laparoscopic sacrocolpopexies from 11 case series, reported that operative times and conversion to open procedures decreased with increased surgeon experience(4). Mean operative time ranged from 96 to 286 minutes with a nearly 3% conversion rate.

The use of the robot in sacrocolpopexy has helped to overcome some of the technical difficulties of laparoscopy, including the steep learning curve and ergonomic difficulties, at a significant cost and without clear benefit to the patient. Direct comparisons of laparoscopic and robotic sacrocolpopexy are limited due to the newness of the technology, however several RCTs do exist. Paraiso et al randomized 78 women with post-hysterectomy vault prolapse to a robotic or laparoscopic approach(5). The primary outcome was total operative time while secondary outcomes were postoperative pain, functional activity, bowel and bladder symptoms, quality of life, anatomic vaginal support, and cost from a health care system perspective. Robotic-assisted surgery was associated with a longer total operative time (67 minutes), as well as longer anesthesia time, total time in the operating room, total sacrocolpopexy time,

and total suturing time. Participants in the robotic group also had significantly higher pain both at rest and with activity 3-5 weeks following surgery and required NSAIDs for a longer time than the laparoscopic group. Finally, the robotic group incurred significantly higher costs than the laparoscopic group. Anatomic outcomes were significantly improved in both groups and did not differ by approach.

The laparoscopic approach to sacrocolpopexy may be broken down into 8 distinct steps, each of which will be reviewed in the presentation, along with tips and tricks for optimizing each step.

- Patient Positioning
- Port Placement
- Vesico-vaginal dissection
- Recto-vaginal dissection
- Presacral dissection
- Suturing mesh onto anterior and posterior vaginal wall
- Tensioning the mesh
- Suturing free end of mesh onto sacrum

#### References

1. Benson JT, Lucente V, McClellan E. Vaginal versus abdominal reconstructive surgery for the treatment of pelvic support defects: A prospective randomized study with long-term outcome evaluation. *Am J Obstet Gynecol.* 1996 Dec;175(6):1418,21; discussion 1421-2.
2. Maher CF, Feiner B, DeCuyper EM, Nichlos CJ, Hickey KV, O'Rourke P. Laparoscopic sacral colpopexy versus total vaginal mesh for vaginal vault prolapse: A randomized trial. *Am J Obstet Gynecol.* 2011 Apr;204(4):360.e1,360.e7.
3. Nygaard IE, McCreery R, Brubaker L, Connolly A, Cundiff G, Weber AM, et al. Abdominal sacrocolpopexy: A comprehensive review. *Obstet Gynecol.* 2004 Oct;104(4):805-23.
4. Ganatra AM, Rozet F, Sanchez-Salas R, Barret E, Galiano M, Cathelineau X, et al. The current status of laparoscopic sacrocolpopexy: A review. *Eur Urol.* 2009 May;55(5):1089-103.
5. Paraiso MF, Jelovsek JE, Frick A, Chen CC, Barber MD. Laparoscopic compared with robotic sacrocolpopexy for vaginal prolapse: A randomized controlled trial. *Obstet Gynecol.* 2011 Nov;118(5):1005-13.



## ROBOTIC REPAIR

Pelvic organ prolapse (POP) will occur in over 11% of women who are post-hysterectomy and there is a lifetime risk of 19% in the general female population for undergoing a surgical procedure for POP. There are numerous proven surgical options for women with POP including trans-vaginal repair with or without mesh interposition, and mesh sacrocolpopexy (MSC) using either an open or a laparoscopic approach. Open MSC is considered the gold standard surgical technique for correction of POP with long term success rates approaching 78-100%. The main drawback of open MSC when compared with a trans-vaginal repair is peri-operative morbidity secondary to the large incision necessary for completion of the procedure. Laparoscopic approach has become a more attractive option especially after the advent of the da Vinci® robotic system which allows for improved ease of maneuvering and intra-corporeal suturing. Up to this point, there have been few series reported in the literature on robotic sacrocolpopexy (RMS) with mostly short follow-up. We describe our current technique and present a table summary of main published series in the literature so far.

### Technique

The RMS is performed using the da Vinci® robot. This system utilizes two robotic arms, a camera arm and an optional fourth robotic arm. The bladder is drained with a 16 French foley catheter. An EEA clamp is placed in the vagina at the beginning of the procedure to aid with prolapse dissection. After gaining pneumoperitoneum and in maximum Trendelenburg position, the camera is inserted through a 12 mm port at the umbilicus, with the robotic arms inserted following a 'W' shape configuration as previously described. An assistant port is placed laterally on the right side, for a total of 5 ports. Docking the robot was done initially at the foot of the bed, however more recently we have evolved to docking from the side in order to maintain access to the vagina. Any abdominal adhesions are taken down as necessary to free the pelvic cavity. At this point small intestines, omentum and left colon are retracted into the upper abdomen, sometimes aided by the Endo Paddle® (a laparoscopic retracting device). Once the pelvis is fully exposed, the trajectory of the right ureter is identified as well as the area of the promontory. Next, the peritoneum is opened at the back wall of the vaginal cuff transversely in order to gain access to the

recto-vaginal space. Then, the dissection is continued anteriorly between the vaginal cuff and the base of the bladder when an anterior compartment prolapse is involved. The anterior dissection is carried distally to above the level of the trigone (3-5 cm distal to the vaginal apex). Posteriorly, the dissection is carried down as distally as possible. The peritoneum over the vaginal cuff is left intact whenever possible to diminish the risk of vaginotomy and of secondary erosion by thinning out the vaginal wall in that area. The peritoneum is then incised from the bottom of the enterocele sac to the sacral promontory on the right side of the rectosigmoid. At this point, the anterior vertebral ligament is exposed. Next, on the back table the anterior and posterior components of the mesh are sutured together in a Y-shape fashion and are measured, trimmed and secured with 2-0 polyglactin sutures at each extremity. The prepared mesh is introduced into the abdomen through the assistant port. The mesh is secured as distally as possible over the posterior vaginal wall with the preplaced absorbable sutures. Additional sutures are placed more proximally and bilaterally over the posterior vaginal wall near the vaginal apex. Because these sutures are absorbable, there is no concern about possibly transfixing the vagina and obtaining a strong vaginal purchase. The anterior portion of the mesh is then secured to the anterior vaginal wall in a similar fashion. Once secured to the vagina, the mesh is then laid in its prepared peritoneal groove extending up to the anterior vertebral ligament. The mesh is secured to the anterior vertebral ligament using two, 2-0 Ethibond® non-absorbable, sutures. The mesh is positioned to follow the concavity of the sacrum, under no tension to ensure vaginal cuff support in a normal anatomic configuration. The peritoneum is then closed over the mesh using running 2-0 polyglactin sutures. A pack is placed in the vagina for 24 hours. The robot is undocked and the port sites are closed in a standard fashion. After IV injection of indigo carmine, cystoscopy is performed to confirm no bladder or ureteral injury.

Table: Review of published robotic sacrocolpopexy series (2006-2011)

Authors	N	Type of Mesh	Type of suture for vaginal mesh anchoring	Anatomic results	mesh erosion	Re-operation for POP	Follow up (months)
Moreno Sierra, et al <sup>1</sup>	31	polypropylene	Non-absorbable	0% recurrent apical prolapse	NR	None	24.5
Tan-Kim, et al (2011) <sup>2</sup>	43	Gynemesh®	2-0 polypropylene	0% recurrent apical prolapse	5%	NR	6
Akl, et al (2009) <sup>3</sup>	80	polypropylene (unspecified)	2-0 prolene	1.25% recurrent apical prolapse	6%	2 rectocele/cystocele repairs, 1 revision of MSC	4.8
Kramer, et al (2009) <sup>4</sup>	21	polypropylene (AMS)	2-0 polyglactin	5% recurrent apical prolapse, 57% recurrent vaginal wall prolapse	0%	12 secondary cystocele or rectocele repairs	25.2
Geller, et al (2008) <sup>5</sup>	73	Intepro®	CV-2 polytetrafluoroethylene	NR	NR	None	1.5
Daneshgari, et al (2007) <sup>6</sup>	12	polypropylene (unspecified)	permanent (unspecified)	0% apical prolapse reported	NR	NR	3.1
Elliott, et al (2006) <sup>7</sup>	21	Intepro®	1-0 polytetrafluoroethylene	5% recurrent apical prolapse	9.5%	1 transabdominal MSC	24

NR=not reported

## References

1. Moreno Sierra J, Ortiz Oshiro E, Fernandez Perez C, Galante Romo I, Corral Rosillo J, Prieto Nogal S, et al. Long-term outcomes after robotic sacrocolpopexy in pelvic organ prolapse: prospective analysis. *Urol Int* 2011;86(4):414-8.
2. Tan-Kim J, Menefee SA, Lubner KM, Nager CW, Lukacz ES. Robotic-assisted and laparoscopic sacrocolpopexy: comparing operative times, costs and outcomes. *Female pelvic medicine & reconstructive surgery* 2011;17(1):44-9.
3. Akl MN, Long JB, Giles DL, Cornella JL, Pettit PD, Chen AH, et al. Robotic-assisted sacrocolpopexy: technique and learning curve. *Surg Endosc* 2009;23(10):2390-4.
4. Kramer BA, Whelan CM, Powell TM, Schwartz BF. Robot-assisted laparoscopic sacrocolpopexy as management for pelvic organ prolapse. *J Endourol* 2009;23(4):655-8.
5. Geller EJ, Siddiqui NY, Wu JM, Visco AG. Short-term outcomes of robotic sacrocolpopexy compared with abdominal sacrocolpopexy. *Obstet Gynecol* 2008;112(6):1201-6.
6. Daneshgari F, Kefer JC, Moore C, Kaouk J. Robotic abdominal sacrocolpopexy/sacruteropexy repair of advanced female pelvic organ prolapse (POP): utilizing POP-quantification-based staging and outcomes. *BJU Int* 2007;100(4):875-9.
7. Elliott DS, Krambeck AE, Chow GK. Long-term results of robotic assisted laparoscopic sacrocolpopexy for the treatment of high grade vaginal vault prolapse. *J Urol* 2006;176(2):655-9.



## Notes

Record your notes from the workshop here