



Complications of Incontinence and Prolapse Surgery: Evaluation, Intervention, and Resolution—A Review from Both Specialties

W42, 16 October 2012 14:00 - 18:00

Start	End	Topic	Speakers
14:00	14:10	Introduction	<ul style="list-style-type: none"> • Howard Goldman
14:10	14:35	Complications of incontinence surgery (except retention)	<ul style="list-style-type: none"> • Sandip Vasavada
14:35	15:10	Retention/Voiding dysfunction after incontinence surgery	<ul style="list-style-type: none"> • Roger Dmochowski
15:10	15:30	Discussion	All
15:30	16:00	Break	None
16:00	16:35	Complications of prolapse surgery (except dyspareunia)	<ul style="list-style-type: none"> • Howard Goldman
16:35	17:00	Dyspareunia after pelvic floor surgery	<ul style="list-style-type: none"> • Tristi Muir
17:00	17:40	Discussion	All
17:40	18:00	Questions	All

Aims of course/workshop

This course will summarize both common and uncommon complications associated with standard and new technologies used for pelvic floor reconstruction and urinary incontinence therapy in women. The intent of this course is to present both the approach to evaluation and management of these complications from both the urologic and urogynecologic perspective of the combined faculty. The emphasis is on newer technologies and complications, both acute and chronic, which are associated with these various surgeries. The goal of this course will be to summarize, not only identification, but also evaluation and appropriate intervention, as well as patient counselling for these various complications.

Educational Objectives

This course will provide a detailed paradigm for avoiding, evaluating and managing complications of incontinence and prolapse surgery. Evidence continues to accrue in this area but it runs the spectrum from Level 1 to 5 with much being expert opinion. Unfortunately, very little cross comparison exists to support these differing interventions. The intent of this course will be to summarize and use this evidence along with the expert opinion of the panel and their peers to develop a paradigm for approach of these complications. The presentations will provide detailed instruction and in particular case discussions by recognized experts in this field.

Complications of Incontinence and Prolapse Surgery: Evaluation, Intervention, and Resolution—A Review from Both Specialties

Sandip P Vasavada MD
 Roger R Dmochowski MD
 Howard B Goldman MD
 Tristi W Muir MD

Complications of Stress Incontinence Surgery (Slings) : (Excluding Voiding Issues)

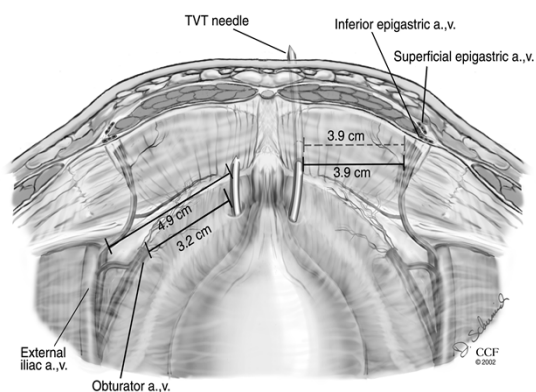
Sandip Vasavada, MD
 Cleveland Clinic Glickman Urological and Kidney Institute
 Cleveland, Ohio

Complications of Vaginal Sling Surgery

- Bleeding
- Infection
- Bladder injury/Perforation
- Bladder outlet obstruction
- Urethral injury
- Neurologic injury/pain
- Mesh related
 - Extrusions into vagina
 - Mesh erosions into urethra
 - Mesh erosions into bladder

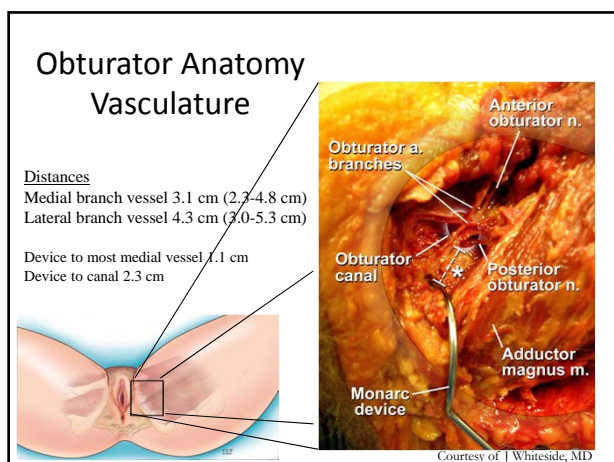
Bleeding During Sling Surgery

- Retropubic passage:
 - entry into retropubic space
 - Sling placement/close observation
 - Foley catheter into bladder, 60cc in balloon and compression
 - Trochar passage
 - Point cautery
 - Usually due to close passage near urethra/periurethral neurovascular compartments
 - Retropubic TVT passage (recognition of injury is key)
 - Exploration (retropubically/open): not transvaginally



Bleeding in Slings

- May occur 0.5 to 8% of time
- No difference between Burch BNS and fascial slings based on Sister trial (2009)
- TOT lower likelihood of bleeding and transfusion rates overall less than 1%



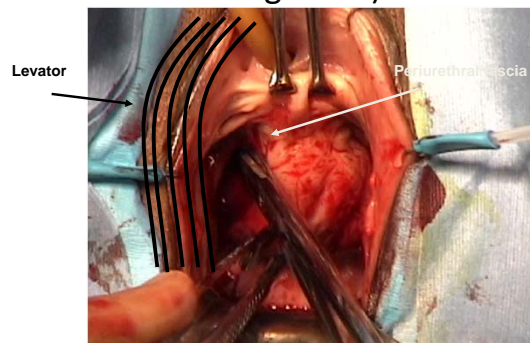Bleeding into Obturator Space

- Very little data
 - Most bleeding will stop with some pressure and placement of sling/compression
 - Foley balloon and inflate with 60 cc sterile water
- What is the utility (if any) of a vaginal pack ?
- case reports
- Compartment syndrome potential
- Use of angiography and embolization?

Bleeding during Retropubic Space entry

- Entry into retropubic space
 - Preservation of endopelvic fascia
- Enter just lateral to periurethral fascia
- Medial to levator fascia and musculature
- Oblique angle 30 degrees from midline towards ipsilateral shoulder

Entry into Retropubic space (fascial slings etc.)



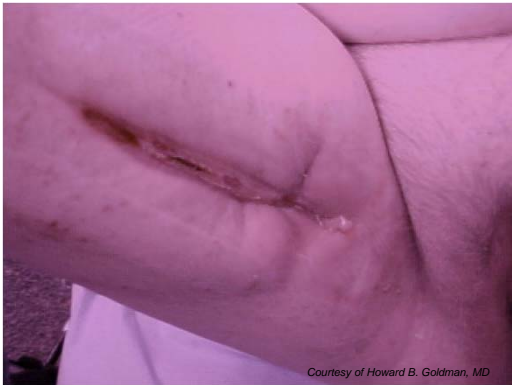Infections

- Sling related infections (with new type 1 meshes are extremely uncommon)
 - Obtape
 - ProteGen
- Urinary tract infections can occur within the first month after sling surgery
 - Discharge
 - Slowing of urine stream
 - Catheters etc..

Perioperative Urinary Tract infections

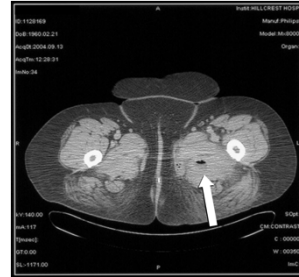
- Post-sling UTI incidence varies from 8-33% (Anger, Laurikainen)
 - Studies not designed to look at this problem
 - Loss to follow-up
 - Lack of standardized perioperative management
 - Perioperative antibiotic protocols often not standardized
 - Diagnostic methods not clear
- Skin and vaginal infections are rare (Laurikainen)
- Overall infection after sling is 5.5 % (Paraiso)
- Used more commonly as a metric in *Outcomes*

Ob Tape Complications

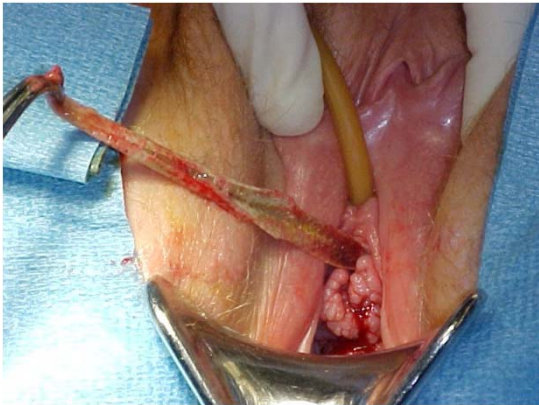


Courtesy of Howard B. Goldman, MD

Infections/ Abscess
66 y/o female s/p TOT sling, fever, pain in thigh, fluctuance, no palp mass

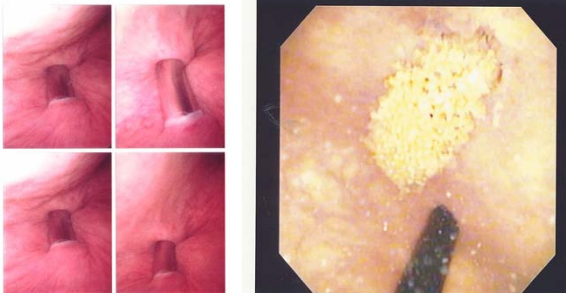
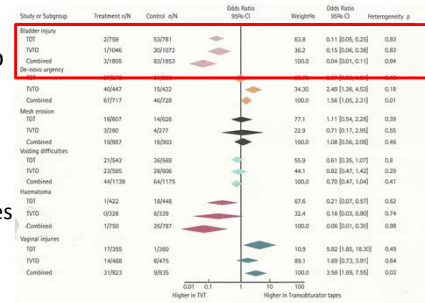


Courtesy of Howard B. Goldman, MD



Bladder Injury/Perforation

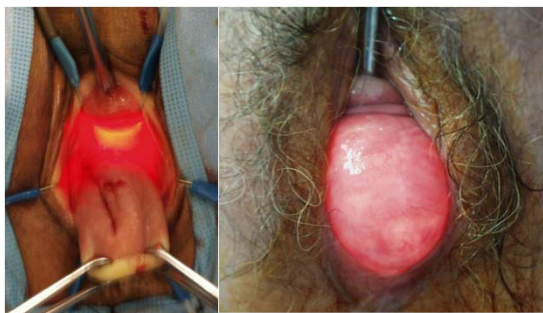
- Not uncommon
- Most series of retropubic slings show rates of 0-24%
- TOT slings too
- 6x less TOT
- Recognized?
- Cystoscopy
 - SUI guidelines



Bladder perforation

- Proper recognition of entry
 - Fluid emanating from space (urine)
 - Irrigation of foley (+/- Indigo Carmine)
 - Cystoscopy
- Suture passage (no further therapy)
- Multilayer closure +/- Martius flap
- No overlapping suture lines
- Good urinary drainage x 5 - 7 days
 - Cystogram to confirm healed bladder wall

LIGHT TEST FOR CYSTOCELE

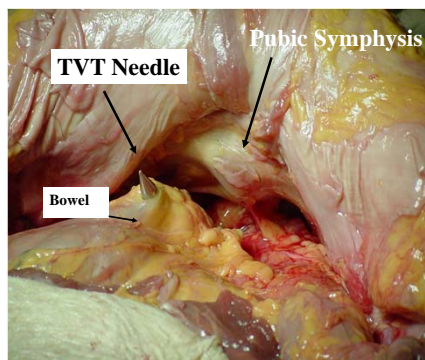


Vasavada, Comiter, Raz, Urol 1999

Urethral Injury

- Overall low incidence (< 1%)
- Again, essential to recognize injury
 - Careful cystourethroscopy
 - Reposition needle/trochars
 - Large injury: probably best to abort surgery (mesh)
 - Primary repair
 - Martius flap ??
- TOT incidence is extremely low but higher with outside in than inside out (BJU int 2010)

Bowel Injury



Picture Courtesy M. Walters

Bowel Injury

- Recognition is again key
- Fatal reports (several)
 - MAUDE database
 - Some from expert TVT implanters
 - Can occur in antegrade slings too (Kobashi et al, 2005)
- Prior abdomino-pelvic surgery
 - Should this contraindicate a tvt sling ?

Neurologic Injury/Pain

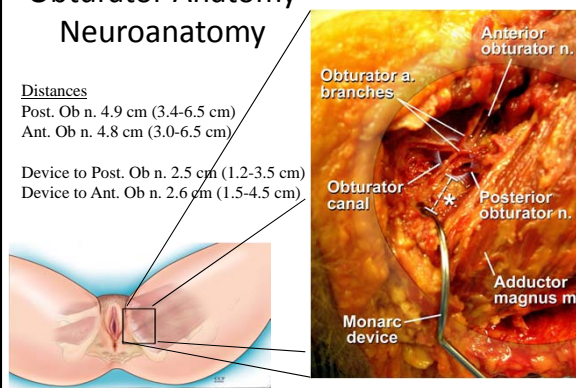
- Trochar passage retropubically (ilioinguinal nerve branches) esp if too lateral
- TOT sling passage can injure groin nerves (higher incidence in less obese patients)
 - Runners
 - Athletic patients
 - Considerations for consent
- TOT (outside in vs inside out): at least transiently, inside out seems to have more pain/neurologic potential abn
- Positioning.... Especially if longer case (prolapse etc..)

Obturator Anatomy Neuroanatomy

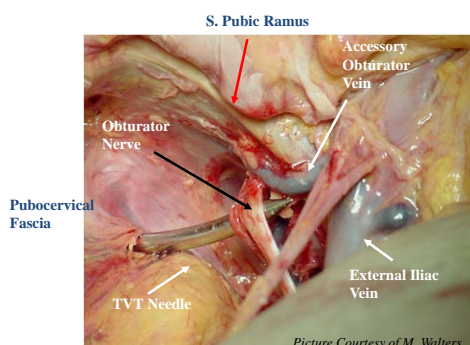
Distances

Post. Ob n. 4.9 cm (3.4-6.5 cm)
Ant. Ob n. 4.8 cm (3.0-6.5 cm)

Device to Post. Ob n. 2.5 cm (1.2-3.5 cm)
Device to Ant. Ob n. 2.6 cm (1.5-4.5 cm)



Nerve & Vascular Injury



Management of Nerve Injury

- Conservative (NSAIDS), rest, time
- Neural pain medications (neurontin etc)
- Pain injections/steroid injections
- Physical therapy
- Removal of sling material
 - May not help pain
 - May elicit more trauma

Mesh Related Complications of Vaginal Sling Surgery

- Extrusion (vaginal exposure)
- Perforation (into urinary tract)
 - Urethra
 - Bladder
- Optimal management

Mesh Complication Presentation

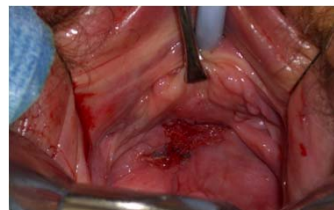
- Extrusion
 - Vaginal discharge
 - Pain
 - Dyspareunia
- Perforation
 - Pain
 - Urinary tract infections
 - Overactive bladder and irritative LUTS
 - Obstructive voiding symptoms
 - hematuria

Mesh Exposure from Slings

- Data shows incidence of less than 2% (Abdel-Fattah et al, BJU int, 2006)
- Most were in ObTape patients
- Etiology
 - Thin flap dissection
 - Vaginal atrophy
 - Breakdown of incision lines

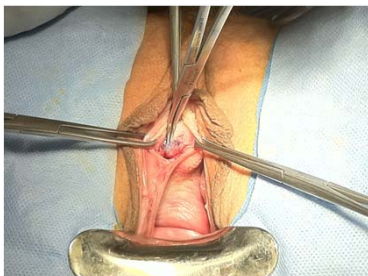Mesh Extrusion

- Management options
 - Vaginal estrogens (limited confirmational data)
 - Flap coverage (small series of good results)
 - Consent for possible need for repeat management
 - Mesh excision and closure of vaginal walls
 - Risk of recurrent SUI



Mesh Extrusion “Button-Hole”

- Reported series are mostly in TOT sling patients
- High lateral sulcus
- May elicit pain



Managing Mesh Complications

- Resolution of mesh exposure may be done with antibiotics and estrogen cream
- Treat in office when mesh exposure is:
 - Easy to reach and near the introitus
 - Small and requires minimal excision
- Treat in OR if mesh exposure is:
 - Large and requires reapproximation of mucosa

Vaginal Erosions of Mesh are Increasing in Incidence as the Use of Mesh Increases

Erosions can be found after:

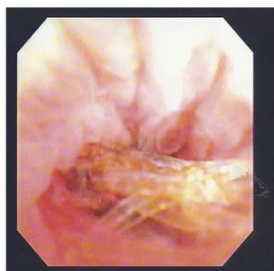
- Slings
- Abdominal sacral colpopexy (open or laparoscopic)
- Cystocele and rectocele repairs
- Tunneller procedures for vaginal apex prolapse

Diagnosis of Mesh Perforation

- History:
 - Pain
 - Urinary tract infections
 - Overactive bladder and irritative LUTS
 - Obstructive voiding symptoms
 - hematuria
- Physical exam (tenderness suburethrally ?)
- Cystoscopy (flexible) bias
- Urodynamics ? Is patient obstructed ?

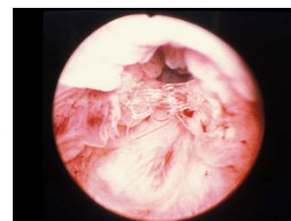
Urethral Perforation/Erosion

- Presenting symptoms may dictate best treatment option
 - Elderly patient
 - Minimal symptoms
 - Hematuria
 - No irritative or obstructive symptoms



Erosion into Urethra

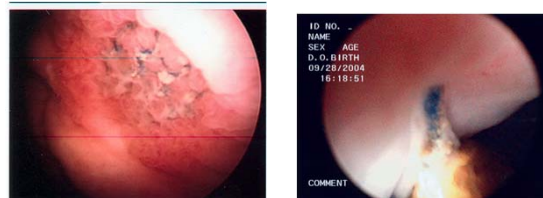
- Should be noted on preop cystoscopy
- Can be managed with endoscopic rx (not scissors, TUR or Bugbee but rather Holmium laser)
- Follow up cysto to assure no remaining edges



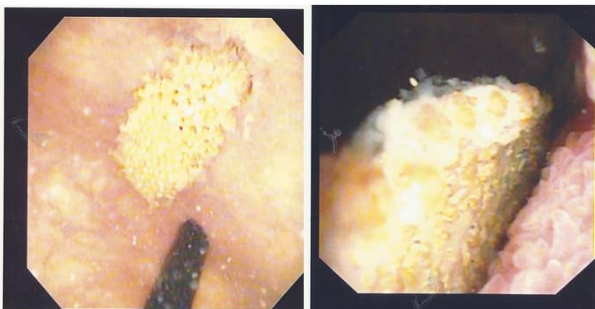
Perforations/Erosions into Bladder

- Optimal management again depends on patient symptoms
 - Endoscopic (holmium laser)
 - Transvesical (definitive)
 - Single port (Cleveland Clinic experience)
 - Open (allows excision of all portions of mesh)
 - Transvaginal (if posterior).... Fistula potential

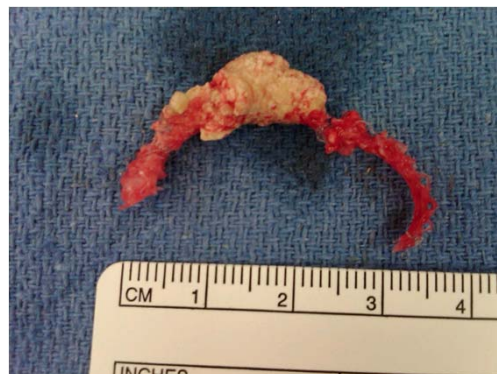Perforations/Erosions into Bladder



Bladder Perforations/Erosions



Path



Conclusions

- Mesh use for slings is likely here to stay
- Surgical principles in exposure (flaps) and closure are important considerations
- Complications can and will occur
- Recognition is key
- If postoperative recognition, complete removal (exposed and then some margin.. Will be necessary in most patients)

Post Operative Voiding Dysfunction and Obstruction: Diagnosis and Treatment

Roger Dmochowski
 Dept of Urology
 Vanderbilt University

Etiologies

- Iatrogenic – post operative for incontinence procedure (most common)
- Iatrogenic – repetitive urethral instrumentation
 - Intrinsic stricture disease
- Smooth sphincter dysfunction
 - Bladder neck dysfunction
- Functional
 - Dysfunctional voiding

Iatrogenic – repetitive urethral instrumentation

Intrinsic stricture disease

- Urethral mucosal involvement
- Causes
 - Repetitive urethral dilatation
 - Prior diverticulectomy
 - Catheter related phenomenon
- Treatments
 - Dilation
 - Incision
 - Reconstruction

Iatrogenic Obstruction

- True incidence after incontinence surgery not known
 - Literature estimates 2.5 - 24%
 - Obstruction requiring intervention
 - Contemporary sling series 1-3%
 - TVT 1.7 -4.5%

Voiding Dysfunction After Incontinence Surgery

[Dunn et al, Int Urogynecol J 2004; 15:25-31](#)

- Medline search 1966-2001
- Retrospective collections, case reports or case cohort series
- Rates of voiding dysfunction:
 - Burch - 4-22%
 - MMK - 5-20%
 - PVS - 4-10%
 - Needle Susp. - 5-7%
 - TVT - 2-4%

Etiology

- Obstruction / Incomplete Emptying
 - Excessive tension or misplaced sutures or sling
 - Postoperative cystocele or other prolapse
 - “Relative” impaired detrusor contractility
 - Habitual voiding by abdominal straining
- Storage Symptoms (Frequency/Urgency/UUI)
 - DO secondary to obstruction
 - DO without obstruction
 - “Sensory urgency”

Presentation

- Urinary retention
- Voiding (obstructive) symptoms
- Storage (irritative) symptoms
 - frequency, urgency, urge incontinence
- Recurrent UTI
- May have recurrent or persistent SUI with obstruction

Timing of Evaluation / Intervention

- First 3 months - watchful waiting vs. early intervention
 - Depends on procedure done
- 3 - 6 months - consider formal evaluation and intervention
 - Decision often based on degree of bother to patient
 - May still experience improvement
- After 6 months - condition less likely to improve
 - especially for cases of retention

Evaluation

- History*
 - Preoperative voiding and continence status
 - Onset of symptoms
 - Type of procedure performed
 - Number and type of other procedures
- Physical Exam*
 - “Over correction”
 - Hypermobility
 - Cystocele, enterocele, rectocele, uterine prolapse

* In cases of retention history and physical may be all that is needed

Evaluation

- Endoscopy
 - Eroded sutures
 - Eroded sling
 - Urethral kink or displacement
 - Bladder neck mobility - kinking with straining
- Urodynamics
 - Videourodynamics

Urodynamics

- Not always helpful in making diagnosis of obstruction after incontinence surgery
 - Webster & Kreder, 1990
 - “Urodynamics may fail to diagnose obstruction”
 - Foster & McGuire, 1993
 - Urodynamics did not predict outcome
 - Nitti & Raz, 1994
 - Pdet and Qmax were not predictive of outcome independently or together. All “acontractile” patients successful

Intervention

- Only *absolute* selection criteria for urethrolisis should be a temporal relationship between surgery and onset of voiding symptoms
- Failure to generate a detrusor contraction during urodynamics should not exclude a patient from definitive treatment, e.g. urethrolisis

Treatment Options

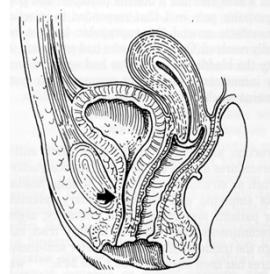
- Conservative
 - CIC
 - Pharmacotherapy
 - Biofeedback
 - Dilatation (??)
- Definitive
 - Surgical

Definitive Treatment Options

- Urethrolisis
 - Transvaginal
 - Retropubic
 - Suprameatal (infrapubic)
- Sling incision
- Mid urethral synthetic sling loosening or incision
- Cut suspension/sling sutures
 - Would expect greatest success if done early
 - *No documented peer-reviewed series*

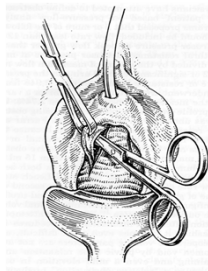
Anatomy

- Urethra may be fixed to the pubic bone with dense scar tissue
- Goal of urethrolisis is to completely free & mobilize urethra



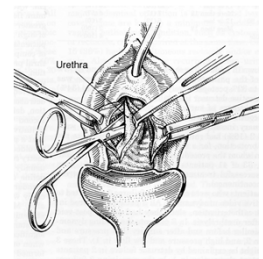
Transvaginal Urethrolisis

- Inverted U incision
- Lateral dissection above periurethral fascia
- Endopelvic fascia sharply perforated and retropubic space entered

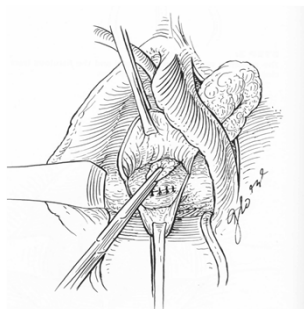


Transvaginal Urethrolisis

- Sharp and blunt dissection freeing the urethra from the undersurface of the pubic bone
- Index finger placed between pubic bone and urethra

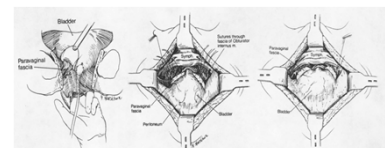


Transvaginal Urethrolisis



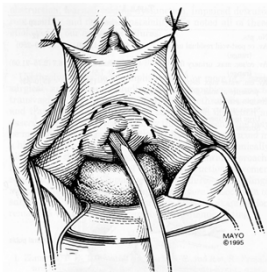
Retropubic Urethrolisis

- Mobilization of urethra by sharp dissection
 - Restore complete mobility to anterior vaginal wall
- Paravaginal repair
- Interposition of omentum between urethra and pubic bone



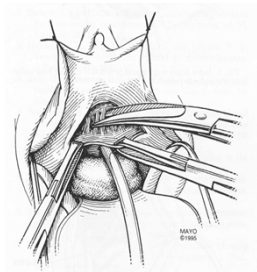
Suprameatal Urethrolisis

- Curved incision above the urethra



Suprameatal Urethrolisis

- Sharp dissection of urethra and bladder neck off pubic bone
 - Pubourethral, pubovesical “ligaments” incised
 - Retropubic space entered
 - Lateral attachments left
 - ? injury to autonomic nerves
- Martius flap interposition (optional)



Urethrolisis Results

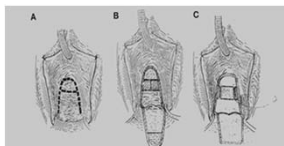
	<i>N</i>	<i>Type</i>	<i>Success</i>	<i>SUI</i>
Foster & McGuire	48	Transvaginal	65%	0
Nitti & Raz	42	Transvaginal	71%	0
Cross, et al	39	Transvaginal	72%	3%
Goldman, et al	32	Transvaginal	84%	19%
Petrou, et al	32	Suprameatal	67%	3%
Webster & Kreder	15	Retropubic	93%	13%
Petrou & Young	12	Retropubic	83%	18%
Carr & Webster	54	Mixed	78%	14%

Urethrolisis – Predicting Outcomes

- No consistent predictors of outcome
 - Only factor predictive of failure was increased PVR (Nitti & Raz)
 - Higher success in spontaneous voiders vs. those on cath (Foster & McGuire)
 - 74% vs. 54%
 - No difference for retention vs. irritative symptoms (Petrou, et al)
 - 65% vs. 67%

Sling Incision

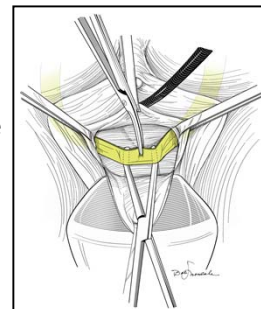
- Case report described by Ghoneim in 1995 using a vaginal graft interposition



- Later several authors reported small series of sling incision with and without interposition of vaginal wall

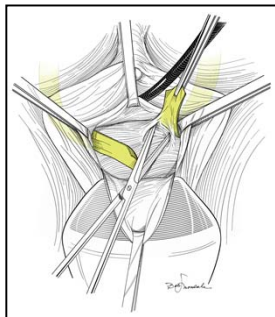
Pubovaginal Sling Lysis

- Inverted U or midline incision
- Isolation of sling in the midline
- Incision of the sling



Pubovaginal Sling Lysis

- Freeing of the sling from the underlying urethra
 - May require sharp or blunt dissection
- No perforation of the endopelvic fascia
- No freeing of the urethra from the pubic bone
- Closure of the vaginal wall



Pubovaginal Sling Lysis By Midline Incision

- 19 women
 - 12 dependent on catheterization
 - 4 obstructive symptoms
 - 3 predominately freq/urge and urge incontinence
 - 15 autologous fascia, 3 allograft fascia, 1 synthetic
- Outpatient procedure
- 12 months mean follow-up

Sling Incision Results

SUI	N	Type	Success
Nitti, et al 17%	19	Midline Incision	84%
Amundsen, et al 9%	32	Various	94% retention 67% UUI
Goldman 21%	14	Midline Incision	93%

TVT and Obstruction

- Klutke, et al Urology 58:697, 2001
 - 600 patients
 - Multicenter
 - 17 (2.8%) obstructed requiring take down
 - Mean time 64 days (6-228 days)
 - Simple midline incision
 - 100% success for spontaneous voiding
 - Mean follow up 13 months (12-16)
 - 1 urethral injury
 - 1 (6%) recurrent SUI
- If within 10 days consider “loosing” sling

Obstruction From TVT

- Critical to identify and cut or loosen sling
- Urethrolisis without identifying TVT likely to fail
- In cases of early intervention (up to 14 days) may be able to loosen by pulling down
- After 10-14 days need to incise as TVT is ingrown with native tissue
- Chronically can become a tight band

Technique of Mid Urethral Sling Loosening 1-2 weeks

- Infiltrate anterior vaginal wall with 1% lidocaine
- Open vaginal suture line
- The sling is identified and hooked with a right-angle clamp
- Spreading of the right angle clamp or downward traction on the tape will usually loosen it (1-2 cm)
- If the tape is fixed, it can be cut
- Reapproximate vaginal wall

Sling Take-Down

- Sling incision is a simply technique with low morbidity which is applicable to all types of sling materials
 - Recommended as first line treatment
- When sling cannot be clearly identified, formal urethrolysis is recommended

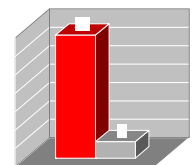
What Happens When Urethrolysis Fails?

Repeat Urethrolysis

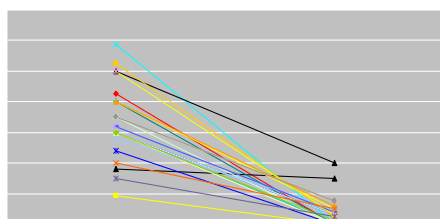
- 24 women all failed at least one prior urethrolysis
 - All deemed obstructed by a combination of clinical criteria
- All underwent repeat urethrolysis via transvaginal or retropubic route (surgeon's discretion)
 - Aggressive approach taken with complete mobilization of urethra off the pubic bone
 - Mean follow up = 14 months

Results Emptying

- Normal emptying with relief of obstructive symptoms in 22/24 (92%)
 - PVR \leq 100 ml
- 20/22 (91%) catheter dependent patients no longer needed to catheterize
- 2 non-catheter dependent patients had PVR = 0



Results Emptying



Results

- | | |
|--|--|
| <p>Urge Incontinence</p> <ul style="list-style-type: none"> • 2/16 (12%) complete resolution • 11/16 (69%) improved, but required anticholinergics • 3/15 (19%) no improvement | <p>Stress Incontinence</p> <ul style="list-style-type: none"> • 4/22 (18%) developed de novo SUI • 2 had persistent SUI • 5 women had collagen injection with 4 (80%) improved |
|--|--|

“Resuspension” With Urethrolisis

- Not routinely necessary after transvaginal urethrolisis
 - Decision for resuspension can be made at the time of surgery based on operative findings
 - Recurrent SUI rates 0 - 19% if no resuspension
- Consider when there is persistent SUI associated with obstruction
 - “Loose” sling preferred

Resuspension With Urethrolisis

- De novo SUI after urethrolisis without resuspension
 - Foster and McGuire - 0
 - Carr and Webster -14%
 - Goldman, et al - 23% of successes
 - 66% responded to collagen

Urethrolisis Approach

- Vaginal approaches
 - Usually first approach
 - Quicker recovery
- Retropubic approach
 - After a failed vaginal approach
 - Vaginal surgery contraindicated or not desired
 - Other abdominal or retropubic surgery
 - Complex cases / surgeon’s preference

Flap Interposition With Urethrolisis

- Recommended for all retropubic and infrapubic urethrolisis
- Recommended for redo transvaginal urethrolisis
- If any doubt - do it

Conclusions

- Clinically significant obstruction after incontinence surgery is uncommon, but occurs even in the most experienced hands
- Urethrolisis or sling incision, by a variety of techniques, is successful in restoring emptying and relieving LUTS in the majority of cases

Complications of Prolapse Surgery: Prevention, Evaluation and Management

Howard B Goldman MD

Section of Female Pelvic Medicine and Reconstructive Surgery
Glickman Urologic and Kidney Institute
The Cleveland Clinic
Lerner College of Medicine
Cleveland, Ohio

Outline

- Perioperative
- Postoperative
 - Bleeding
 - Infection
 - DVT
 - Voiding dysfunction
 - Pain/Nerve Injury
 - Graft complications

Bleeding

- Incidence depends on definition
- Varies by procedure
- Overall less than 2% require blood transfusion
 - Potential for significant bleeding during SSF

Bleeding

- Incidence depends on definition
- Varies by procedure
- Overall less than 2% require blood transfusion
 - Potential for significant bleeding during SSF
 - Stay 2 cm medial to ischial spine and superficial under the ligament – not necessary to go around entire coccygeous muscle
 - Pudental vessels and nerves lay deep to the coccygeous and near/lateral to iliac spines.

Mild Bleeding

- Not unusual
- For very small bleeders
 - finish procedure - pack
- Larger bleeders
 - cautious cautery
 - oversew with absorbable suture
 - finish procedure and pack

Moderate-Significant Bleeding

- As on prior slide
- If deep in vagina/pelvis may be difficult to access
- Temporary packing
- Judicious clip placement – Disposable long shaft
- Hemostatic agents – Floseal
- Embolization

Bladder Injury

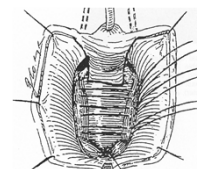
- Always try to close with multiple layers
- Straightforward in “traditional” cystocele repair
- If doing deep lateral dissection – mesh kits
 - May be difficult to visualize
 - Reapproximate tissue in that area – may only get one layer
 - Evaluate location of ureters – check for efflux
 - ? If mesh should be placed
 - My personal preference....
- Leave Foley catheter for 7-10 days

Ureteral Injury

- Many not diagnosed at time of surgery
- Delay in diagnosis contributes to morbidity
- At time of surgery can remove sutures and/or stent fairly easily

Ureteral Injury/Obstruction During Plication

- May catch or kink ureters
- 0.5-2%
- Check for ureteral efflux after sutures placed (without pulling too much)/tied
- If necessary remove sutures and redo



Ureteral Injury/Obstruction During Vault Suspension

- Not rare during ureterosacral ligament vault suspension 1-11%
- Ureter not far from USL
 - Stay medial and cephalad
- Check for ureteral efflux after sutures placed – put tension on them
 - I check again at end of case after all tied down
- If no efflux – cut sutures on that side and replace

Ureteral Injury during Dissection

- Unusual
 - More common in stage 4(3?) AVW prolapse
- Can occur with dissection deep to pubocervical fascia
 - Commonly used in synthetic mesh repairs
- Stent/Repair/Reimplant

Avoiding Bladder and Ureteral Injury

- Appropriate Exposure
- Stay in the right plane
 - Synthetic mesh – hydrodissection
 - Trochars – cysto with a 70 angle lens
- For stage 4 (?) AVW prolapse – consider ureteral catheters
- Cystoscopy to check bladder integrity and ureteral efflux

Rectal Injury

- Can occur during rectocele repair or dissection for vault/enterocele
- Careful dissection
- Know where the rectum is at all times
 - ? Rectal pack?
- More common during repeat rectocele repair
- For SSF – don't try to force retractors into pararectal space – place gently

Rectal Injury

- Almost always can do layered primary repair
- Call colorectal surgery to help
 - ? safer if any medicolegal issues arise
- Probably no need to keep NPO (if below peritoneal reflection) – follow the colorectal surgeons advice
- (If planned posterior mesh – would ABORT)
- I do gentle bowel prep prior to rectocele or SSF repairs
 - bottle of Mag Citrate afternoon prior and enema evening prior
 - As much to avoid straining with BM for first few days as to have relatively clean rectum

Postoperative Complications

- Infection
 - UTI – not rare
 - Wound infection
 - Unusual

Prevention of UTI

- Sterile urine pre-op
- Dose of perioperative antibiotics
- Current recs – less than 24 hours antibiotics
- Avoid prolonged catheter use if possible

UTI

- Simple – treat
- Recurrent – Cystoscopy to rule out intravesical stitch/mesh
- If catheter in longer than 24 hours consider one dose of antibiotic at catheter removal

Superficial Wound Infection

- Antibiotics – cipro and flagyl
- Warm baths
- Supportive care

Deep infection

- Pelvic abscess
 - Drain
 - Transvaginally – US guidance
 - Percutaneously – CT guidance
 - Antibiotics

Vesicovaginal Fistula

- Uncommon after cystocele repair
 - Unrecognized bladder injury at time of repair
 - Inadequate closure/drainage after recognized bladder injury
- More common with mesh repairs
 - Deeper dissection during repair
 - Placement of foreign body

VVF

- No mesh involved
 - Transvaginal repair after tissue healed
 - Usually more distal than typical VVF
 - Easier to access
 - Transabdominal repair if more comfortable with that approach
 - Not necessary to wait 3 months
- Mesh involved
 - Will discuss with intravesical mesh

Ureteral Injury

- Mean delay to dx – 5.6 days Kim JH, Intl Urogyn J, 2006
- Multiple presenting symptoms
 - Incontinence
 - Flank pain
 - Sepsis
 - Ileus
 - 5% “silent” - dx later as non-fxn/hydro kidney
- Typically some CT abnormality noted first
 - Hydroureteronephrosis down to pelvis

Ureteral Injury

- Cysto, retrograde, stent
 - Suture removal often necessary
- Percutaneous nephrostomy
 - Antegrade stent
- Reimplant
 - Usually at a later date – after stent/nephrostomy

Voiding Dysfunction

- De-Novo Stress Incontinence
- Urge Incontinence
- Difficulty Emptying
- Covered in previous lecture

Selective sling at time of POP surgery

- If could demonstrate SUI on UDS or when pessary placed – sling placed
 - Risk of intervention from sling 8.5%
 - Risk of intervention for sui with no clinical or uds hx of sui - 8.3%
 - Risk of sui when hx positive for sui (but uds and packing neg for sui) – 30%

Ballert, JN, et al, J Urol, 2009

What I Do

- If doing POP repair
 - History (even in past) of SUI – recommend sling
 - No history of SUI but when bladder filled and POP reduced – SUI – recommend sling
 - No hx of SUI and unable to elicit any SUI – counsel against concomitant sling

New Urge Sxs

- Make sure not in retention
- Evaluate for obstruction
- If continues for significant period of time make sure no foreign body in bladder
- Treat above
- Treat as typical OAB

“Nerve Pain”

- Can occur with deep bite of USL
- Buttock pain in 10-15% of SSF suspension
 - May be due to nerve within SSF-coccygeous
 - Usually temporary
 - Anti-inflammatories/time
- Rare cases may require stitch removal

Lowenstein L, et al, Intl Urogyn J, 2007

Biologic Graft Complications

- Infections/Fluid collections
 - Usually spontaneously drain
- Extrusion/Wound healing
 - May reepithelialize
 - May require removal

Synthetic Graft Complications

- Pain
- Vaginal Extrusion
- Intravesical Erosion
- Rectal Erosion

Incision of Arm

- Palpate arm
- Inject local in fornix
- Incise over arm
- Get around arm
- Incise arm

Pain At Body of Mesh

- Initial conservative management
- If persists remove
 - If not extruded – important to map out the exact areas of tenderness to make sure those areas are removed at time of surgery

Rectal Erosion of Mesh

- May be asymptomatic or can cause significant morbidity
- Probably under-reported as most do not do routine rectal exams
- Risk factors
 - Previous rectocele repairs
 - Rectal disease – can lead to disasters
 - Inflammatory Bowel Disease
 - Diverticulitis

Mesh Extrusion

- 3-15% - depending on series
- Prevention
 - Pre-op hormonal cream
 - Dissect and place deep to pubocervical fascia
 - Ensure mesh lays flat
 - Avoid excessive vaginal wall trimming

Mesh Extrusion - Management

- Observation – if not sexually active and not symptomatic
- Hormonal cream – I have not had much luck
- Trim in office – very small exposures
- Remove in OR

Removal of Mesh

- Decision of whether to remove just localized area of mesh vs all mesh
 - Based on sxs, pain, etc
- Infiltrate with lidocaine with epinephrine
- Excise skin edges
- Undermine and remove mesh 1 cm from skin edges
- Utilize sharp and blunt dissection
 - Kitner/peanut
- Posterior – may benefit from finger in rectum
- Close vaginal skin

Experience with Mesh Removal

- Avg age – 60
- Prior medical tx – 84%
- Latency to presentation 17 wks (0-96)
- Indication for removal
 - Symptomatic mesh erosion 12 (63)
 - Recurrent pelvic organ prolapse 8 (42)
 - Chronic pain 6 (32)
 - Dyspareunia 6 (32)
 - Vesicovaginal fistula 3 (16)
 - Multiple indications 16 (84)

Ridgeway B, Am J Obs Gyn, 2008

Experience with Mesh Removal

- 79% excised transvaginally
- Follow up – 16-75 weeks
- Pain scores – 0 (0-8 scale)
- 87% free of presenting symptoms

Ridgeway B, Am J Obs Gyn, 2008

Intravesical Mesh Erosion

- May be associated with VVF
- Can approach abdominally or transvaginally
- Most have reported a transabd approach

Intravesical Mesh Erosion

- May be associated with VVF
- Can approach abdominally or transvaginally
- Most have reported a transabd approach
- **I prefer transvag approach**
 - Good exposure
 - Minimal morbidity
 - Can remove almost all of mesh under bladder

Complications of POP Surgery

- Perioperative
- Postoperative
 - Bleeding
 - Infection
 - DVT
 - Voiding dysfunction
 - Pain/Nerve Injury
 - Graft complications

Complications of POP Surgery

- Prevention is the best treatment
- Identify at time of surgery – lowest morbidity if dealt with then
- Mesh repairs have introduced a number of new potential complications
- Even with significant complications – most patients can be treated with minimal residual morbidity
- Key is identifying problem and knowing how to deal with it

Dyspareunia Following Prolapse Surgery

Tristi W. Muir, MD
Associate Professor
Director, Pelvic Health and Continence Center
University of Texas Medical Branch, Galveston

Objectives

- To develop an understanding of the possible etiologies of dyspareunia
- Explore the literature on frequency of pelvic surgery related dyspareunia
- Construct strategies to avoid de novo post-operative dyspareunia
- Evaluate dyspareunia treatment plans- who, what, when and where?

Dyspareunia Etiology

- Landscape
- Nerves
- Muscles
- Mind
- His problem

Landscape

- G-spot disruption
- Vaginal narrowing
- Erosion
- Vaginal lubrication decreased

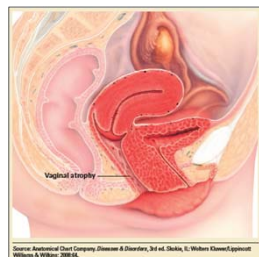
Vaginal Dimensions

- Vaginal length and caliber decreases significantly
- No correlation with sexual function and vaginal dimensions
- Dyspareunia increases in women undergoing prolapse surgery (8% Vs. 19%)
- Sexual satisfaction improved with sexual function (82% Vs. 89%)

Weber, 2000

Vaginal Atrophy

- Affects 10-40% of postmenopausal women
- Symptoms- vaginal dryness, pruritus, bleeding dyspareunia

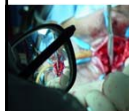

Atrophy

- Estrogen
- Vaginal lubricants
- Foreplay
- Regular sexual activity

Erosion

- Healing
 - Vascularization
 - Collagen formation
 - Age
 - Estrogen status
 - Immune status
 - Avoidance of hematoma and infection



Prospective Clinical Assessment of the Transvaginal Mesh Technique for Treatment of Pelvic Organ Prolapse- 5 Year Results

Complication	Number affected (N=85)	% affected	Surgical intervention N (%)
Mesh erosion	15	17.6%	7 (8%)
De novo dyspareunia	3	3.5%	

Miller, D et al. Abstract AUGS, 2010

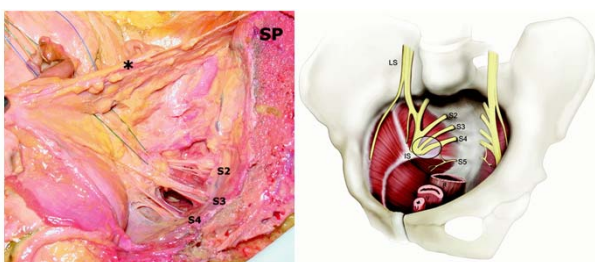
Late Erosion

- More common in sexually active women (17.3% Vs. 2% respectively)- OR 10.47
- Kaufman 2011

Vaginal Dimensions

- Dilator
- Estrogen
- Physical therapy
- Surgery

Nerve Entrapment and the Uterosacral Vaginal Vault Suspension



Siddiqui NY et al. Obstet Gynecol 2010;116:708-13.

Nerve Entrapment and the Uterosacral Vaginal Vault Suspension

- 7/182 women with USVVS with nerve entrapment
- Symptoms
- Treatment
 - Removal of ipsilateral US suture
 - Treatment with PT and gabapentin

Flynn MK et al. AM J Obstet Gynecol. 2006;195:1869-72.

Nerve Entrapment and the Sacrospinous Ligament Fixation

- N = 52F/U 38 months
- 3/52 with de novo dyspareunia
 - 2 resolved with suture removal

Baumann M. et al Surg Endosc. 2009;23:1013-7.

Abdominal Sacrocolpopexy Vs Sacrospinous Ligament Fixation

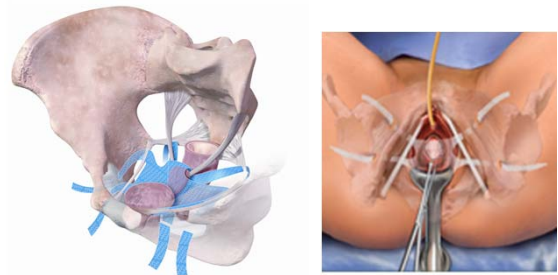
- Randomized trail
- N=95
- Impact of sexual function secondary outcome

Maher CR et al. American Journal of Obstetrics and Gynecology (2004) 190, 20e6

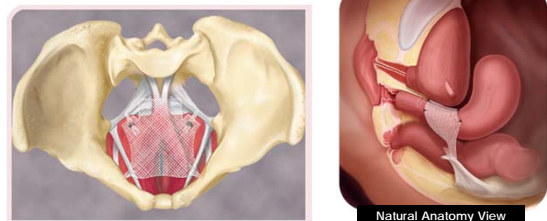
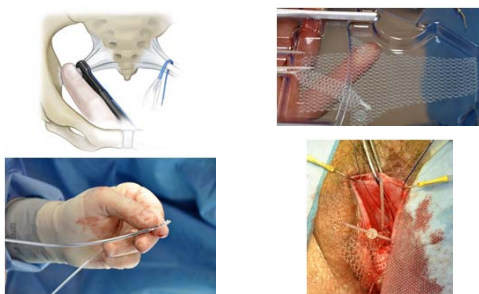
Trocar Systems



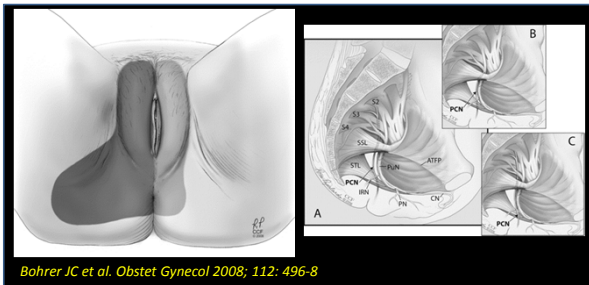
Mesh Arms



“Trocarless” Placement



Pelvic Pain Following Vaginal Mesh Placement



Bohrer JC et al. *Obstet Gynecol* 2008; 112: 496-8

De novo dyspareunia estimated to be at least 3%

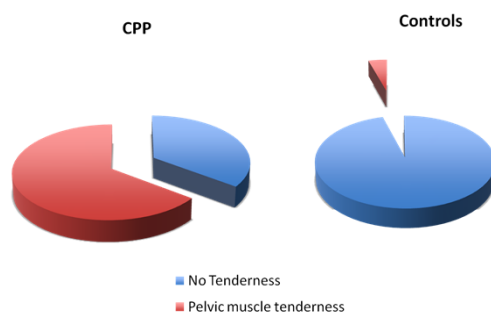
Mesh Kits: Tricks

- Thick vaginal flaps
- Avoid tension
- Avoid “bunching” of mesh
- Use vaginal estrogen prior to and after surgery
- Know your anatomy, mesh and what to do if you have a complication

Vaginismus

- Affects 1-7% of world’s population

Evaluation of Pelvic Floor Muscles

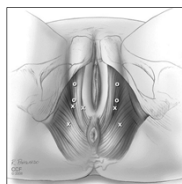


Montenegro M et al. *Pain Medicine* 2010;11:224-8

Pelvic Floor Muscles Treatment

- Dilators
- Physical therapy
- Trigger point injection-
- Botulinum toxin type A

Botulinum toxin type A injections



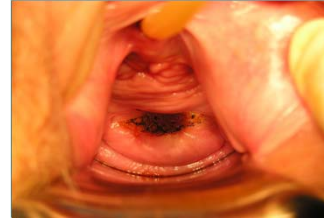- Initial injection- 10 Units at 5 sites
- 1 month later- 10 Units at 4 sites

Park, Amy; Paraiso, Marie *Obstet Gynecol.* 2009;114:484-487

It's all in their head

- Complexity of female sexual dysfunction
 - Physical health of both people
 - Emotional health
 - Body Image
 - Partner's reaction to prolapse and surgery
 - Intimacy of their relationship

Hispareunia



Treatment Erosion

- Micro-erosion
 - Estrogen cream
 - Colposcope may be helpful to identify and cut mesh
- Macro-erosion
 - Estrogen cream
 - Excision with vaginal flap advancement
 - Combination

Erectile dysfunction

- Most men >45 years of age have ED at least some of the time
- Projected to affect 322 million men worldwide by 2025
- Severity and prevalence increase with age

[La Vignera S](#) et al. Androl. 2011 May 19. [Epub ahead of print]

Treatment of ED

- PDE5I
- vacuum erectile device (VED),
- intraurethral medication,
- intracavernosal injection (ICI),
- androgen supplement,
- α -blocker
- combinations

How can we avoid it?

- Pick the right patient
- Pick the right procedure
 - Are there procedures we should avoid?
 - Do we know?
 - What directions do we need to follow to answer our questions
- Perform the procedure correctly
- Preoperative counseling

Dyspareunia Happens

- Evaluation
 - Severity
 - Time course
 - Location

Treatment Nerve Entrapment

- Moderate- Severe
 - Remove the sutures as quickly as possible
- Mild – Moderate (getting better???)
 - Reassurance
 - Trigger point injection

Counseling

- Multidisciplinary Options
 - Pre-operative counseling
 - Treat the underlying pain
 - Sexual counseling
 - Physical therapy
 - Treat atrophy

Dyspareunia Happens

- Treatment plan
 - If severe- be aggressive
 - Evaluate etiology
 - Treat with
 - Estrogen
 - Dilators
 - Injections
 - Surgery
 - Lean on associates
 - » Physical Therapy
 - » Sexual counseling

Case Presentations

Complications

- Complications will occur
- Proper planning can help minimize them
- Proper evaluation can readily identify them
- Proper treatment can make sure that most complications can be treated with little residual morbidity



Notes

Record your notes from the workshop here