

# #340 Randomized trial to compare **SOLIFENACIN** and **TRANSOBTURATOR TAPE** placement *after bilateral apical fixation* in the treatment of **urgency urinary incontinence**

– first results –

Ludwig S, Jäger W and Mallmann P

University of Cologne, Dept. of Gynecology and Obstetrics, Div. of Urogynecology, Cologne, Germany

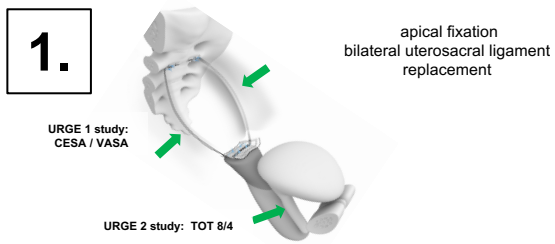
Corresponding author: [sebastian.ludwig@uk-koeln.de](mailto:sebastian.ludwig@uk-koeln.de)

## Aim of the study

The etiology of urinary incontinence is unknown. Beside stress urinary incontinence (SUI), current treatment options are based on a neurological disorder or the detrusor. Ulmsten and DeLancey hypothesized an anatomical defect of the anterior vaginal wall: laxity of the 3 levels (the paraurethral tissue, the apical end and vesicourethral junction).

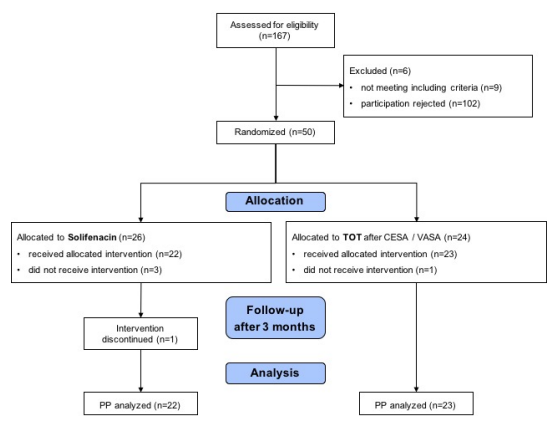
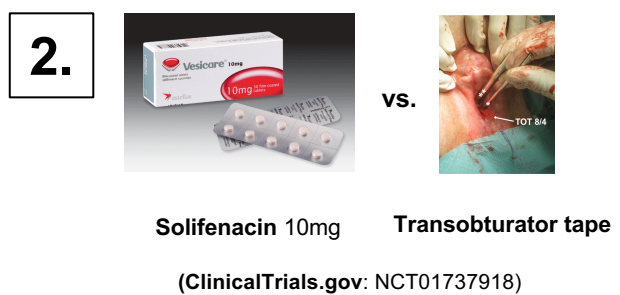We evaluated the effect of a transobturator tape placement (in patients with bilateral replacement of the uterosacral ligaments) on urgency urinary incontinence and mixed urinary incontinence.

## Study design, material and methods



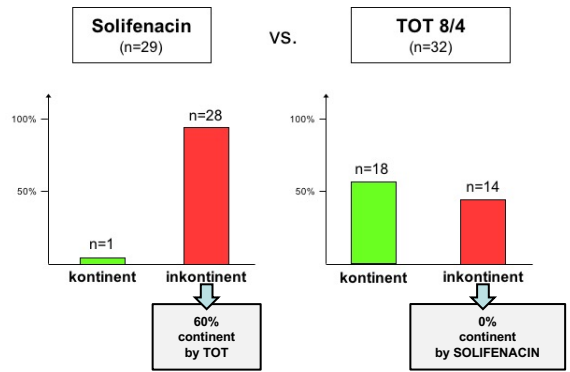
### Inclusion criteria URGE 2 study:

- prior **apical fixation by CESA / VASA** (cervicosacropexy / vaginosacropexy, bilateral uterosacral ligament replacement)
- and persistent UUI-symptoms



## Results

61 patients with UUI or MUI after CESA or VASA surgery were randomized and were evaluable for analysis. In the solifenacin treatment arm one of the 29 patients treated with solifenacin were cured. In 18 out of 32 patients (56%) continence was restored after transobturator tape placement.



## Interpretation of results

The standard pharmacological treatment (solifenacin) for UUI symptoms restored continence in only one of these patients (under medication). The replacement of the pubourethral ligaments with a transobturator tape (TOT) restored continence in 56% of patients with UUI or MUI.

## Concluding message

The bilateral replacement of the uterosacral ligaments by CESA and VASA surgical procedures in addition with the replacement of the pubourethral ligaments by a transobturator tape provided one therapy to restore continence in over 75% of patients with UUI and MUI. Surgery for UUI symptoms outperformed medication.