

A COMPARATIVE STUDY OF PELVIC FLOOR FUNCTION IN NULLIPAROUS WOMEN USING 4D ULTRASOUND AND MAGNETIC RESONANCE IMAGING.

Hypothesis / aims of study

To compare biometric measures of pelvic floor function obtained by 4D pelvic floor ultrasound (4DUS) and magnetic resonance imaging (MRI) in a group of nulliparous young women.

Study design, materials and methods

In this prospective study, 27 nulliparous volunteers were assessed using translabial 4DUS and multiplanar 3D MRI. 4D US was performed using a Kretz Voluson 730/730 Expert with a 7-4MHz transducer. MR images were obtained using a Siemens MAGNETOM Avanto 1.5T scanner. We used a previously published imaging protocol for 4DUS[1] and duplicated this protocol as closely as possible for the magnetic resonance images.

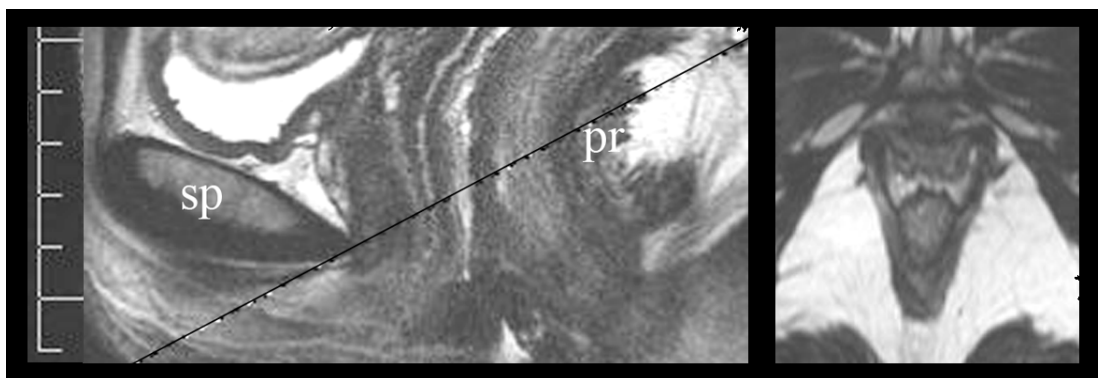


Figure 1: Identification of the hiatal plane on Magnetic resonance imaging: midsagittal plane on the left, oblique axial on the right.

The plane of minimal hiatal dimensions was defined from a mid-sagittal image as the minimum distance between the inferior edge of the symphysis pubis to the anorectal angle (see figures). All participants were imaged in the supine position after voiding as previously described[2]. Data was acquired at rest, on maximum valsalva and maximum pelvic floor contraction. Ultrasound data analysis was undertaken at a later date, using the software GE Kretz 4D View v 5.0. High resolution sagittal MR images were used to measure the anterior-posterior diameter (AP) at rest and during all manoeuvres.

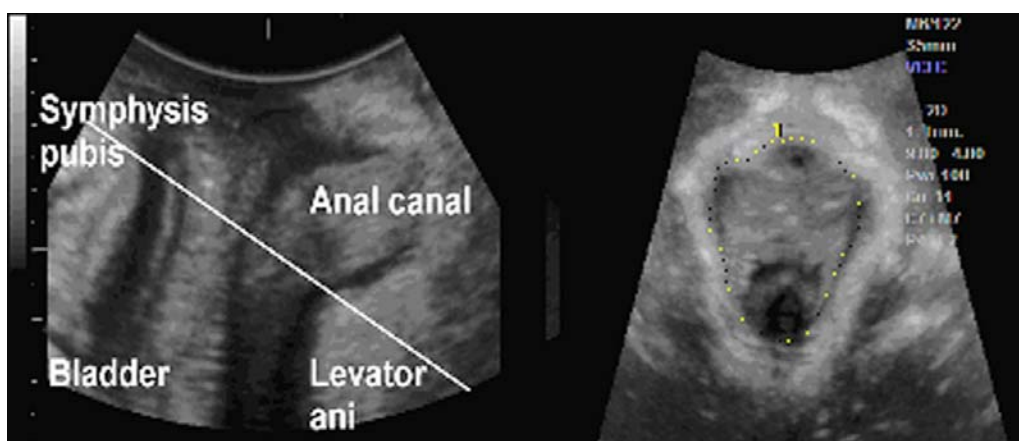


Figure 2: Identification of the hiatal plane on 4D ultrasound imaging: midsagittal plane on the left, oblique axial on the right. The small dots on the right image shows measurement of the hiatal area.

Area measures were possible using an axial MR image where the appropriate axial plane on valsalva was defined using the dynamic sagittal valsalva images. A coronal slice was used to try and verify the transverse diameter on valsalva using the dynamic axial slice as a reference. Data analysis was done by the first and second authors for 4DUS and the first and third authors for MRI. Pearson's correlation coefficient (r) was used to compare normally distributed continuous data. Intraclass correlation coefficients were used to establish reliability between the examiners for both ultrasound and the MR data. A $p < 0.05$ for the reliability coefficient was considered adequate. Formal ethical approval was obtained from the institutional ethics committee.

Results

All participants were asymptomatic for any pelvic floor dysfunction. Mean age was 29.3(range 21-41) years, mean body mass index 22.4 (range 18-29) kg/m^2 . Interobserver reliability for US data was between 0.57 and 0.81, with the

best agreement reached for levator hiatal area on Valsalva. For MRI data the two examiners had excellent agreement with all ICC's being >0.7. Correlations between the parameters measured on ultrasound and MR images are presented in Table 1.

Parameter measured	U/S		MRI		r	P
	Mean (\pm SD)	Range (cm)	Mean (\pm SD)	Range (cm)		
Sag AP diameter at rest	4.65 (0.48)	3.9-5.7	4.79 (0.54)	3.8-6.0	0.533	0.005
Sag AP diameter on Valsalva	5.01 (1.35)	3.6-7.3	5.69 (1.35)	2.9-8.0	0.658	<0.001
Sag AP diameter on PFMC	4.02 (0.43)	3.1-4.7	4.52 (0.58)	3.0-5.9	0.503	0.01
Hiatal axial area at rest	12.43 (1.86)	9.2-17.8	12.51 (2.02)	9.1-18.1	0.648	0.001
Hiatal axial area on Valsalva	17.48 (5.83)	10.6-29.0	20.37 (7.61)	6.53-36.50	0.524	0.009

Table 1: Correlations between hiatal parameters determined on ultrasound and MR imaging.

Interpretation of results

In this comparative study of 3D pelvic floor ultrasound and MRI of the levator hiatus, we endeavoured to use an identical methodology for both modalities, with careful consideration given to anatomical reference points to ensure equivalence of parameters. Overall, correlations between methods were good to moderate, but all highly significant. There was a tendency for MRI to yield higher measurements for midsagittal diameter and area on Valsalva. All measurements are largely comparable to similar data in the literature[1, 3].

Concluding message

Both ultrasound and magnetic resonance imaging are capable of determining biometric measures of the levator hiatus with good repeatability. Correlations are good to moderate for all examined measures. There are systematic discrepancies between methods for measurements during manoeuvres. These are likely due to difficulties in following the correct measurement planes on MRI for Valsalva and pelvic floor muscle contraction.

References

1. Ultrasound Obstet Gynecol, 2005. **25**: p. 580-585.
2. Ultrasound Obstet Gynecol, 2004. **23**: p. 80-92.
3. Ultrasound Obstet Gynecol, 2006. **26**: p. 710-716.

FUNDING: Bright Futures - Enterprise Scholarship

HUMAN SUBJECTS: This study was approved by the University of Auckland Human Participants and Ethics Committee and followed the Declaration of Helsinki Informed consent was obtained from the patients.