

HYDROURETERONEPHROSIS DUE TO PESSARY: A FLOW-CHART MANAGEMENT.

Hypothesis / aims of study

The use of a pessary to treat a pelvic organ prolapse (POP), or to control symptoms until surgery, is a valid non-invasive option that can improve quality of life with minor complications. However, neglected, oversized, or misplaced pessaries can lead to a severe complication such as hydroureteronephrosis (HUN), which can become critical when associated to urosepsis. The aim of our study is to present a flow chart for the management of HUN due to neglected, oversized, or misplaced pessaries.

Study design, materials and methods

We analyzed all cases of HUN caused by pessary in the literature and additionally our experience. On the basis of the most relevant, and commonly adopted steps in the diagnosis and management we developed an original flow chart.

Results

In the case of woman, usually old, with abdominal or flank pain, symptoms of uremia and/or urosepsis, the use of a pessary should be investigated. If the suspect is confirmed, the first assessment of the patient should be a vaginal examination. In case of the confirmation of pessary presence, with a concomitant increase of serum creatinine value, the suspect of a possible ureteral obstruction due the device should be considered. We suggest the use of a CT scan with contrast to investigate the presence of a HUN. If a HUN is detected in a patient with no signs of urosepsis we suggest a conservative management by the removal of the pessary. When urosepsis is suspected, it is also mandatory to administer antibiotic therapy and evaluate the HUN drainage on the basis of the clinical condition. We suggest a daily monitoring of the diuresis, and US execution after a week to confirm HUN resolution. The check of full blood tests, serum creatinine and biochemical should be considered to monitor the clinical evolution of the patient. Figure 1 shows our flow chart.

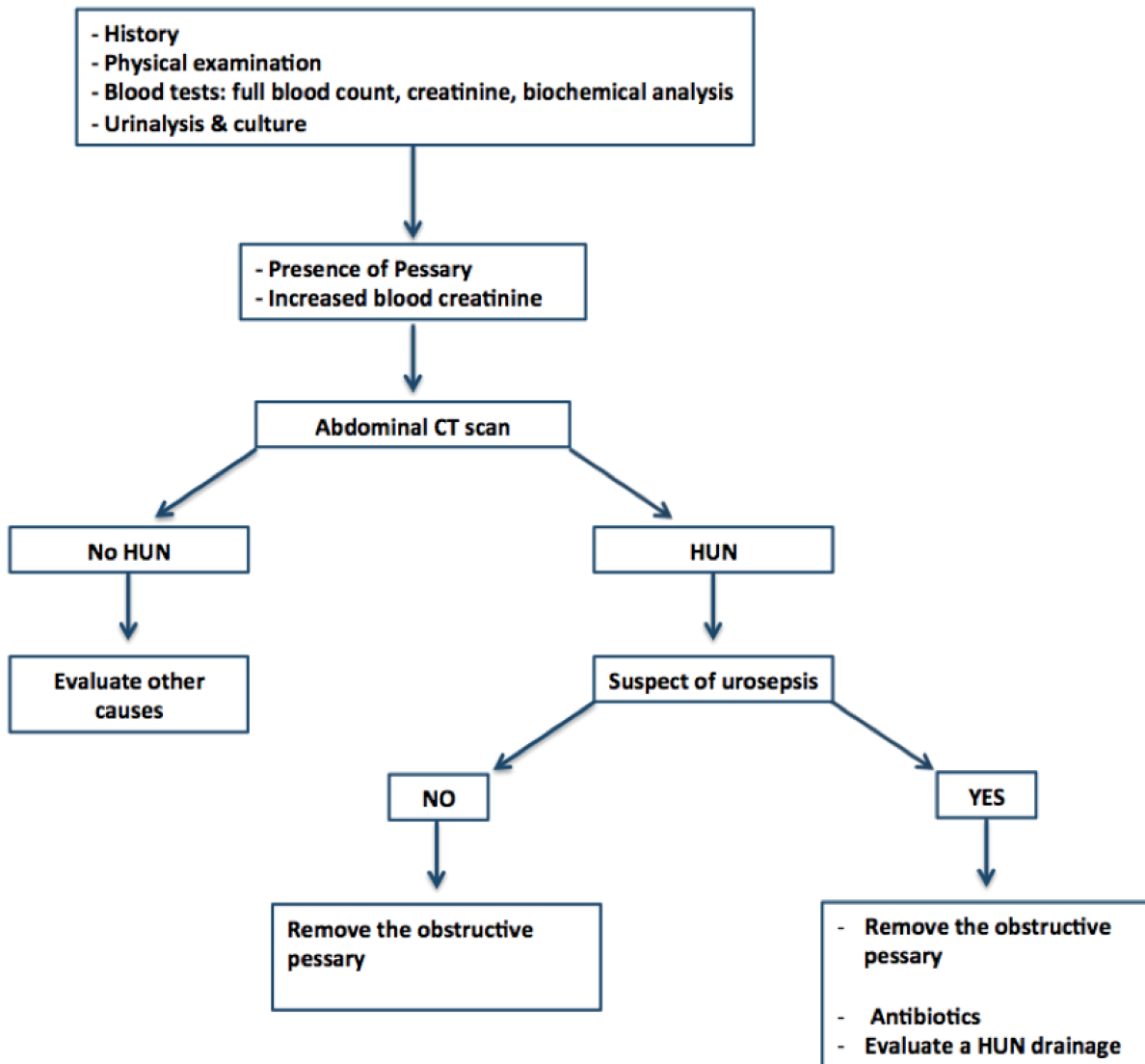
Interpretation of results

A review of the literature showed that the suspicion of the pessary as the culprit is recommended in old patients with a history of long-term pessary placement, with abdominal or flank pain, symptoms of urosepsis and/or uremia, and evidence of HUN (1). The first assessment of the patient should involve vaginal examination. Reliance on indicators used to determine when a pelvic examination is needed may lead to the omission of crucial clues for diagnosis (2,3). Pessary can create an extrinsic compression, causing obstruction often associated with acute urinary failure. CT scan enables complete evaluation of the urinary tract, showing the underlying cause of obstruction and blockage of the distal ureter. This step obviated the need for a diagnostic endoscopic approach used by some authors. If a HUN is detected in a patient with no signs of urosepsis, the simple conservative management with the removal of the pessary is the proper treatment. In patients with a concomitant urosepsis antibiotic therapy must be administered and HUN drainage must be considered. This procedure is mandatory in case of a solitary kidney. We suggest daily monitoring of diuresis, and US conducted after a week to confirm HUN resolution. The analysis of full blood tests, serum creatinine and biochemical blood tests should be considered to monitor the clinical evolution of the patient.

Concluding message

Neglected, oversized, or misplaced pessary may generate HUN causing an obstructive uropathy which is the prerequisite for a urosepsis. In these patients, it is crucial to remove the pessary, administer antibiotics in case of concomitant urosepsis and evaluate HUN drainage. We propose an original management flow chart for these cases on the basis of literature and our experience.

Figure 1: original flow chart of hydroureteronephrosis due to a pessary



References

1. 1. Duncan LE, Foltzer M, O'Hearn M. Unilateral hydronephrosis, pyelonephritis, and bacteremia caused by a neglected vaginal ring pessary. J Am Geriatr Soc. 1997 Nov;45(11):1413-4.
2. 2. Levitt MA. An evaluation of clinical variables in determining the need for pelvic examination in the emergency department. Ann Emerg Med. 1991 Apr;20(4):351-4
3. 3. Roberge RJ, McCandlish MM, Dorfsman ML. Urosepsis associated with vaginal pessary use. Ann Emerg Med. 1999 May;33(5):581-3

Disclosures

Funding: No source of founding or grant **Clinical Trial:** No **Subjects:** HUMAN **Ethics not Req'd:** Our ethics committee did not required an approval for this study because it has a retrospective evaluation of clinical data. **Helsinki:** Yes **Informed Consent:** Yes