

ANTERIOR VAGINAL MUCOSAL FLAP APPROACH FOR FEMALE URETHRAL RECONSTRUCTION IN PATIENTS WITH URETHRAL STRICTURE

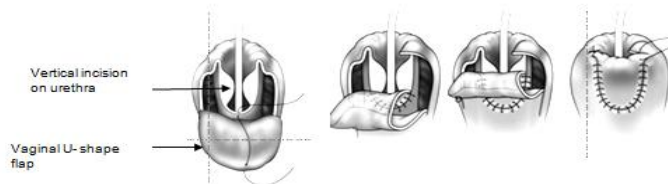
Hypothesis / aims of study

Female urethral stricture is an uncommon condition. Obstetric injuries to urethra are predominantly due to prolonged labour, particularly if maternal fetal disproportion exists, causing urethral pressure and necrosis. Although obstetric injuries are one of the important causes of urethral loss, but urethral or/and vaginal atrophy, recurrent infections and skin disease like Lichen plan can cause urethral stricture as well. Perhaps the multitude of surgical and nonsurgical approaches described attests to the quest to find a universally acceptable approach. In addition there is a big lack of evidences to determine the efficacy of the medications, pelvic floor muscle training, urethral dilatation, neuro-stimulations and acupuncture. Anterior U-shape vaginal flap technique may decrease the rate of relapse in female urethral stricture. We present our single institution experience with urethral reconstruction in ten patients using an alternative anterior vaginal flap technique inspired by the other technique.

Study design, materials and methods

Retrospective analysis of all the patients with refractory voiding lower urinary tract symptoms (LUTS) and urethral stricture was done from March 2014 to April 2016. Total of 10 patients with retention or severe voiding dysfunction and failed conservative management, were enrolled to the study. In 9 patients stricture involved the entire middle and distal urethra, and in one, it also involved the proximal urethra with bilateral hydronephrosis. Strictures in patients were due to trauma, recurrent infections, atrophic urethritis and Lichen plan diseases. All patients except one were under urethral dilatation for 1-15 years.

The charts of all women who had undergone anterior vaginal flap technique for the treatment of urethral stricture were identified and retrospectively reviewed. Demographic data points, history and vaginal examination were identified in addition to pertinent clinical and urodynamic parameters including urinary flow rate and PVR, history of UTIs, and any pertinent upper tract imaging was reviewed. Clinical follow-up included a series of standardised questions including if they voiding symptoms like reducing flow forces or calibre, hesitancy, intermittency, failure to empty, needed repeat urethral dilatation or medication for urethral stricture disease in the postoperative period or if they had symptoms of stress urinary incontinence (SUI) or de nova urgency. Woman's personal assessment of surgical success was obtained using the Patient Global Impression of Improvement (PGI-I) questionnaire with scores of 1 – 5: 1 (very much better), 2 (much better), 3 (a little better), 4 (no change), 5 (worse). Patients were placed in the dorsal lithotomy position. A small urethral Foley catheter was inserted into the urinary bladder, and the balloon was inflated with normal saline to hold it securely at the bladder neck. Two parallel anterior vaginal wall incisions around existing urethral meatus at least for 4 cm in length (depend on stricture situation) and 1.8 to 2 cm. vaginal flaps was dissected and flipped up. A vertical incision was performed on dorsal part of the urethra to pass the stricture. Then the distal end of vaginal flap sutured to proximal end of urethra and inner part of the flap was tabularized over bigger size of Foley's catheter (20F) with absorbable 3-0 Vicryl. The second layer of folded vaginal flap was sutured to native vagina with continues 3-0 Vicryl stitches as shown in the in below. Vaginal pack was kept for 24 hours. Intravenous antibiotics were given for seven days. Urethral catheter was removed after two weeks.



Results

The study was conducted on 10 patients, the average age of patients was 53.3 ± 10.04 years, and operation time 63.5 ± 10.01 minutes, the intraoperative bleeding of 182 ± 29.73 cc and duration of hospital stay was 2.7 ± 0.67 days. Average postoperative Qmax in patient 17.3 ± 2.54 ml/s and average PVR were 28 ± 13.16 cc (tab-1). During 1 year of follow-up, one of the patients had de nova urgency and one who had urgency before surgery, after surgery suffered from severe urgency incontinence, both of the patients had a convenient voiding. In postoperative urodynamic study both of the patients had overactive detrusor with normal voiding phase. After a low dose botulinum toxin injection, their symptom relatively improved.

Interpretation of results

In all the patients voiding LUTs improved or cured. In addition satisfaction rate was high in the majority of the patients. No ISD was observed in follow up of this group.

Concluding message

Anterior vaginal flap urethroplasty is a safe and effective technique that is associated with good outcomes and patients satisfaction. For this reason after a multicenter prospective trial it may be utilized in earlier steps urethral stricture management in women.

Table1- post operative results

case	age	Operative Time(min)	Blood loss	Mean duration of hospitalization	Postoperative Post void residue	Postoperative Continence	Postoperative Qmax(ml/s)	PGI
1	54	80	180	2	40	continence	17	1
2	38	75	250	2	30	continence	18	1
3	46	60	150	3	10	urgency incontinence	12	3
4	57	60	200	2	10	continence	17	1
5	44	70	170	3	20	continence	20	1
6	67	50	180	2	50	urgency	14	2
7	53	60	150	3	30	continence	20	1
8	70	70	200	3	20	continence	18	1
9	47	50	160	4	30	continence	18	1
10	57	60	180	3	40	continence	19	1

Disclosures

Funding: no funding source **Clinical Trial:** No **Subjects:** HUMAN **Ethics Committee:** Local ethics committee of Tabriz University of Medical Sciences **Helsinki:** Yes **Informed Consent:** Yes