

## FEMALE URETHRAL DIVERTICULUM CANCER: INCIDENCE, DIAGNOSIS AND MANAGEMENT

### Hypothesis / aims of study

Cancer in female urethral diverticulum is extremely rare. We have reviewed all patients having excision of urethral diverticulum to determine the incidence of urethral diverticulum cancer, mode of diagnosis, management and outcome.

### Study design, materials and methods

Pathological reports on all women having excision of urethral diverticulum between 2005-2016 were reviewed. All women had preoperative T2 pelvic MRI. Those patients with clinical (N=2) or MRI (N=3) suspicion of cancer had urgent TUR biopsies and/or transvaginal biopsies. All patients proceeded to excision of urethral diverticulum +/- Martius fat pad interposition. Further surgery for women with urethral diverticulum cancer was as determined by the urological cancer MDT and the patient.

### Results

100 women of mean age 44 years (17-77) had excision of urethral diverticulum, 3 of whom (mean age 42 years (38-55) had cancer in their diverticulum. The commonest preoperative symptoms were urethral pain (3/3) and UTI (2/3). 2/3 were noted to be 'hard' on palpation and MRI was reported as suspicious but not diagnostic of cancer in 2/3. Transurethral and transvaginal biopsy was negative for cancer in all cases. Results for MRI, biopsy and definitive histology are detailed in table 1.

One patient had anterior exenteration and radiotherapy and is alive with metastases at 72 months, one patient declined further treatment and died at 23 months and one patient had radical urethrectomy and is alive at 6 months.

### Interpretation of results

Urethral diverticulum often present with non specific symptoms. Urethral diverticulum cancer occurred in 3% of diverticulum and was adenocarcinoma in all cases.

Pre-operative biopsy is unhelpful in determining malignancy and MRI suspicion does not appear to be diagnostic of cancer.

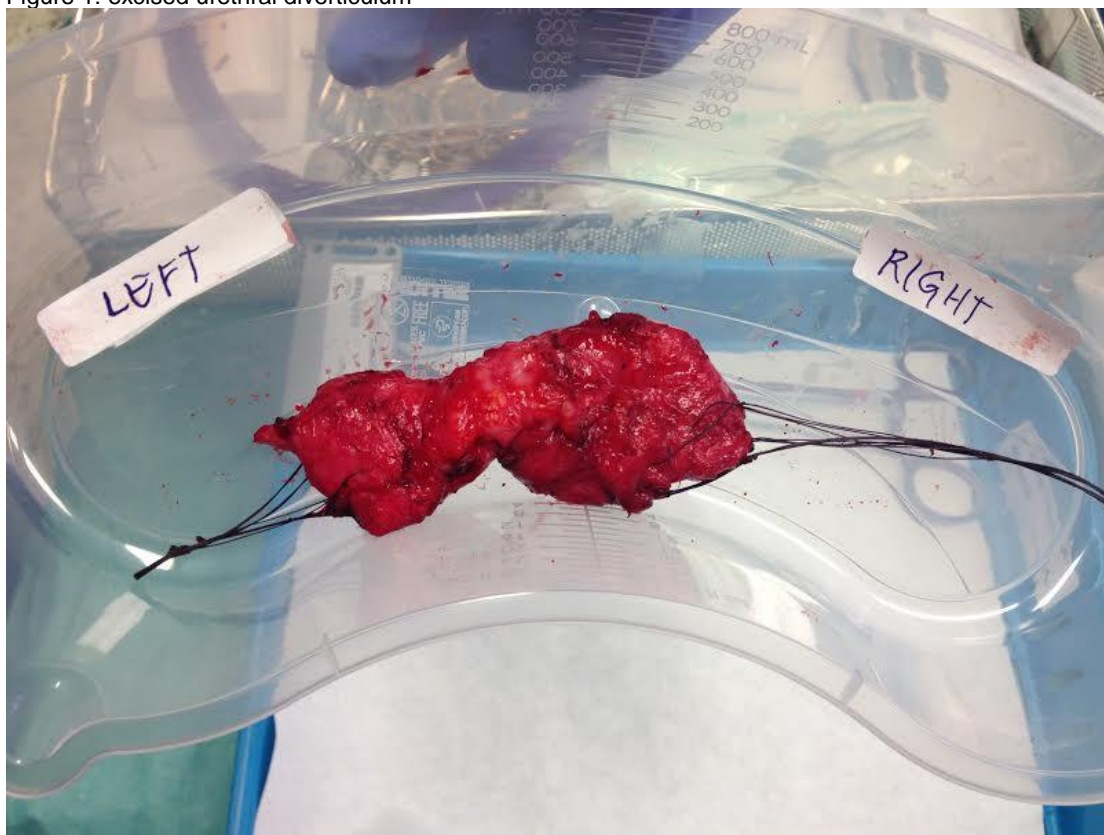
### Concluding message

All suspicious cases of urethral diverticulum should proceed to urgent diverticulum excision for definitive diagnosis.

Table 1

	Benign Diverticulum	Urethral	Malignant Diverticulum	Urethral
MRI suspicious of cancer	1/97		2/3	
Biopsy Negative	1/1		2/2	
Definitive Histology	Benign		All adenocarcinoma	
Stone in Diverticulum	3/97		0/3	
MRI Simple	19/97		1/3	
MRI Horseshoe	51/97		2/3	
MRI Circumferential	27/97		0/3	
Caucasian	82/97		0/3	

Figure 1: excised urethral diverticulum



Disclosures

**Funding:** None **Clinical Trial:** No **Subjects:** HUMAN **Ethics Committee:** UCLH NHS Foundation Trust **Helsinki:** Yes **Informed Consent:** Yes