

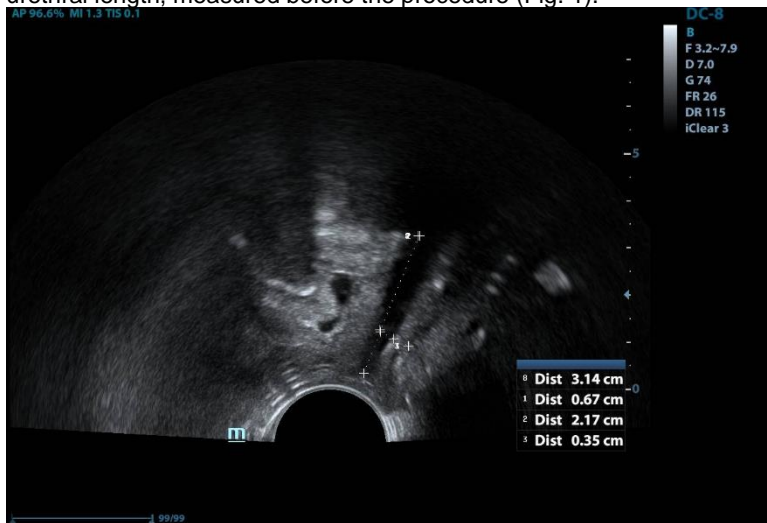DOES MID-URETHRAL SLING CHANGE ITS LOCATION IN MIDDLE TERM OBSERVATION?

Hypothesis / aims of study

Stress urinary incontinence is a worldwide health problem concerning over 30% of adult women. Mid-urethral slings are the gold standard of treatment with relatively high efficacy and safety rates. Nevertheless, approximately 10-30% of patients undergoing the procedure still suffer from persistent or recurrent incontinence. It has been suggested that the problem is connected with suboptimal sling location proximal to the bladder neck. The aim of the study was to determine whether suboptimal sling location is connected with its migration or is a result of incorrect surgery technique or another epidemiologic risk factor such as age or obesity.

Study design, materials and methods

A prospective cohort study was performed in a group of 238 patients who underwent retropubic sling implantation (TVT). Sling location was determined with the use of pelvic floor ultrasound examination and calculated relative to the individual patient's urethral length, measured before the procedure (Fig. 1).



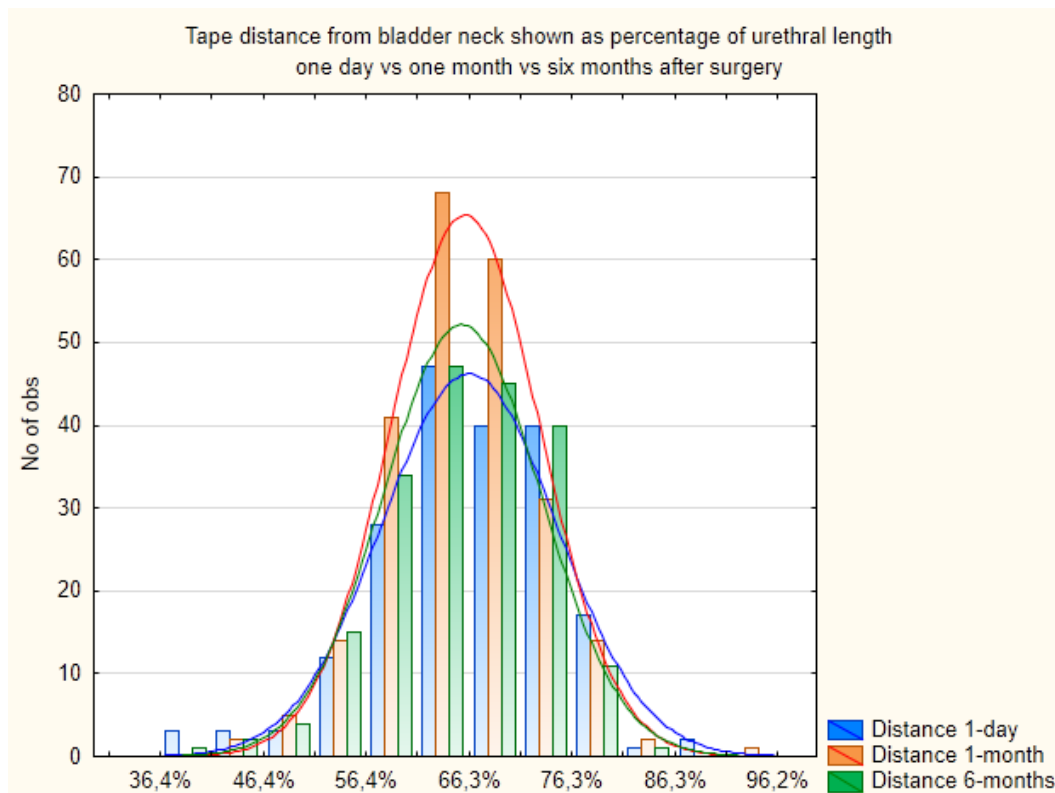
Sling location was visualized 1 day and 1 and 6 months after the surgery.

Results

Mean urethral length in the studied cohort (n= 242) was 28,76 +/-3,67mm. The distribution of the urethral length was normal (min 19,5; max 39 mm).

Mean tape position (distance from the bladder neck to the middle part of the tape) 1 day after the surgery was 21,13 +/- 3,83 mm (66,18 +/- 8,43% of the urethral length) and did not change as it was visualized one and six months after the surgery: 19,92 +/- 3,57 (65,80 +/-7,23% of urethral length) and 19,18 +/-3,53 mm (65,5 +/-7,62% of urethral length) (Fig. 2)

Figure 2. Sling location (% of urethral length) - 1 day, 1 month and 6 months post TVT implantation



The tape location shifts did not differ significantly between the analyzed groups.

Interpretation of results

As proximal sling position seems to be suboptimal for best clinical results of sub-urethral slings, there is ongoing discussion whether proximal location of the sling is connected with tape "migration" or with incorrect implantation during the surgery. The question is extremely important from the clinical point of view. Assuming that the tape location remains stable after the surgery it becomes evident that proximal positioning of the sling should be diagnosed immediately after the procedure and is connected with inappropriate surgery technique.

Our study for the first time shows stable sling location in middle term observation after the TVT procedure. We also demonstrated that the sling does not change its position, regardless of the patient's age or weight.

Concluding message

The sling location does not change after implantation in middle term observation. Therefore it appears that suboptimal sling location is a result of incorrect surgical technique and should be diagnosed and treated early after the primary surgery.

Disclosures

Funding: none **Clinical Trial:** No **Subjects:** HUMAN **Ethics not Req'd:** it is a retrospective study **Helsinki:** Yes **Informed Consent:** No