

## DESCENDING PERINEUM ASSOCIATED WITH PELVIC ORGAN PROLAPSE TREATED WITH SACRAL COLPOPERINEOPEXY AND RETRORECTAL MESH FIXATION: PRELIMINARY RESULTS

### Hypothesis / aims of study

Descending Perineum Syndrome (DPS) is a rare coloproctologic disease and the best treatment is yet to be defined. DPS is frequently associated with pelvic organ prolapse (POP) (1-2) and it is reasonable to postulate, that treatment of POP will also have an curative impact on DPS. We aimed to evaluate the subjective and objective improvement of DPS patients who have undergone a laparoscopic sacral colpoperineopexy associated with retrorectal mesh placement for concomitant POP.

### Study design, materials and methods

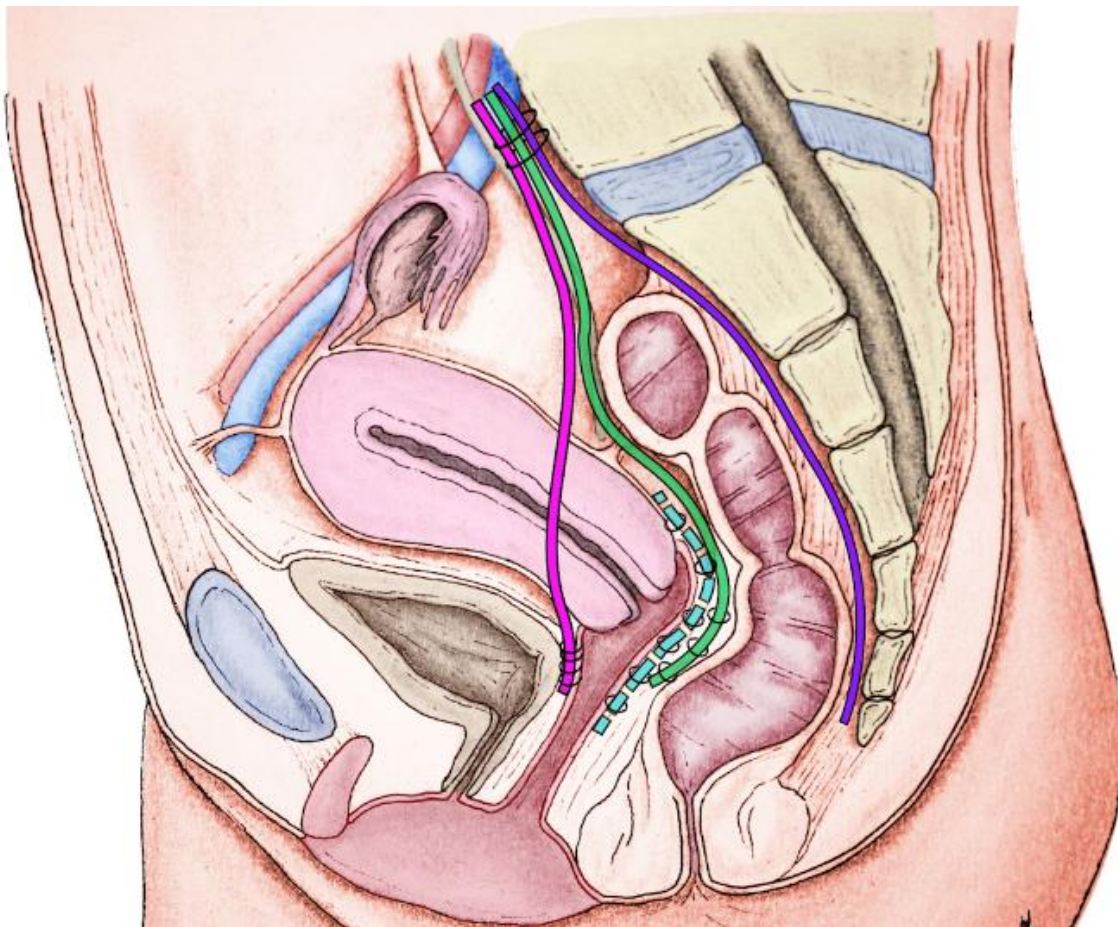
This retrospective cohort study, conducted between February 2010 and May 2016 included all women who have undergone surgery to treat POP and DPS. Improvement of POP was assessed clinically and satisfaction was assessed with a questionnaire. We used a prospective record file, specifically designed for pelviperineology patients, in order to document history and clinical examination of the urological, gynecological and coloproctologic compartment. All perineum-descending symptoms were recorded and POP was evaluated with the POP-Q system. Perineal Descent (PD) was suspected in the presence of elongation of the ano vulvar distance during straining and thinning of the intergluteal fold, later confirmed either by MRI and/or defecography. Patients with cystocele, urinary stress incontinence or occult stress urinary incontinence were referred for urodynamic assessment. All patients with fecal incontinence underwent endoanal ultrasound and Ano-Rectal Manometry (ARM).

Patients with POP and associated DPS were offered a standardized laparoscopy :

- Placement of an anterior mesh between bladder and vagina for bladder suspension,
- Placement of a dorsal mesh between rectum and sacral concavity to fix the perineum,
- Placement of a posterior mesh with uterosacral fixation in case of rectocele
- Placement of a ventral tension free mesh between vagina and rectum fixed to the promontory, in case of exteriorized rectal prolapsed or stage IV intra rectal intussusception.

All patients had postoperative assessment by the surgeon at five weeks and all patients received the questionnaire evaluating satisfaction by mail.

Differences in categorical variables between the groups were analyzed using chi-squared test (or Fisher's exact test when appropriate). Quantitative variables were reported as mean and deviation standards (or median and interquartile ranges when appropriate).



## Results

36 patients were operated, 6 lost of follow up, 30 responded to the questionnaire.

We detected a 94% objective cure rate defined by stage 0 or 1 POP at postoperative physical examination. One patient had a residual stage 2 cystocele with a good correction of hysteroptosis and another patient had a low rectocele for which she underwent vaginal perineal repair one year later. Rectal prolapse was cured in 100% of cases.

Of the 30 responders, 24 patients (80%) were satisfied with the subjective outcome of the procedure.

We investigated if medical history had an influence on the satisfaction and didn't find any statistically significant association between satisfaction and menopause, history of anorectal and POP surgery, fixed DP, ventral mesh rectopexy and hysterectomy. Patients at three-year follow up were less satisfied (62,5%) than at one year follow up (100%).

Twenty-seven patients with constipation responded to the questionnaire; one was cured (4%), 15 patients (56%) were improved, nine (33%) didn't change and two (7%) had worsening of their symptoms. Twenty-two patients with pre-operative Obstructive Defaecation Syndrome (ODS) responded to the questionnaire; Two (9%) were cured, 12 (54,5%) improved, seven (32%) didn't change and one (4,5%) had deteriorated. Twenty-two patients requiring digital maneuvers responded to the questionnaire, seven (32%) were cured, eight (36%) improved and seven (32%) did not change.

## Interpretation of results

Descending perineum is an anatomic description, and is not only frequently associated with anorectal symptoms, therefore defining the DPS, but also with rectocele which is known to induce straining (1-2). In our study population, all patients with DPS had associated POP. We hypothesized that restoration of the anatomy with the correction of both DP and POP may improve not only POP related symptoms, but also DPS, which could break the vicious circle at its root.

In our study, we observed a trend towards a negative impact of previous surgical history. Indeed, even if it does not reach statistical significance, it appears that 87% of the satisfied women have no history of POP surgery compared to only 50% with POP surgery history ( $p=0,05$ ).

Several previous studies assessed the impact of ventral mesh rectopexy for complex rectocele associated with constipation, we found an even higher reduction of 51% in defecation symptoms (3).

## Concluding message

Patients suffering from DPS are highly satisfied after treatment with laparoscopic Sacralcolpoperineopexy associated with the dorsal mesh for combined DP and POP.

A prospective long term study on the outcome of patients with DPS who have undergone this kind of surgery would be needed to confirm our results.

## References

1. Chaudhry Z, Tarnay C. Descending perineum syndrome: a review of the presentation, diagnosis, and management. *International urogynecology journal*. 2016;27(8):1149-56. doi:10.1007/s00192-015-2889-0.
2. Pucciani F. Descending perineum syndrome: new perspectives. *Techniques in coloproctology*. 2015;19(8):443-8. doi:10.1007/s10151-015-1321-6.
3. Formijne Jonkers HA, Poierrie N, Draaisma WA, Broeders IA, Consten EC. Laparoscopic ventral rectopexy for rectal prolapse and symptomatic rectocele: an analysis of 245 consecutive patients. *Colorectal disease : the official journal of the Association of Coloproctology of Great Britain and Ireland*. 2013;15(6):695-9. doi:10.1111/codi.12113.

## Disclosures

**Funding:** non **Clinical Trial:** No **Subjects:** HUMAN **Ethics not Req'd:** retrospective study **Helsinki:** Yes **Informed Consent:** Yes