

# The new method of suburethral tape visualization in vivo

Shkarupa D.<sup>1</sup>, Kubin N.<sup>1</sup>, Staroseltseva O.<sup>1</sup>, Zaytseva A.<sup>1</sup>, Shapovalova E.<sup>1</sup>, Pisarev A.<sup>1</sup>  
1. University Clinic of Saint-Petersburg State University, Department of Urology, Saint Petersburg, Russia.

## Hypothesis / aims of study

More than 20 years ago, P.Petros and U.Ulmsten proposed the Integral theory and the tension-free vaginal sling procedure, based on the role of midurethra support in urinary continence. The efficacy of this technique significantly depends on the relationship between the urethra and the implant, passed through the various structures of pelvis. This fact is confirmed by the outcomes of the surgery with use of transobturator or retropubic position of the tape as well as U-and H-type mini-slings. There is great variation in the efficacy of different sling procedures stated in different trials: 62-98%. [1] To identify better ways to insert tapes for stress urinary incontinence (SUI) treatment, and to define proper indications for each insertion technique, visualization of the implants is required. The aim of our study was to develop a new effective, safe and cheap method of synthetic midurethral sling visualization using standard radiopaque ureteral catheter.

## Study design, materials and methods

The prospective pilot study included 5 women with SUI. All patients underwent a midurethral synthetic tape placement in tension-free manner. In three cases, the surgery was performed according to standard in-out technique, described by D.Leval. [2] Two women received a retropubic sling procedure, according to U.Ulmsten [3]. All operations were performed under general anesthesia. A 5 Fr radiopaque ureteral catheter with hydrophilic coating was used as a tracer. The catheter was passed through the various structures of pelvis together with a suburethral tape in the original manner (Fig.1). At the final stage of the procedure the ends of the catheter and the distal ends of the tape were left uncut with the sterile drape closing on it. In several hours after surgery all patients underwent multispiral pelvic CT-scanning. To identify the position of the urethra, a 12 Fr Foley catheter with its balloon and lumen filled with radiocontrast solution was inserted in bladder. Pelvic examinations were obtained on 64-slice CT-scanner (Toshiba Aquilion) with slice thickness 0,5 mm. with the following 3D-reconstruction. The image analysis was performed using RadiAnt DICOM Viewer 3.4.2.13370 software.

## Interpretation of results

The coronal and saggital plane images enabled to analyze the mutual position between numerous anatomical landmarks. The oblique section was used to determine the suburethral hammock angle (Fig.3, 4). The measurement of distances between midurethra and pubic symphysis; the implant and symphysis; the pubic arch angle and suburethral hammock angle were taken in all patients.

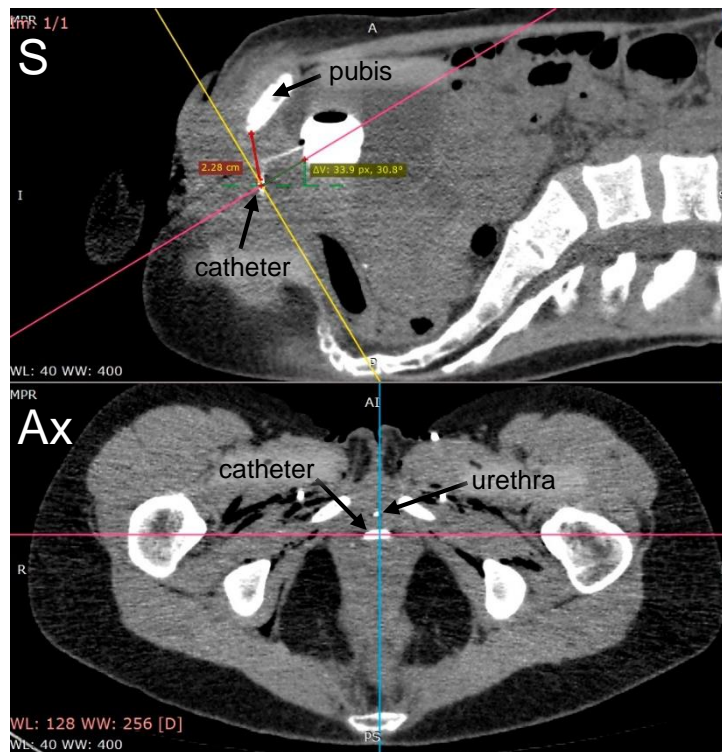


Figure 3. Saggital (S) and axial (Ax) planes

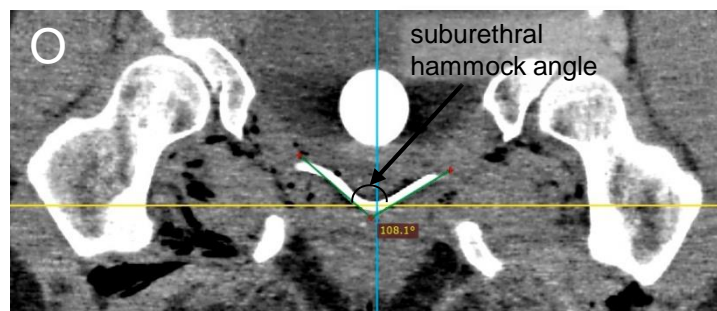


Figure 4. Oblique (O) plane

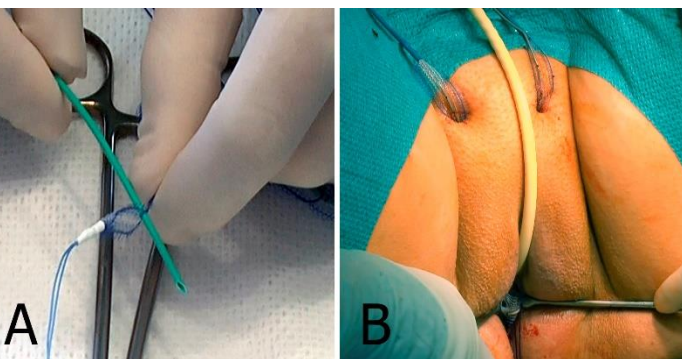


Figure 1. Implantation of the sling. The catheter is passed through the mesh (A). The tape is placed together with the catheter (B).

## Results

Mean operative time was  $14,98 \pm 2,82$  min for transobturator approach and  $22,51 \pm 6,14$  min for retropubic approach. There were no cases of intra- or postoperative complications. The ureteral catheter inserted together with the sling did not cause any additional discomfort. It was simply pulled out from the wound. This procedure was absolutely painless, so there was no need for local anesthesia. The catheter accurately repeated the path of the tape due to its flexibility, so it precisely shows the trajectory of the sling (Fig.1).

## Concluding message

The proposed method of midurethral sling contrasting is easy to perform, it is universal for any type of suburethral mesh implant. The catheter allows to clearly visualize and describe the position of midurethral sling in relation to the pelvic bones and the urethra. Further data analysis can clarify new details and improve the results of SUI surgical treatment in future.

## References

- Robert D Moore, Scott R Serels, G Willy Davila Minimally invasive treatment for female stress urinary incontinence. Expert Review of Obstetrics & Gynecology, 2008; 3(2):257-272
- De Leval J. Novel surgical technique for the treatment of female stress urinary incontinence: transobturator vaginal tape inside-out. Eur Urol. 2003;44(6):724.
- Ulmsten U, Petros P. Intravaginal slingplasty (IVS): an ambulatory surgical procedure for treatment of female urinary incontinence. Scand J Urol Nephrol 1995; 29:75-82.

## Disclosures

Funding: NONE Clinical Trial: No Subjects: HUMAN Ethics Committee: Saint-Petersburg State University Clinic Ethical Committee Helsinki: Yes Informed Consent: Yes

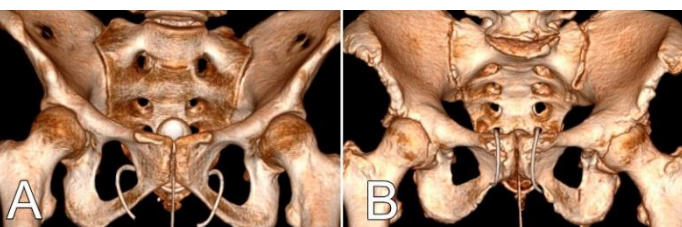

Figure 2. Position of transobturator (A) and retropubic (B) suburethral tape, anterior view