

NEUROTROPHIN AND FIBROGENESIS CYTOKINES EXPRESSION IN KETAMINE CYSTITIS BLADDERS – CORRELATION WITH CLINICAL CHARACTERISTICS

Hypothesis / aims of study

Previous studies revealed nerve hyperplasia and fibrosis in the bladder of ketamine related cystitis (KC). However, the pathogenesis of these pathologic changes was still unclear. The aim of current study is to investigate the neurotrophin expression and the fibrogenesis pathway in the KC urothelium.

Study design, materials and methods

The patients with KC who were admitted to our hospital for partial cystectomy with augmentation enterocystoplasty were enrolled into this study. The diagnosis of KC was based on previously recreational use of ketamine for at least 6 months and lower urinary tract symptoms. All patients underwent a comprehensive history review and urodynamic study. The bladder specimens was obtained from the surgery and sent to our laboratory for western blotting and immunochemical staining. Western blotting with quantification was used to investigate the expression of neurotrophin growth associated protein 43 (GAP-43), nerve growth factor (NGF) and its receptor tropomyosin receptor kinase A (TrkA) in these bladder specimens. The fibrogenic cytokine transforming growth factor beta (TGF- β) was also investigated. Immunochemical staining with 3,3' Diaminobenzidine (DAB) was also performed to verify the location of Trk-A and GAP-43 expression in the KC bladder. Bladder specimens from patients with bladder cancer and underwent radical cystectomy were also obtained for western blotting and were considered as normal control. Pearson's correlation coefficients were calculated to determine the correlations between the quantification results of western blotting and clinical symptoms scores, including Visual Analogue Scale for pain (VAS), bladder capacity and compliance in the urodynamic study.

Results

A total of 13 KC patients and 3 normal controls were enrolled. The mean age in KC patients and controls is 29.0 ± 5.4 and 54.7 ± 10.5 years old, respectively. The western blotting quantification revealed significantly higher expression of neurotrophin GAP-43 and Trk-A in the KC bladder than that in the controls (table 1 and figure 1). The fibrogenic cytokine TGF- β also significantly increased in the KC bladder. The expression of GAP-43 in KC bladders was significantly correlated with TGF- β ($r=0.714$, $p=0.001$). The GAP-43 also was significantly correlated poor bladder compliance in urodynamic study ($r=-0.548$, $p=0.022$). The DAB immunochemical staining also revealed GAP-43 and Trk-A expression in the KC bladder urothelial cells and suburothelial tissue (Figure 2).

Interpretation of results

Current study used western blotting and revealed increased neurotrophin GAP-43 in the KC bladder. The expression of NGF was not increased, but its receptor Trk-A was upregulated in the KC bladders. It suggests increased neurotrophin activity might involve the pathogenesis of KC, but the detail mechanism is still unclear. The upregulation of TGF- β suggested it play an important role in the fibrogenesis mechanism of KC bladder. The expression of GAP-43 and TGF- β was significantly correlated, and GAP-43 also negative correlated with bladder compliance. The increased neurotrophin in bladder also might be associated with fibrogenesis in KC.

Concluding message

Neurotrophin and fibrogenesis cytokines TGF- β might play an important role in the pathogenesis of KC. Increased neurotrophin expression was correlated with the upregulation of TGF- β , and may be associated with fibrogenesis in KC.

Table 1. bladder neurotrophin and fibrogenic cytokine expression in KC patients and controls

	controls (N=3)	KC (N=13)	P value
TGF- β	0.32 \pm 0.08	1.51 \pm 0.55	0.009
GAP-43	0.81 \pm 0.35	1.61 \pm 0.49	0.019
TRK-A	0.16 \pm 0.11	0.76 \pm 0.64	0.037
NGF	0.51 \pm 0.44	0.63 \pm 0.45	0.459

Figure 1. The western blotting of neurotrophin and fibrogenesis in KC and normal bladder

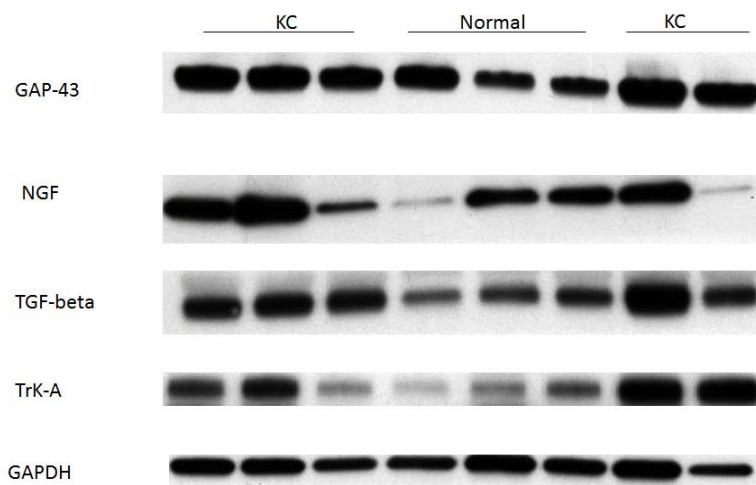
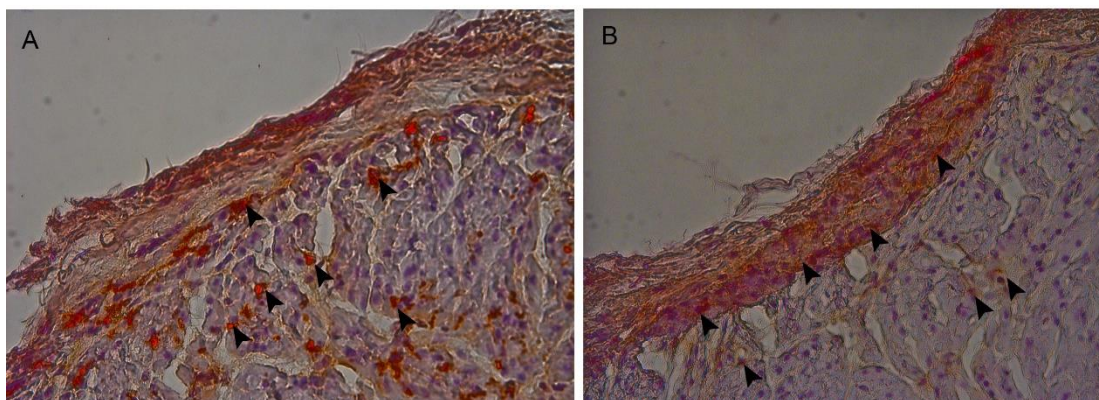


Figure 2. The urothelium GAP-46 and Trk-A expression in DAB immunochemical staining



The DAB immunochemical staining revealed (A) GAP-43 and (B) Trk-A expression in the urothelium of KC bladder. The expression could be found in urothelial cells and suburothelial tissue.

Disclosures

Funding: none **Clinical Trial:** No **Subjects:** HUMAN **Ethics Committee:** Research Ethics Committee, Hualien Tzu Chi Hospital, Buddhist Tzu Chi Medical Foundation **Helsinki:** Yes **Informed Consent:** Yes