

## **UROTHELIAL FUNCTIONAL PROTEIN AND SENSORY RECEPTORS IN PATIENTS WITH INTERSTITIAL CYSTITIS/BLADDER PAIN SYNDROME WITH AND WITHOUT HUNNER'S LESION**

### Hypothesis / aims of study

Urothelial functional protein and sensory receptors in patients with interstitial cystitis/bladder pain syndrome with and without Hunner's lesion

### Study design, materials and methods

Fourteen female IC/BPS patients with Hunner's lesion (Hunner IC) and 14 age-matched IC/BPS patients without Hunner's lesion were enrolled (non-Hunner IC) in this study. Bladder mucosa biopsy was taken and sent for histopathological review. The bladder specimen inflammation severity, eosinophil infiltration and urothelium denudation under hematoxylin and eosin stain was graded on a 4-point scale. Immunofluorescence staining and quantification of the adhesive protein E-cadherin, tryptase, zonula occludens-1 for the bladder specimens were carried out. Specimens were also investigated for urothelial muscarinic receptors M2, M3, endothelial nitric oxide synthase (e-NOS) and purinergic receptor P2X3 by western blotting.

### Results

Fourteen female IC/BPS patients with Hunner's lesion (Hunner IC) and 14 age-matched IC/BPS patients without Hunner's lesion were enrolled (non-Hunner IC) in this study. Bladder mucosa biopsy was taken and sent for histopathological review. The bladder specimen inflammation severity, eosinophil infiltration and urothelium denudation under hematoxylin and eosin stain was graded on a 4-point scale. Immunofluorescence staining and quantification of the adhesive protein E-cadherin, tryptase, zonula occludens-1 for the bladder specimens were carried out. Specimens were also investigated for urothelial muscarinic receptors M2, M3, endothelial nitric oxide synthase (e-NOS) and purinergic receptor P2X3 by western blotting.

### Interpretation of results

IC/BPS encompassed a heterogeneous spectrum of disorders, with different cystoscopic and histopathological presentations. The clinical significance and difference of pathogenesis in different subtypes are still not clear. There has been a long debate on whether Hunner IC and non-Hunner IC are different phenotypes of the same disease condition or two different disease entities. Current study revealed more defect of urothelial adhesive protein and more expression of eNOS in Hunner IC than those in non-Hunner IC. The urothelium of Hunner IC also had more severe inflammation and eosinophil infiltration than non-Hunner IC.

### Concluding message

Bladder inflammation and urothelial cell adhesion defect were more severe in the Hunner IC than that in the non-Hunner IC patients. eNOS was significantly higher in the Hunner IC bladder, suggesting eNOS might play an important role in the inflammation and angiogenesis in the bladder of Hunner IC.

Table 1. Functional protein and sensory receptor expression in Hunner and non-Hunner IC/BPS

	Group 1 Normal control (N=10)	Group 2 Hunner IC (N=14)	Group 3 Non-Hunner IC (N=14)	P-value	p-value among groups
E-cadherin	33.63 (18.97-41.15)	8.64 (4.96-20.0)	23.34 (15.27-27.14)	<0.001	1 vs 2: <0.001 1 vs 3: 0.007 2 vs 3: 0.013
ZO-1	5.31 (4.75-7.25)	4.25 (0.00-7.51)	3.63 (0.00-6.96)	0.303	1 vs 2: 0.484 1 vs 3: 0.102 2 vs 3: 0.944
Tryptase	5.45 (2.99-8.18)	5.04 (2.32-11.9)	9.94 (5.88-17.11)	0.025	1 vs 2: 0.944 1 vs 3: 0.012 2 vs 3: 0.048
TUNEL	0.39 (0.00-0.68)	3.57 (0.91-7.42)	1.86 (0.00-3.38)	0.005	1 vs 2: 0.002 1 vs 3: 0.035 2 vs 3: 0.127
M2	1.17 (0.58-1.75)	0.55 (0.22-1.00)	1.09 (0.77-1.38)	0.082	1 vs 2: 0.072 1 vs 3: 0.806 2 vs 3: 0.028
M3	1.43 (0.72-2.42)	0.62 (0.33-1.11)	0.60 (0.32-0.90)	0.004	1 vs 2: 0.027 1 vs 3: 0.001 2 vs 3: 0.619
P2X3	1.57 (0.63-2.26)	1.08 (0.43-1.59)	1.46 (0.72-3.23)	0.161	1 vs 2: 0.099 1 vs 3: 0.675 2 vs 3: 0.091
β3-AR	0.47 (0.22-0.94)	0.48 (0.34-0.64)	0.76 (0.25-0.99)	0.469	1 vs 2: 0.832 1 vs 3: 0.613 2 vs 3: 0.143
eNOS	0.23 (0.16-0.40)	0.40 (0.30-0.50)	0.05 (0.02-.014)	<0.001	1 vs 2: 0.089 1 vs 3: <0.001 2 vs 3: <0.001

ZO-1: zonula occludens protein 1; TUNEL: terminal deoxynucleotidyl transferase dUTP nick end labeling; eNOS: endothelial nitric oxide synthase, β3-AR: beta-3 adrenoceptor

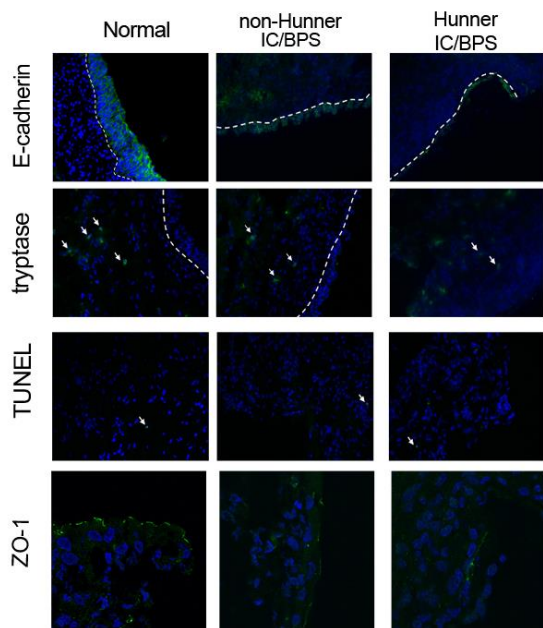


Fig. 1. Immunohistochemical staining of the urothelium in Hunner IC and non-Hunner IC revealed that the urothelium of Hunner IC had more defect of E-cadherin than non-Hunner IC.

**Disclosures**

**Funding:** none **Clinical Trial:** Yes **Public Registry:** No **RCT:** No **Subjects:** HUMAN **Ethics Committee:** Research Ethics Committee, Hualien Tzu Chi Hospital, Buddhist Tzu Chi Medical Foundation **Helsinki:** Yes **Informed Consent:** Yes