

## THE MEASUREMENT AND ASSESSMENT OF RECTOCOELE USING TOTAL PELVIC FLOOR ULTRASOUND AND PROCTOGRAPHY

### Hypothesis / aims of study

A rectocele is the protrusion of the rectum into the vagina, is common in multiparous, postmenopausal women and is associated with pelvic floor defaecatory dysfunction.

Currently gold standard imaging techniques for rectocele assessment include defaecation proctography and dynamic MRI. Defaecation proctography entails radiation exposure and only images the rectum. Dynamic MRI images the entire pelvic floor but is expensive and inaccessible. Total pelvic floor ultrasound (PFUS) avoids ionising radiation and is a less invasive test which allows the diagnosis and measurement of a rectocele. If we could rely upon PFUS for diagnosis and assessment we may be able to avoid proctography in some women.

This study assesses;

- inter- and intra- rater repeatability of rectocele diagnosis and measurement by PFUS (specifically transperineal ultrasound) and proctography,
- correlation between rectocele diagnosis and subsequent measurement using these two imaging modalities.

### Study design, materials and methods

The retrospective review of dynamic images of 66 women for PFUS and defaecation proctography were independently reviewed by four interpreters blinded to clinical symptoms and results.

Transperineal ultrasound was performed on coughing, squeezing and bearing down. Rectocele measurement on ultrasound was determined by protrusion of the rectal wall beyond the perineal body into the vagina. Defaecation proctography was performed with rectal and oral contrast. Rectocele measurement on proctography was the distance beyond a single line from the projected anterior rectal wall to the furthestmost point of the rectocele.

Bland Altman analysis was performed to determine agreement.

### Results

The mean measurement of rectocele on PFUS was 1.7 cm (median 1.5, range 0 – 4). The mean measurement on defaecation proctography was 2.1 cm (median 2, range 0 – 7).

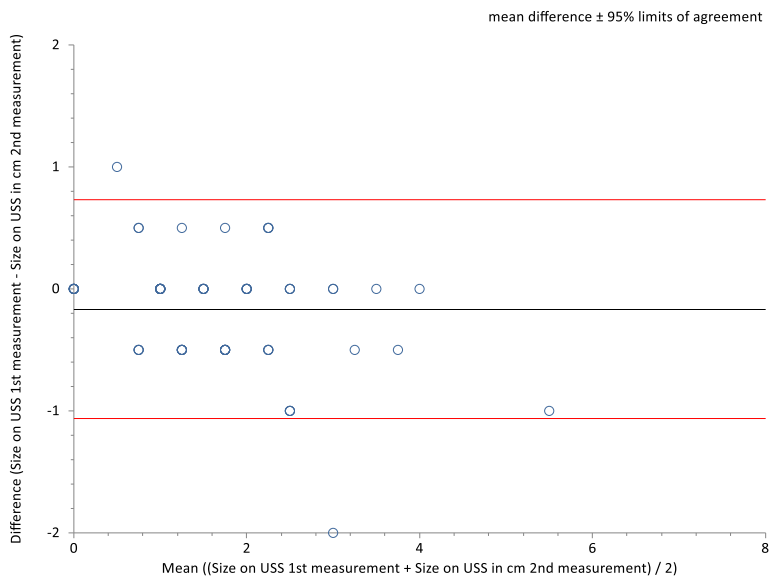
There was good intra rater agreement for rectocele measurement on proctography. The intra class correlation coefficient was 0.71. The mean difference was 0.03cm with a 95% confidence interval of -0.16 to 0.21. The limits of agreement were -1.7 to 1.7.

There was good inter rater agreement for rectocele measurement on defaecation proctography. The intra class correlation coefficient was 0.84. The mean difference was -0.09cm with a 95% confidence interval of -0.21 to 0.02. The limits of agreement were -1.2 to 1.01.

There was good intra rater agreement for rectocele measurement on PFUS. The intra class correlation coefficient was 0.9. The mean difference was -0.16cm with a 95% confidence interval of -0.27 to -0.05. The limits of agreement were small (-1.06 to 0.73). This is shown in figure 1.

There was also good inter rate agreement for rectocele measurement on PFUS. The intra class correlation coefficient was 0.78. The mean difference was -0.007cm with a 95% confidence interval of -0.19 to 0.18. The limits of agreement were also small (-1.53 to 1.51).

Figure 1: Intra rater agreement for rectocoele measurements using PFUS.



There was moderate agreement between rectocoele measurement on PFUS and that on proctography (intra-class correlation coefficient 0.46). There was a strong positive correlation between measurements on PFUS compared to proctography (correlation coefficient 0.59). Rectocoele measurement was 1.25 cm larger on proctography than on ultrasound.

Interpretation of results

The measurement of rectocoeles on both proctography and PFUS shows good inter – and intra – rater repeatability. There is a strong positive correlation between measurements on PFUS and proctography with measurements being larger on defaecation proctogram compared with PFUS.

Concluding message

There is a good correlation between measurements using ultrasound compared with proctography. Not surprisingly, measurements are larger with proctography where protrusion of the rectal wall is measured in contrast to ultrasound which measures the protrusion over the perineal body into the vagina. Clearly, proctography may over-diagnose rectocoele. The next main consideration is how size on each modality correlates with function and clinical symptoms.

Disclosures

**Funding:** None **Clinical Trial:** No **Subjects:** HUMAN **Ethics not Req'd:** Review of imaging already performed **Helsinki:** Yes **Informed Consent:** No