

## THE THERAPEUTIC EFFICACY OF HUMAN UMBILICAL CORD BLOOD-DERIVED MESENCHYMAL STEM CELLS (UCB-MSCS) ON KETAMINE INDUCED CYSTITIS

### Hypothesis / aims of study

Ketamine use as a recreational drug is on a rapid increase in young people. Many reports have shown that long-term ketamine abuse is liable to lead to lower urinary tract symptoms that resemble interstitial cystitis (IC). IC is a disease characterised by severe and chronic pelvic pain with frequency, urinary urgency, and nocturia in the absence of bacterial infection or other diseases. This study evaluated the therapeutic effect of human umbilical cord blood derived mesenchymal stem cells (UCB-MSCs) in a ketamine induced cystitis (KC) rat model.

### Study design, materials and methods

For KC rat models 10-week-old, female Sprague-Dawley rats were used. Sham treatment (n=5) rats were assigned to the control group. The rats in the KC group (n=10) and KC+MSCs group (n=9) were intravenously injected with ketamine at a dose of 25 mg/kg for 5 days a week over a duration of 2 weeks. After one week,  $1 \times 10^6$  UCB-MSCs were directly injected into the submucosal layer of the anterior wall and dome of the bladder in KC+MSCs group. The cystometric parameters and immunohistochemical results (Toluidine-Blue, Masson Trichrome, TUNEL staining) were measured at one week following the intervention.

### Results

Most rats in the KC group exhibited irregular voiding frequency and decreased inter-contraction interval in comparison with the control group ( $118.8 \pm 34.3$  vs  $306.5 \pm 138.5$  seconds, respectively;  $p < 0.05$ ). The KC+MSCs group demonstrated improvement in most voiding parameters to normal levels within 1 week. A single injection of UCB-MSCs significantly increased the inter-contraction interval ( $339.0 \pm 131.2$ ,  $p < 0.05$ ) (Figure 1). In immunohistochemical analysis, the bladders in KC group were characterized by mast cell infiltration in Toluidine-Blue staining, fibrosis in Masson Trichrome staining and apoptosis in TUNEL staining which were significantly ameliorated in the bladders in the KC+MSCs group (Figure 2).

### Interpretation of results

The injection of UCB-MSCs restored the damaged bladder and associated pathologies including mast cell infiltration, fibrosis and apoptosis in the KC rat model.

### Concluding message

Stem cell therapy could be valuable treatment option for painful bladder conditions such as ketamine induced interstitial cystitis.

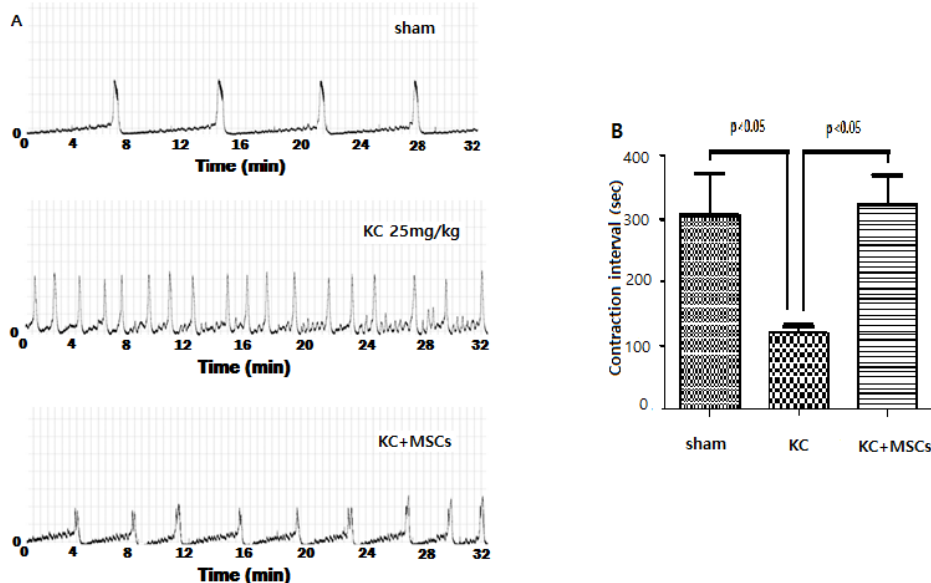
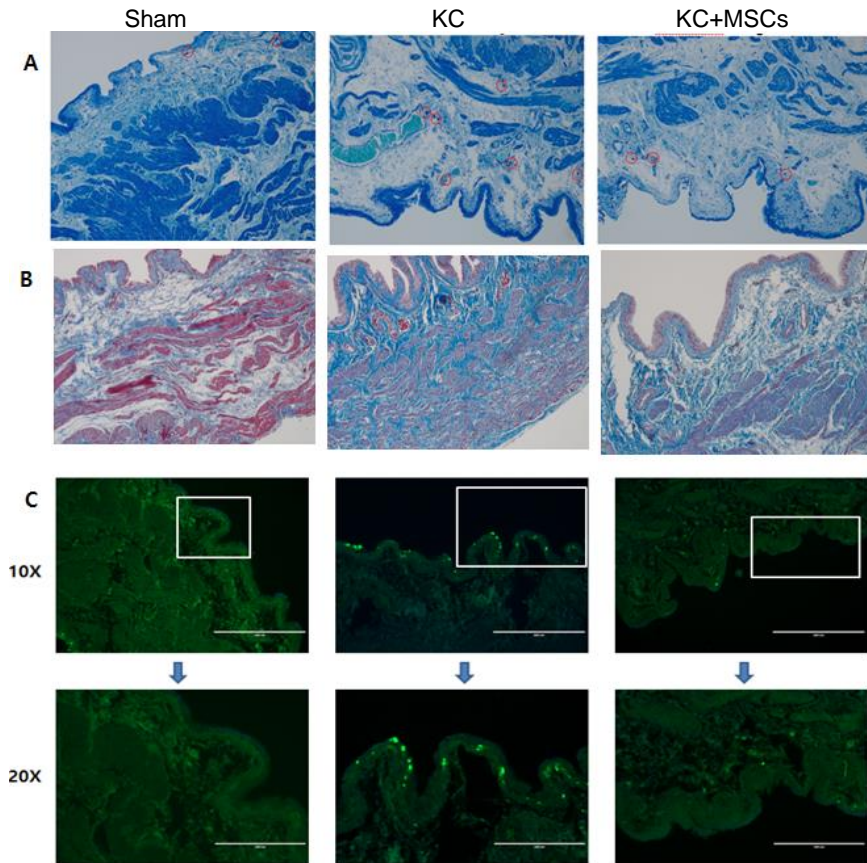


Figure 1. UCB-MSC injection improved voiding function in an KC bladder.

(A) Cystometry results and (B) Contraction intervals.



**Figure 2. UCB-MSC therapy ameliorated immunohistologic abnormalities in KC bladder.**

(A) Toluidine-Blue staining (magnificationx100). Red circles indicate mast cell. (B) Masson Trichrome staining (magnificationx100). Blue dye indicates fibrosis. (C) TUNEL staining (magnificationx100 and x200) Bright green dots indicate apoptotic cells.

Disclosures

**Funding:** the Basic Science Research Program through the National Research Foundation of Korea (NRF) funded by the Ministry of Education, Science, and Technology (2013R1A1A2004678) **Clinical Trial:** No **Subjects:** ANIMAL **Species:** rat **Ethics Committee:** Asan medical center