

HISTOLOGICAL ANALYSIS OF THE USE OF PLATELET-RICH PLASMA (PRP) IN THE INTEGRATION OF IMPLANTED POLYPROPYLENE MESHES WITH RABBITS' VAGINAL MUCOSA

Hypothesis / aims of study

The polypropylene meshes have been applied at gynaecology for the correction of pelvic floor dysfunction and the stress urinary incontinence (SUI). However, it still features significant rates of complications, probably due to an inappropriate inflammatory response [1]. The platelet-rich plasma has been used successfully in several areas of medicine, providing a better process of wound healing as a result of its high amount of growth factors [2]. The aim was to study the effect of the impregnation of platelet-rich plasma (PRP) in the integration of monofilament polypropylene mesh implanted in the rabbits' vagina.

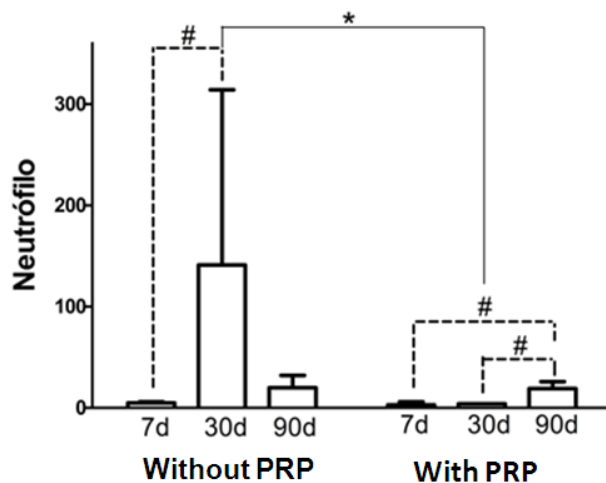
Study design, materials and methods

Thirty adult female New Zealand rabbits were submitted to monofilament polypropylene mesh implant surgery in their vaginas. In 15 of them a PRP gel was also deposited on the meshes. The rabbits were divided into 3 groups of 10 rabbits (5 with and 5 without PRP) and sacrificed at 7, 30 and 90 days after surgery for the extraction of both their vaginal mucosa and mesh. The PRP was obtained using the protocol for human beings described by Anitua et al. with modifications. The evaluation of the infiltrated inflammatory was made through the counting of neutrophil using eosin-haematoxylin staining. The collagen types I and III deposition were evaluated by picosirius and trichrome of Masson staining. The results were presented using the median and interquartile range (P75-P25) and submitted to the Shapiro-Wilk and Levene tests, respectively. Due to normality violation, data were treated with non-parametric tests. The Mann-Whitney and Kruskal-Wallis tests followed by a multiple comparison test as suggested by Bonferroni $p < 0.05$.

Results

After 30 days there were significant differences in the intensity of inflammatory infiltrate between the groups with and without PRP (figure 1).

Figure 1 - Analysis of the results obtained for inflammatory infiltrate per field by comparing the presence or absence of PRP.

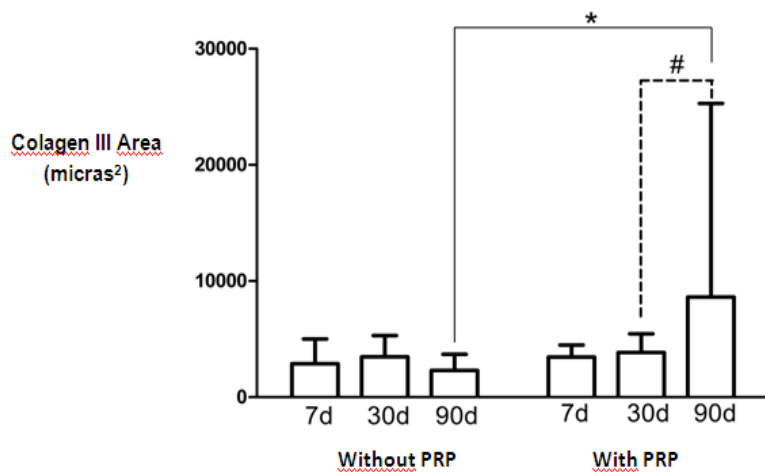


$P < 0,05$ without PRP x with PRP (test Mann-whitney)

* $P < 0,05$ comparing days (test Kruskal-Walis)

The group with PRP showed lower values of inflammatory infiltrate compared with the group without PRP. After 90 days, there was an increase in the production of collagen type III when using PRP (figure 2).

Figure 2 - Results of type III collagen in different euthanasia times for the groups with and without PRP.



$P < 0,05$ Without PRP x with PRP test Mann-Whitney.

* $P < 0,05$: Comparing days; test Kruskal-Wallis

median and interquartile range (P75-P25)

Interpretation of results

The acute inflammatory reaction occurred similarly in rabbits euthanized 7 days, with and without PRP, suggesting that the use of PRP did not affect the initial inflammatory phase. Gerullis et al. in an animal study found that the use of plasma did not influence the early inflammatory reaction, but the inflammatory processes of medium and long term [3]. In rabbits sacrificed after 90 days in the group PRP was a statistically significant increase in type III collagen fibers, the first to be produced. It is possible that the PRP does not alter the late production of collagen, decreasing the risk of over foreign body reaction, acting in the early stages of the repair process.

Although further studies are required with the use of PRP on mesh implants in ovariectomized rabbits, aged, and compare the results with those of this current study.

Concluding message

There was no change in the immediate inflammatory response (7 days) using the PRP. After 30 days, there was a significant increase in the inflammatory infiltrate in the group without the PRP, a change that was not noted in the group with PRP. This observation indicates a reduction of the inflammatory response. There was a significant increase in collagen type III after 90 days of the study.

References

1. Almeida SHM, Rodrigues MAF, Gregório E, Crespígio J, Moreira HA: Influence of sling material on inflammation and collagen deposit in an animal model. *Int J Urol.* 2007; 14: 1040-1043.
2. Marx RE: Platelet-rich plasma: evidence to support its use. *J Oral Maxillofac Surg.* 2004; 62(4): 489-496. Platelet-rich plasma: evidence to support its use
3. Gerullis H et al: Coating with autologous plasma improves biocompatibility of mesh grafts in vitro: development stage of surgical innovation. 2013; *Biomed Research International.* 2013; 1-6.

Disclosures

Funding: None **Clinical Trial:** No **Subjects:** ANIMAL **Species:** Rabbit **Ethics Committee:** Comitê de Ética no Uso de Animais em Pesquisa da Universidade Estadual de Londrina