

## REDUCED EXPRESSION OF ESTROGEN RECEPTOR- $\alpha$ (IN PATIENTS WITH BLADDER PAIN SYNDROME/INTERSTITIAL CYSTITIS

### Hypothesis / aims of study

It has been reported that chronic inflammation and epithelial cell apoptosis are prevented by 17 $\beta$ -estradiol replacement due to the estrogen receptor- $\alpha$  (ER $\alpha$ ) activation (Refs. 1, 2). Thus, we examined the expression of ER $\alpha$  in bladder biopsy specimens from patients with bladder pain syndrome/interstitial cystitis (BPS/IC).

### Study design, materials and methods

Bladder mucosal biopsies were obtained from 11 BPS/IC patients (male; 6, female; 5) with Hunner's lesion (HL) and in 8 BPS/IC patients (male; 2, female; 6) with non-Hunner's lesion (NHL) after hydrodistention. Normal bladder mucosae were obtained from 11 patients (male; 6, female; 5) who underwent surgeries for stress urinary incontinence or benign prostatic hyperplasia (control). Immunohistochemical staining for CD3, which is a T cell marker associated with tissue inflammation and immune responses, E-cadherin, which is an adhesion molecule expressed in the epithelium, and ER $\alpha$  were performed in each bladder specimen. The number of CD3 and ER $\alpha$  positive cells and expression level of E-cadherin were measured at x200 magnification and expressed as mean values of 4 different sites in each specimen using image J software.

### Results

There was no significant difference among the age of control ( $68 \pm 11$  years), HL ( $62 \pm 10$  years) and NHL ( $59 \pm 16$  years) groups. The expression of ER $\alpha$  positive cells, which were expressed in both urothelium and suburothelial layers (Fig.1A), was significantly lower in HL specimens than in control specimens although there was no significant difference in the ER $\alpha$  expression between NHL and control specimens. The expression of CD3 positive cells, which were also expressed in both urothelium and suburothelial layers (Fig.1B), was significantly higher in HL specimens compared with controls although there was no significant difference in the CD3 expression between NHL and control specimens. The expression level of E-cadherin, which was only expressed in the urothelium (Fig.1C), was significantly lower in HL specimens than in control specimens although there was no significant difference in the E-cadherin expression between NHL and control specimens. In addition, there was a significantly negative correlation between the expression of ER $\alpha$  and CD3 ( $r = -0.41$ , Fig.2A), and a significantly positive correlation between the expression of ER $\alpha$  and E-cadherin ( $r = 0.66$ , Fig.2B) in control, HL and NHL specimens.

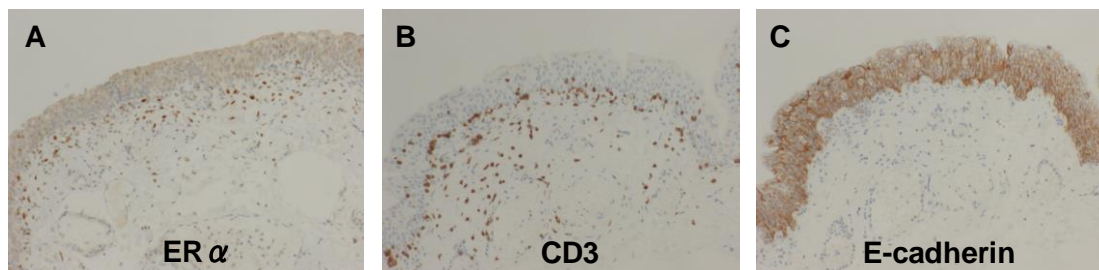


Fig. 1. Representative photomicrographs showing the positive staining of ER $\alpha$  (A), CD3 (B) and E-cadherin (C) in bladder sections from a control patient. x200 magnification

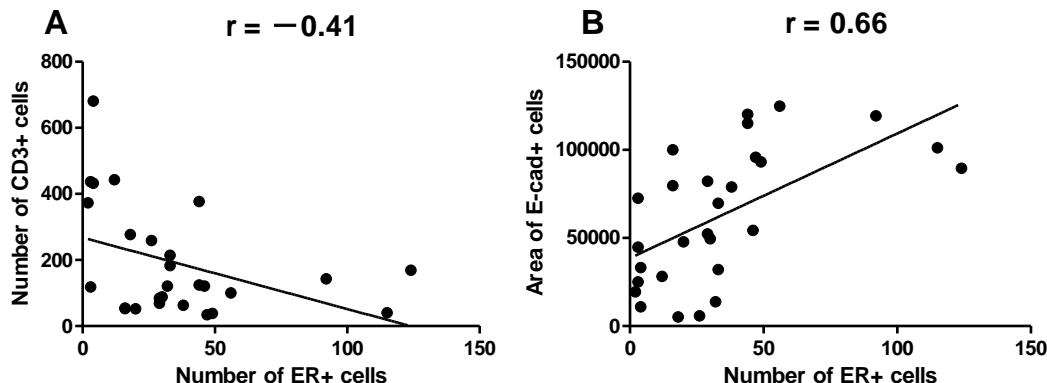


Fig. 2. Correlations between the expression of ER $\alpha$  and CD3 (A) and the expression of ER $\alpha$  and E-cadherin (B) in control, HL and NHL specimens.

### Interpretation of results

These results demonstrate that; (1) BPS/IC with HL is associated with chronic bladder inflammation indicated by increased CD3 expression, (2) reduced expression of ER $\alpha$  is associated with chronic bladder inflammation (i.e., increased CD3 expression) in BPS/IC specimens, especially those with HL, (3) E-cadherin in the urothelium is reduced in the HL-type of BPS/IC patients, whose

bladders often show thinning or denudation of the urothelium, and (4) reduced expression of ER $\alpha$  is also associated with urothelial dysfunction (i.e., decreased E-cadherin expression).

#### Concluding message

Because ER $\alpha$  stimulation is known to prevent chronic inflammation and epithelial cell apoptosis (Refs. 1, 2), the reduced expression of ER $\alpha$  in urothelial and suburothelial layers could contribute to impaired urothelial function and chronic bladder inflammation, which are the important pathogenesis of BPS/IC. Thus, ER $\alpha$  expression could be a useful marker for the pathological detection of BPS/IC, especially in the HL type.

#### References

1. Maret A et al., Eur J Immunol 33, 512-21, 2003
2. Acconcia F et al., J Cell Physiol 203, 193-201, 2005

#### Disclosures

**Funding:** None **Clinical Trial:** No **Subjects:** HUMAN **Ethics Committee:** The ethics committee of Jikei University School of Medicine **Helsinki:** Yes **Informed Consent:** Yes