

## DISPLACEMENTS OF PELVIC FLOOR STRUCTURES DURING VOLUNTARY PELVIC FLOOR MUSCLE CONTRACTION IN CONTINENT AND INCONTINENT MEN AFTER RADICAL PROSTATECTOMY MEASURED WITH TRANSPERINEAL ULTRASOUND.

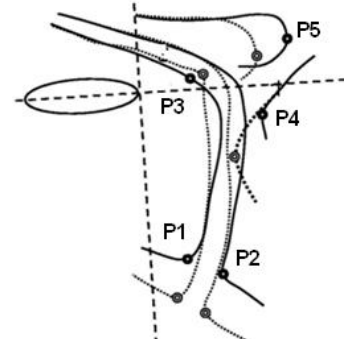
### Hypothesis / aims of study

Urinary incontinence remains a common problem after radical prostatectomy. Until now, most research concerning the visualization by imaging of continence mechanisms was focused on women. Literature in men is however rather scarce (1-3). The aims of our study were to provide reliability data of the displacement of pelvic floor structures during voluntary contraction by analyzing transperineal ultrasound images and to compare the displacements in continent and incontinent men after radical prostatectomy.

### Study design, materials and methods

Eight continent and 8 incontinent men minimum 11 months after radical prostatectomy were measured using transperineal ultrasound. Five points of interest (the ventral and dorsal aspect of the urethrovesical junction, the most dorsal point of the striated urethral sphincter, the most ventral point of the anorectal junction and the most dorsal point of the bulb of the penis) were investigated (Fig. 1). All images were immediately analyzed on the ultrasound device, without using additional software packages. Intra- and interobserver reliability was assessed using intraclass correlation coefficients (2,1 and 2, k), respectively. Mann-Whitney U-tests were used to compare mean displacement values between continent and incontinent patients.

**Figure 1: Explanation of the different points of interest (Adapted from (1) (with permission from authors))**



Point	Location
P1	Inflection point of ventral aspect of urethrovesical junction (ventral UVJ)
P2	Inflection point of dorsal aspect of urethrovesical junction (dorsal UVJ)
P3	Most dorsal point of striated urethral sphincter
P4	Ventral-most point of anorectal junction (ARJ)
P5	Most dorsal point of the bulb of the penis

### Results

Mean age of the continent group was 61.8 years (SD 7.54) and 65.9 years (SD 7.54) for the incontinent group (p=0.231). In both groups, 5 patients underwent open and 3 patients underwent robot radical prostatectomy. The mean duration of urinary incontinence was 45 days (range 13-114 days) in the continent group and 3 years and 7 months (range 11 months- 7 years 1 month) in the incontinent group.

Intra-observer reliability was good to excellent for the measurement of displacement of all points of interest. Inter-observer reliability was excellent for the measurement of the displacement of the ventral and dorsal urethrovesical junction and the bulb of the penis, and good for the displacement of the anorectal junction. However the confidence interval for the latter point was rather large. The striated urethral sphincter could not be measured reliably between observers (Table 1). Comparison of continent and incontinent men showed that only the displacement of the most dorsal point of the bulb of the penis differed significantly between both groups, whereby continent men had a larger displacement during maximal voluntary contraction (Table 2). Furthermore all images were immediately analyzed on the ultrasound device, without the use of additional software packages, which is of paramount importance for clinicians.

**Table 1: Inter-observer reliability (in 8 incontinent patients)**

Location	Mean (SD)	SEM	ICC	95% CI
UVJ ventral	6.6 (2.35)	1.24	0.837	0.286-0.966
UVJ dorsal	8.64 (3.35)	1.30	0.918	0.329-0.985
SUS	6.41 (1.69)	1.73	-0.099	-1.365-0.701
ARJ	16.36 (3.99)	2.80	0.674	-0.415-0.950
BU	8.39 (2.74)	1.43	0.843	0.301-0.968

Mean, standard deviation (SD), standard error of measurement (SEM), intra-correlation coefficient (ICC) and 95% confidence interval (CI) are presented for all points of interest and both observers

**Table 2: Mean displacements of the points of interest for continent and incontinent patients**

Location	Incontinent patients		Continent patients		p-value
	Mean (SD)	Range	Mean (SD)	Range	
UVJ ventral	6.99 (2.90)	2.21-11.08	7.84 (2.09)	5.52-12.08	0.487
UVJ dorsal	9.34 (3.73)	4.53-16.24	8.9 (3.19)	5.30-15.48	0.674
SUS	7.25 (1.95)	5.65-10.04	5.68 (1.95)	3.80-8.43	0.172

ARJ	16.92 (4.84)	11.32-25.39	12.45 (5.24)	6.18-18.86	0.180
BU	8.78 (3.43)	4.37-14.75	13.98 (3.37)	10.67-19.99	0.016

Mean, standard deviation (SD), standard error of measurement (SEM), intra-correlation coefficient (ICC) and 95% confidence interval (CI) are presented for all points of interest and both observers

#### Interpretation of results

Intra-observer reliability was good to excellent for both observers and for all points of interest, indicating that the displacement of the pelvic floor can be measured reliably by the same observer using transperineal ultrasound. Inter-observer reliability assessment showed that the striated urethral sphincter could not be reliably measured. The measurement of the anorectal junction had good inter-observer reliability; its rather large confidence interval however indicates that this point has to be interpreted with caution. Based on our results, the anorectal junction and the most dorsal point of the striated urethral sphincter ideally should be assessed by the same rater. The most dorsal point of the bulb of the penis was the only pelvic floor structure with a significant larger displacement during maximal voluntary contraction in continent compared to incontinent men. A potential explanation could be that the continent group has a better ability to close the urethra than the incontinent group, though further research is warranted to fully understand the role of the different pelvic floor structures in a patient's continence status.

#### Concluding message

Transperineal ultrasound is a reliable and clinically feasible measurement method to assess voluntary pelvic floor muscle contraction in men after radical prostatectomy. All points of interest can be analyzed immediately on the ultrasound device. The bulb of the penis has a larger displacement during contraction in continent compared to incontinent men.

#### References

1. Stafford RE, Ashton-Miller JA, Constantinou CE, Hodges PW. Novel Insight into the Dynamics of Male Pelvic Floor Contractions Through Transperineal Ultrasound Imaging. *The Journal of Urology*. 2012;188(4):1224-30.
2. Kirschner-Hermanns R, Najjari L, Brehmer B, et al. Two- and three-/four dimensional perineal ultrasonography in men with urinary incontinence after radical prostatectomy. *BJU International*. 2012;109(1):46-51.
3. Davis SN, Morin M, Binik YM, Khalife S, Carrier S. Use of Pelvic Floor Ultrasound to Assess Pelvic Floor Muscle Function in Urological Chronic Pelvic Pain Syndrome in Men. *The Journal of Sexual Medicine*. 2011;8(11):3173-80.

#### Disclosures

**Funding:** Agency for Innovation by Science and Technology (Applied Biomedical Research): governmental grant **Clinical Trial:** No **Subjects:** HUMAN **Ethics Committee:** Commission Medical Ethics of the University Hospitals Leuven **Helsinki:** Yes **Informed Consent:** Yes