

Introduction

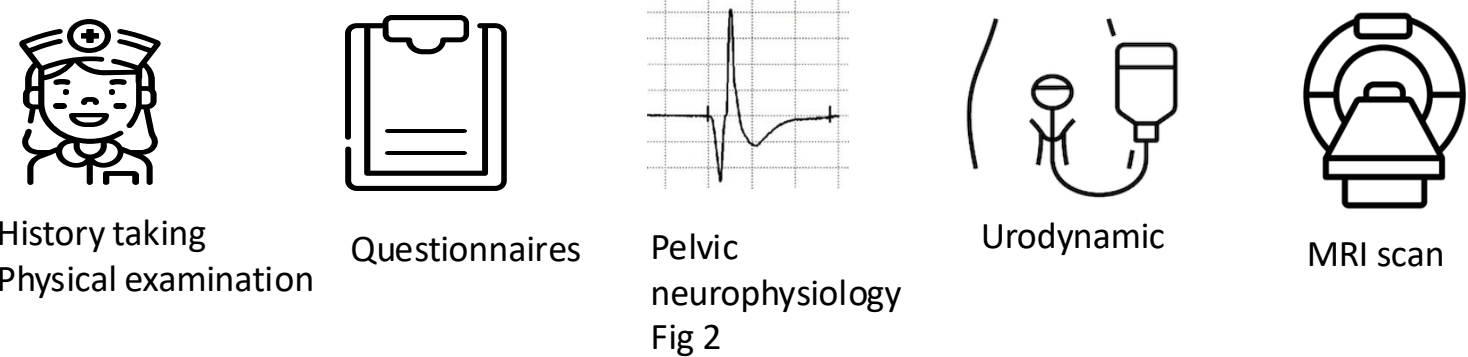
- **Midline sacral meningeal cysts (MSMC)** → diverticula deriving from the dural lining of the sacral thecal sac (Fig 1)^{1,2}
 - Communication with the subarachnoid space of the lumbar cistern = ostium
 - Filled with cerebrospinal fluid
- Frequent confusion with perineurial cysts (Tarlov cysts)
- Rare <1%
- Widely considered to be benign lesions without clinical significance
- Symptomatic MSMC described, related to the **sacral nerve root compression** → radicular pain and genito-urinary symptoms
- Previous description of nerve injury in Tarlov cysts³

Aims

- Describe the **clinical presentation** of patients with presumed symptomatic MSMC
- Assess the impact of the cyst on **nerve root function**
- Compare the **rate of nerve injury between MSMC and Tarlov cysts**

Methods and Materials

- Inclusion of all consecutive patients with symptomatic MSMC (i.e. with at least one pelvic symptom) referred for a uro-neurology assessment between January 2017 and July 2021



- Comparison with previous published cohort of patients with Tarlov cysts who undergone a similar assessment³

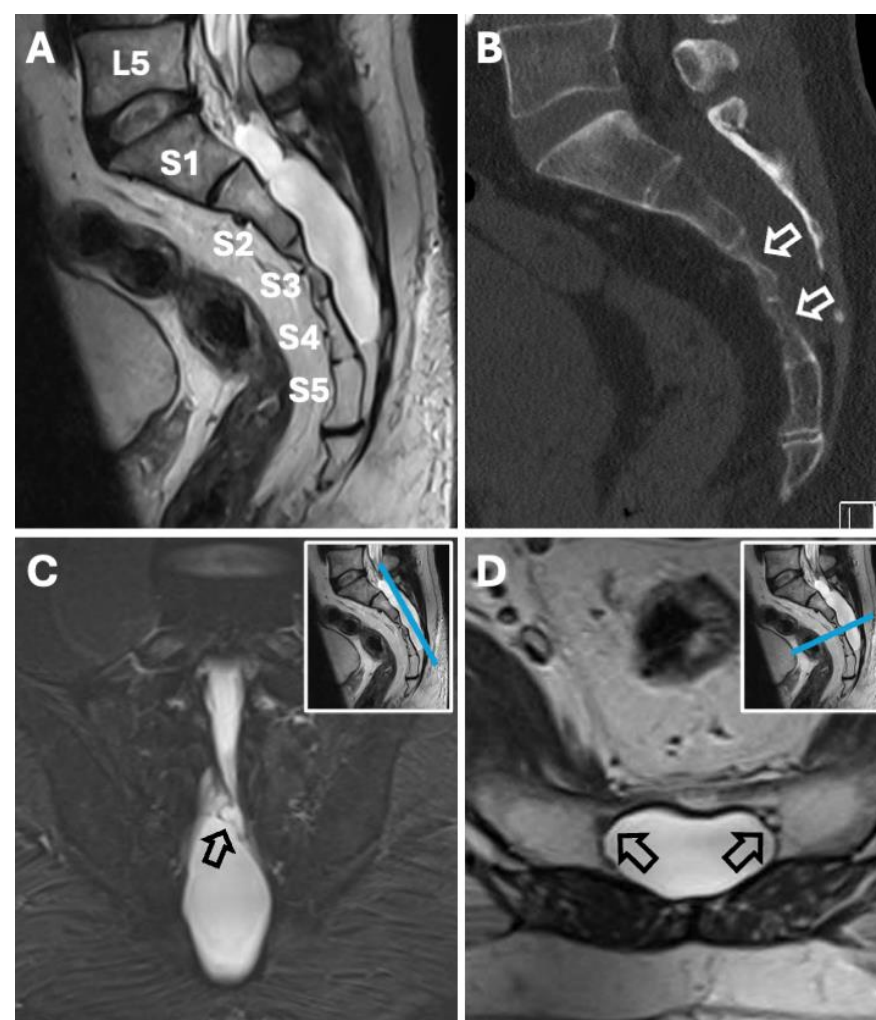
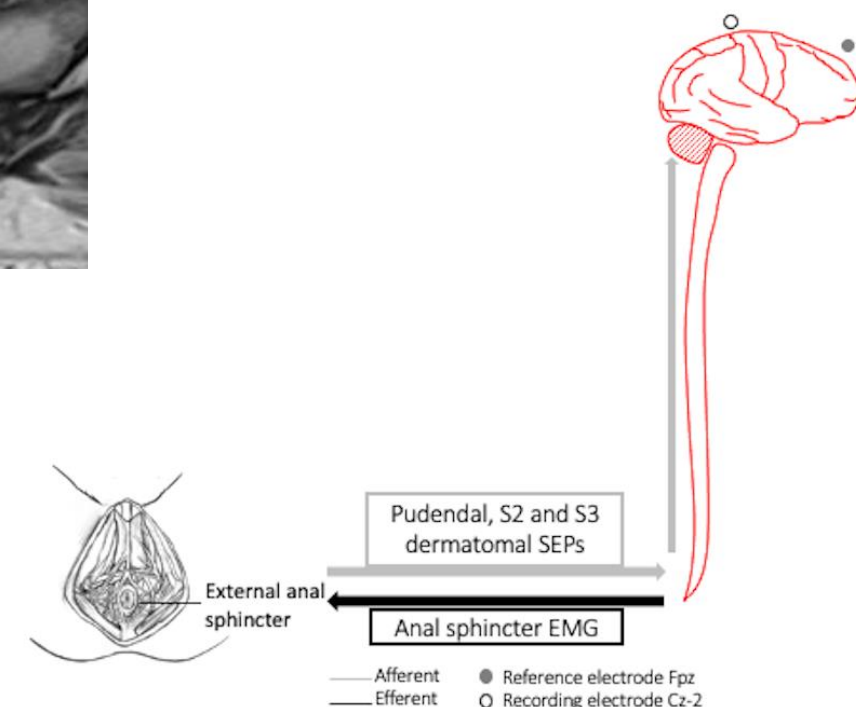


Fig 1. Imaging features of MSMC. (A) Sagittal T2-weighted lumbosacral MRI slice showing an MSMC from lower S1 to the S4/S5 junction. (B) Sagittal lumbosacral CT slice (bone window) demonstrating MSMC-induced sacral scalloping (white arrows). (C) Oblique coronal T2-weighted sacral MRI slice running through the MSMC's ostium (black arrow), seen to present with complex septations. The inset in the right upper corner indicates the level of the MRI slice. (D) Axial T2-weighted sacral MRI slice through lower S3 level. The black arrows indicate the S4 nerve roots pushed ventrally by the dorsally growing cyst.

Fig 2. Schematic diagram depicting the pelvic neurophysiology studies performed



Results

- **11 patients; 42.2±12.5 years**
- Median compression of 6 nerve roots
- **9 patients with abnormal neurophysiology findings** (Table 1)
- No link between abnormal neurophysiology and the size of the cyst
- Comparison with Tarlov cysts
 - Abnormal neurophysiology tests not significantly different between TC and MSMC (57% versus 82%, respectively, p=0.19)
 - The number of abnormal tests was greater in MSMC (p=0.046)
 - Proportion of patients with at least two abnormal tests higher in patients with MSMC (55% versus 18%, p=0.018)

Patient	Age	Symptoms						Neurophysiology findings			MR Imaging findings		Uroflowmetry	
		Pain	Numbness	LUTS Storage	LUTS Voiding	Bowel symptoms	Sexual dysfunction	EAS EMG	Dermatomal SEPs (n)	Pudendal SEPs	Extension of the cyst	Size of the cyst	Curve	PVR
1	54	Back Legs	Legs Perineum	Yes	No	No	NA	Normal	Abnormal (3)	Abnormal (bilateral)	S1 to S5	96x47x25	Normal	Normal
2	49	Back Legs	-	Yes	No	Yes	Yes	Normal	Abnormal (1)	Abnormal (unilateral)	S1 to S3	40x35x24	Normal	Normal
3	59	Legs Pelvis	-	Yes	Yes	No	Yes	Normal	Normal	Abnormal (unilateral)	S1 to S4	80x39x22	Abnormal	High
4*	25	Back Legs Pelvis	-	No	Yes	NA	No	Normal	Normal	Normal	S2 to S4	60x43x20	NA	Normal
5	58	Back Legs Pelvis	-	Yes	Yes	No	Yes	Not done	Abnormal (1)	Normal	S2	14x12x20	Abnormal	Normal
6	35	Back Legs	-	Yes	No	No	NA	Normal	Abnormal (3)	Abnormal (unilateral)	S2	19x11x19	Abnormal	High
7*	34	Back Legs	-	Yes	Yes	Yes	NA	Normal	Normal	Abnormal (unilateral)	S2 to S4	57x30x13	Normal	Normal
8	47	Back Pelvis	Leg	Yes	Yes	No	No	Abnormal	Abnormal (1)	Normal	S1 to S3	51x28x14	Normal	Normal
9	43	Back Legs	Leg	Yes	Yes	Yes	Yes	Normal	Abnormal (1)	Abnormal (unilateral)	S1 to S4	83x51x36	Normal	High
10	39	Back Legs Pelvis	-	Yes	Yes	Yes	Yes	Not done	Normal	Normal	S2 to S4	57x39x21	Normal	Normal
11	22	Back Legs	Buttock	Yes	Yes	Yes	Yes	Normal	Abnormal (1)	Abnormal (unilateral)	S1 to S2	28x20x14	Abnormal	Normal

Table 1: Clinical presentation and neurophysiology, MR imaging and uroflowmetry findings in 11 patients with midline sacral meningeal cysts

EAS: external anal sphincter; EMG: Electromyography; LUTS: Lower Urinary Tract Symptoms PVR: Post Void Residual; SEPs: Sensory Evoked Potentials

* Other urological syndrome associated (Fowler's syndrome)

Normal findings
1 abnormal test
2 abnormal tests

Discussion

- Nerve injury: sensory > motor pathways → related to the fiber size?
- Five patients with abnormal uroflowmetry: impact of nerve injury on bladder contraction? Medication (opiates)?
- Overactive bladder: probably not related to the cyst
- No obvious link between the size of the cyst and nerve injury → Role of intracystic pressure in creating nerve injury?

Conclusions

- First study to report an objective neurological impairment of sacral nerve root function in patients with symptomatic MSMC
- Increased prevalence and severity of nerve injury in MSMC than in Tarlov cysts → related to their expansiveness and involvement of multiple sacral roots
- Role of pelvic neurophysiology in selecting patients for surgery?

Contact

Claire Hentzen
Neuro-urology department
Tenon Hospital, Paris, France
Email: claire.hentzen@aphp.fr

References

1. Tarlov IM. Spinal perineurial and meningeal cysts. *J Neurol Neurosurg Psychiatry*. Dec 1970;33(6):833-43.
2. Cabrilo I, Zaidman N, Casey AT. Midline sacral meningeal cyst decompression and repair. *Acta Neurochir (Wien)*. Oct 2021;163(10):2777-2781.
3. Hentzen C, Cabrilo I, Malladi P, et al. Sacral Tarlov cysts: Neurophysiology abnormalities and correlation with pelvic sensory and visceral symptoms. *Eur J Neurol*. Sep 2023;30(9):2838-2848.