

## VAGINAL COLLAGEN REMODELLING AFTER FRACTIONAL CARBON DIOXIDE LASER SURGERY

### Hypothesis / aims of study

The process of becoming older is genetically determined and environmentally modulated. The process of vaginal ageing itself can contribute to the loss of vaginal trophism, tone, support and function with a consequent increased risk of lower urinary tract symptoms and pelvic floor dysfunction. Connective tissues and collagen constituents and architecture play an important role in this ageing process. With age, in fact, collagen fibrils loose their reticular spatial disposition and, the Type I/III ratio is altered compared to premenopausal state.

The aim of this study is to assess if CO<sub>2</sub> laser at the level of vaginal mucosa can determine new collagen formation or modification as shown in the skin[1].

### Study design, materials and methods

A pilot study was designed as a prospective cohort trial. Consecutive women addressed to POP reconstructive procedure were enrolled. After fascial plications the redundant vaginal edges were irradiated with a CO<sub>2</sub> laser (SmartXide DOT, DEKA Laser, Florence, Italy) through a vaginal probe for internal dot resurfacing. Each target area was firstly irradiated with a different machine set-up (in terms of power output, exposure time, distance and sequence of delivery points) and subsequently trimmed and stored in a properly buffered solution. Each sample received histological, examination in particular for the evaluation of the radiation-induced modifications. Microscopic and ultrastructural aspects of the collagenic and elastic components of the matrix were studied, and a specific image analysis with computerized morphometry was performed in order to demonstrate the specific action of the treatment and possibly to correlate the modifications of the ultrastructural pattern to specific molecular modifications. We also considered the fine cytological aspects of the connective tissue proper cells, particularly stem cells and fibroblasts, related to the conditions of the specific laser stimulation. The evaluation of specific morphologic features as mirrors of functional reparative or regenerative activities was also made.

### Results

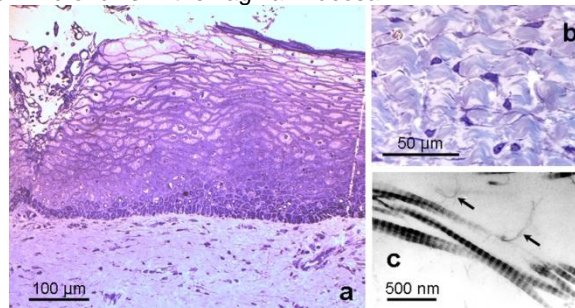
During the study period 4 women were enrolled and 8 vaginal specimens were finally retrieved. Both microscopic and ultrastructural aspects of the collagenic and elastic components of the matrix showed new collagen formation easily distinguishable from the surrounding amorphous matrix at the toluidine blue staining. The electron microscopy evaluation at high magnification showed collagen microfibrils with an initial trabecular disposition (Figure 1). All the procedures were uneventful for patients.

### Interpretation of results

This pilot study showed how CO<sub>2</sub> dot laser can produce a remodeling of the vaginal connective tissue without causing damage to the surrounding tissue. Other tests, including experiments on animal models, are needed to establish the long-term outcome before starting any other experience on humans. In agreement with the ACOG recommendations[2] this step will be absolutely mandatory to prevent that the use of CO<sub>2</sub> laser in cosmetic vaginal procedures could turn into real disasters. We feel that this study may actually represent a first step in an almost unexplored field.

### Concluding message

CO<sub>2</sub> dot laser produces new collagen microfibrils in the vaginal mucosa.



**Figure 1:** a) Vaginal epithelium and the most superficial layer of the connective tissue is represented in a semi-thin section at the light microscope; b) compact single bundles of collagen fibres are well distinguishable from the amorphous matrix (toluidine blue staining). c) TEM high magnification of collagen microfibrils with some filaments in close relationship with their surface (arrows).

### References

1. AL Berlin, M Hussain, R Phelps, and DJ Goldberg. A prospective study of fractional scanned non sequential Carbon Dioxide laser resurfacing: a clinical and histopathologic evaluation. *Dermatologic Surgery*, 32, 2: Feb 2009
2. ACOG Committed Opinion Number 378; September 2007. Vaginal "rejuvenation" and cosmetic vaginal procedures.

<i>Specify source of funding or grant</i>	Deka gave us the CO2 laser equipment and gave us a grant
<i>Is this a clinical trial?</i>	No
<i>What were the subjects in the study?</i>	HUMAN
<i>Was this study approved by an ethics committee?</i>	Yes
<i>Specify Name of Ethics Committee</i>	Institutional Review Board, Insubria Univesity, Varese, Italy
<i>Was the Declaration of Helsinki followed?</i>	Yes
<i>Was informed consent obtained from the patients?</i>	Yes