

INTERRATER RELIABILITY OF ASSESSING AGE-RELATED CHANGES TO THE LEVATOR ANI OF NULLIPAROUS WOMEN ON 3-D ENDOVAGINAL ULTRASOUND

Hypothesis / aims of study

The objective of this study is to assess the interrater reliability of assessing age-related changes in levator ani subdivisions using 3-D endovaginal ultrasound (3-D EVUS).

Study design, materials and methods

80 nulliparous women ages 21-70 were recruited for this IRB approved study through campus and community advertising. Participants underwent a standard examination and a 3-D EVUS (BK Medical Peabody, MA). Levator ani subdivisions were identified by a classification based on attachment points. Subdivisions of interest included the puboperinealis, puboanalis, pubococcygeous, puborectalis and ileococcygeous muscles. Levator ani muscle defects were graded as: no muscle damage (0), mild abnormality (1), moderate abnormality (2), and complete muscle loss (3). An exemplary scan of a 25 yo nulliparous woman was selected for image clarity. According to the scoring system, a score of 0 given to each muscle pair corresponds to "no muscle damage" and a score of 30 corresponds to "complete muscle loss" of all subdivisions. A length of six cm of the vagina was scanned in 60 seconds at scans every 0.25 mm with a cumulative 240 scans from which a 3-D rendered cube was calculated. The ultrasound cubes were then be reviewed by two reviewers (LHQ and SAS), blinded to participant data or the scores of the other reviewer. Exact examiner agreement was calculated by percent agreement between muscle pairs, and weighted kappa values for each muscle subdivision (ordinal scores). Bias was examined with a Bland-Altman plot. Interclass coefficient was calculated to report agreement of total scores.

Results

There were 160 scans available for this study (2 scans per subject). Median age was 47 years (range 22-70). Exact agreement for unilateral scoring was 83% and differences of within one point agreement were found in 11.7%. Readings for pubococcygeous were not analyzed because this muscle was only visualized in 20% of cases. Exact agreement or a one point difference was reached in 95% of cases. The kappa coefficients were as follows: puboperinealis (kappa 0.813, 95% CI 0.686, 0.94), puboanalis (kappa 0.2, 95% CI -0.0171-0.362), puborectalis (kappa 0.6, 95% CI 0.4-0.843), and ileococcygeous (kappa 0.7, 95% CI 0.5-0.885). The intraclass correlation for comparison of total scores was 0.82 (95% CI 0.72-0.89). The Bland-Altman plot showed slight overestimation by reader 1 (mean bias 0.4 ± 0.45) Figure 1. Although the kappa statistic was lowest for puboperinealis measurements, overall exact reader agreement was 84% for this muscle group.

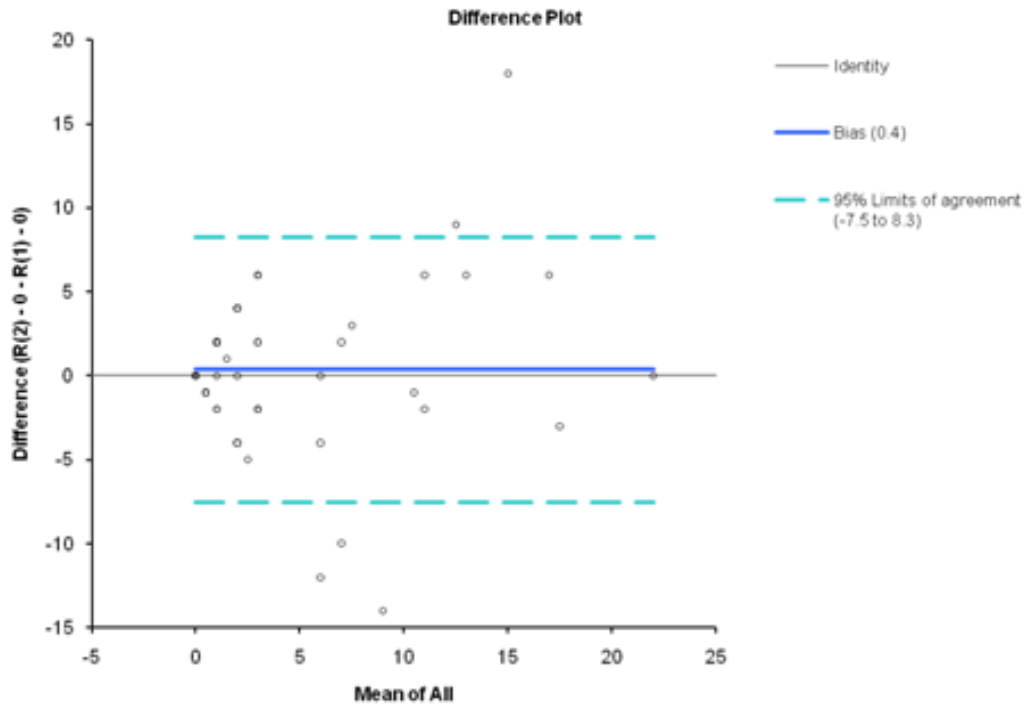
Interpretation of results

Interrater reliability for age-related changes of levator ani subdivisions on 3-D EVUS in nulliparous participants of different ages was overall good to excellent. There was agreement of abnormalities within one point difference in 95% of cases.

Concluding message

Interrater reliability for age-related changes of levator ani subdivisions on 3-D EVUS in nulliparous participants of different ages was overall good to excellent. There was agreement of abnormalities within one point difference in 95% of cases.

Figure 1. Bland Altman Plot showing mean difference of measurements between readers



<i>Specify source of funding or grant</i>	OU College of Medicine Alumni Association Research Scholar Grant
<i>Is this a clinical trial?</i>	Yes
<i>Is this study registered in a public clinical trials registry?</i>	No
<i>Is this a Randomised Controlled Trial (RCT)?</i>	No
<i>What were the subjects in the study?</i>	HUMAN
<i>Was this study approved by an ethics committee?</i>	Yes
<i>Specify Name of Ethics Committee</i>	OUHSC Institutional Review Board
<i>Was the Declaration of Helsinki followed?</i>	Yes
<i>Was informed consent obtained from the patients?</i>	Yes