

Sakakibara R<sup>1</sup>, Uchida Y<sup>2</sup>, Uchiyama T<sup>3</sup>, Yamamoto T<sup>3</sup>, Yamanishi T<sup>4</sup>, Yamaguchi C<sup>5</sup>, Kishi M<sup>1</sup>, Ogawa E<sup>1</sup>, Takahashi O<sup>6</sup>, Sugiyama M<sup>6</sup>

*1. Neurology, Internal Medicine, Sakura Medical Center, Toho University, 2. Radiology, Chiba University, 3. Neurology, Chiba University, 4. Urology, Dokkyo Medical College, 5. Central Laboratory Unit, Chiba University Hospital, 6. Clinical Physiology Unit, Sakura Medical Center, Toho University*

## **INCREASE IN BILATERAL MID-CINGULATE BLOOD FLOW RELATED TO BLADDER RECOVERY IN IDIOPATHIC NORMAL PRESSURE HYDROCEPHALUS AFTER SHUNT SURGERY**

### Hypothesis / aims of study

It is reported that bladder dysfunction in idiopathic normal pressure hydrocephalus (iNPH) relates closely to right frontal hypoperfusion using <sup>123</sup>I- N-isopropyl-p-iodoamphetamine (IMP) single-photon emission computed tomography (SPECT) [1]. We here analysed which brain area is related with recovery of bladder dysfunction in iNPH after shunt surgery.

### Study design, materials and methods

Seventy-five patients with iNPH who underwent shunt surgery were enrolled in the study. Before and 12 months after shunt surgery, we analysed brain IMP-SPECT imaging using NEUROSTAT (3D-SSP) software [2], bladder dysfunction by a Japanese NPH grading scale-revised (JNPHGS-R) bladder subscale. JNPHGS-R bladder subscale consisted of grade 0, none, grade 1, urinary urgency and frequency, grade 2, urinary incontinence 1-3 times a week, grade 3, urinary incontinence more than daily, and grade 4, loss of bladder control. More than one grade improvement is defined as improvement; more than one grade decrement is defined as worsening; otherwise no changes.

### Results

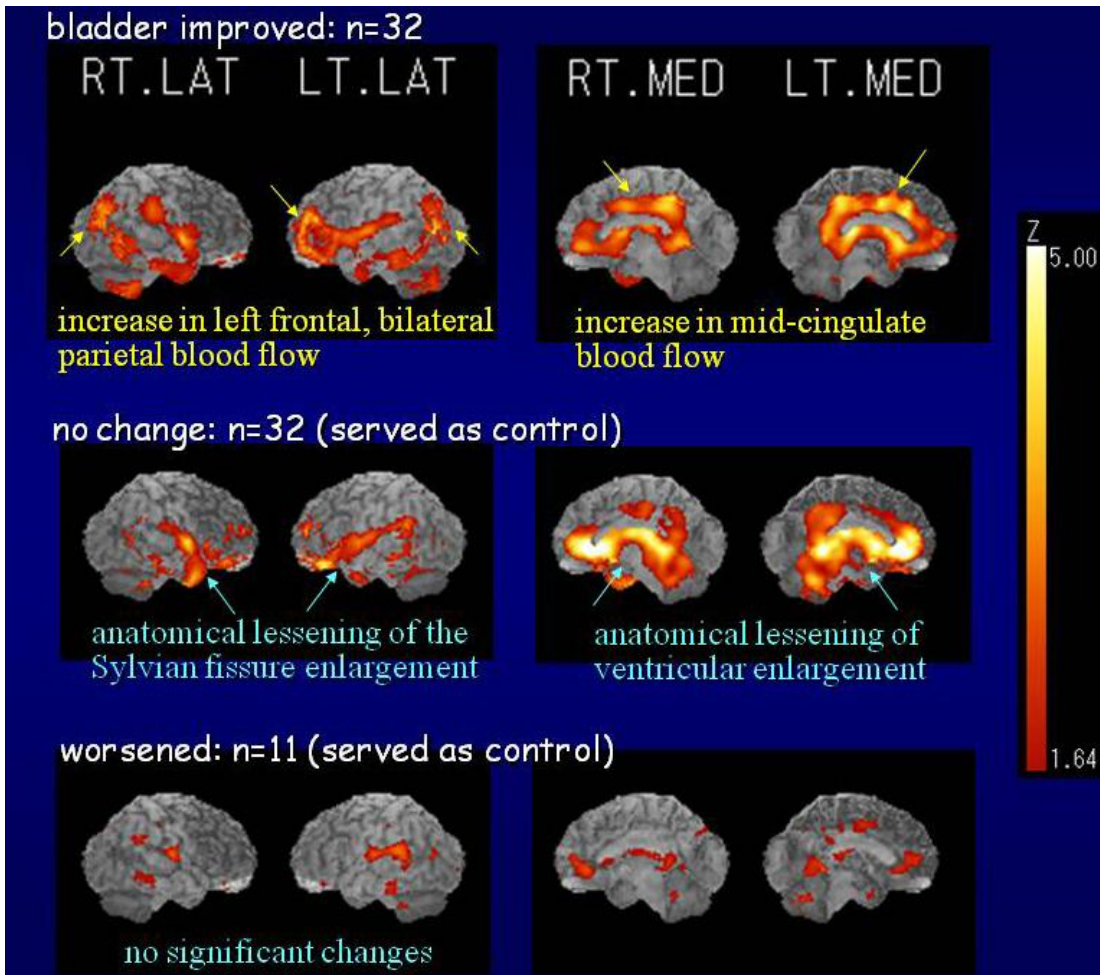
Comparing pre and post surgery, in the bladder improvement group (32 cases) there was an increase in left frontal, bilateral parietal and mid-cingulate blood flow ( $p < 0.05$ ) (**Figure 1**). In the no change group (32 cases) there was an increase in blood flow which is regarded as reversed enlargement in the Sylvian fissure and lateral ventricles. In the worsening group no significant blood flow change was observed.

### Interpretation of results

Urinary incontinence is one of the triads to clinically diagnose iNPH, which potentially can be reversed by shunt surgery. Since iNPH is a diffuse brain disease with dilated ventricles, the site of lesions accounting for bladder dysfunction has remained unclear in this disorder. In our previous study, we have reported that bladder dysfunction in iNPH is closely related with right frontal hypoperfusion. To the best of our knowledge, this is the first report to show that after the shunt surgery, bladder improvement is closely related with an increase in left frontal, bilateral parietal and mid-cingulate blood flow. Previous studies have suggested that the frontal cortex is critical in supra-pontine regulation of micturition reflex. The net effect of the frontal cortex on micturition is thought to be inhibitory, since lesion in this area has led to urinary incontinence in experimental animals and humans [3]. Functional imaging studies in normal volunteers have shown that the lateral and medial frontal cortex are activated during bladder filling and micturition [3]. Therefore, blood flow increase in the mid-cingulate gyrus etc. in the present study most probably indicates functional restoration of the brain's inhibition on the micturition reflex in this disorder.

### Concluding message

The present study showed for the first time that comparing pre and post surgery, bladder recovery in iNPH patients related closely to an increase in left frontal, bilateral parietal and mid-cingulate blood flow using <sup>123</sup>I-IMP SPECT. Blood flow increase in the mid-cingulate gyrus etc. in the present study most probably indicates functional restoration of the brain's inhibition on the micturition reflex in this disorder.



**Figure 1** 3D- SSP maps of differences of cerebral blood flow before and 12 months after shunt surgery in iNPH patients as measured by  $^{123}\text{I}$ -labelled IMP SPECT.

Comparing pre and post surgery, in the bladder improvement group (32 cases) there was an increase in left frontal, bilateral parietal and mid-cingulate blood flow ( $p < 0.05$ , shown in Z-score). In the no change group (32 cases) there was an increase in blood flow which is regarded as reversed enlargement in the Sylvian fissure and lateral ventricles. In the worsening group no significant blood flow change was observed.

#### References

1. ICS general meeting (2007) abstract 8.
2. J Nucl Med (1994) 35: 1528-1537.
3. Nat Rev Neurosci. (2008) 9: 453-466.

<i>Specify source of funding or grant</i>	No funding or grant
<i>Is this a clinical trial?</i>	No
<i>What were the subjects in the study?</i>	HUMAN
<i>Was this study approved by an ethics committee?</i>	Yes
<i>Specify Name of Ethics Committee</i>	Ethics Committee in Sakura Medical Center, Toho University
<i>Was the Declaration of Helsinki followed?</i>	Yes
<i>Was informed consent obtained from the patients?</i>	Yes